



# Third Week of Development

Dr. Heba Kalbouneh  
DDS, MSc, DMD/PhD  
Professor of Anatomy, Histology and Embryology

*Prepared and adapted for teaching by Prof. Dr. Heba Kalbouneh.  
Illustrations adapted from multiple educational resources for educational purposes.  
These slides are intended for students enrolled in this course and should not be  
distributed without permission.*

# Third week of development

*(Days 15–21)*


The third week of development is characterized by:

- ✓ Gastrulation, during which the bilaminar embryonic disc is transformed into a trilaminar disc composed of ectoderm, mesoderm, and endoderm.
- ✓ Formation of primitive streak and primitive node.
- ✓ Formation of notochord.
- ✓ Establishment of the body axes (craniocaudal, dorsoventral and left-right).
- ✓ Differentiation of intraembryonic mesoderm.
- ✓ Initiation of neurulation.
- ✓ The beginning of cardiovascular system (vasculogenesis).
- ✓ The formation of chorionic villi (secondary and tertiary).

**The third week of development involves:**

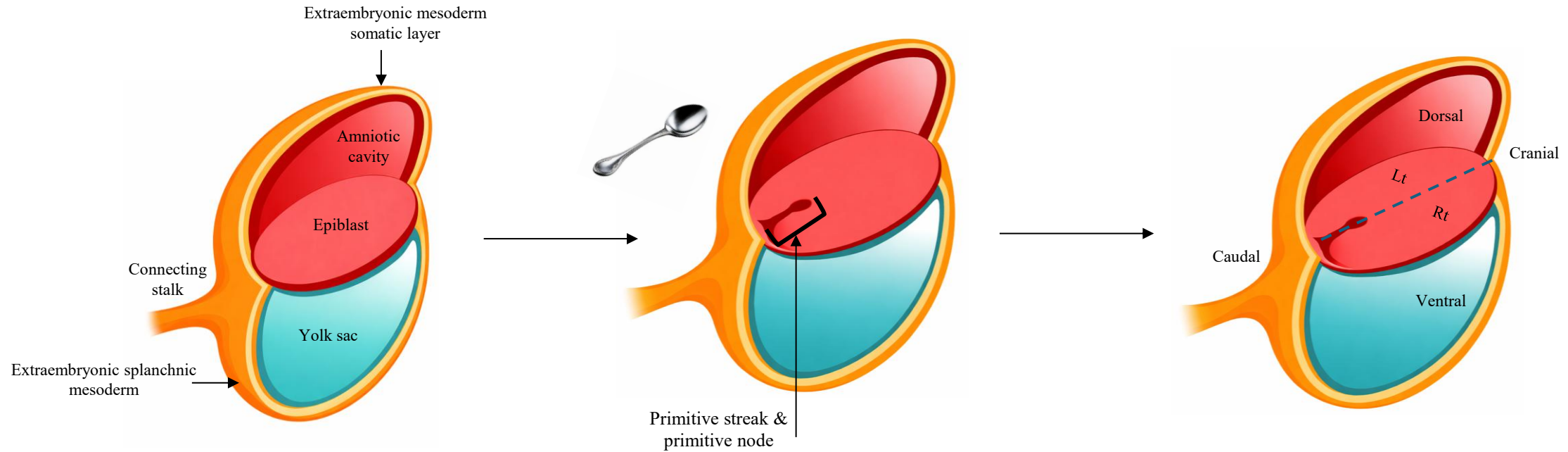
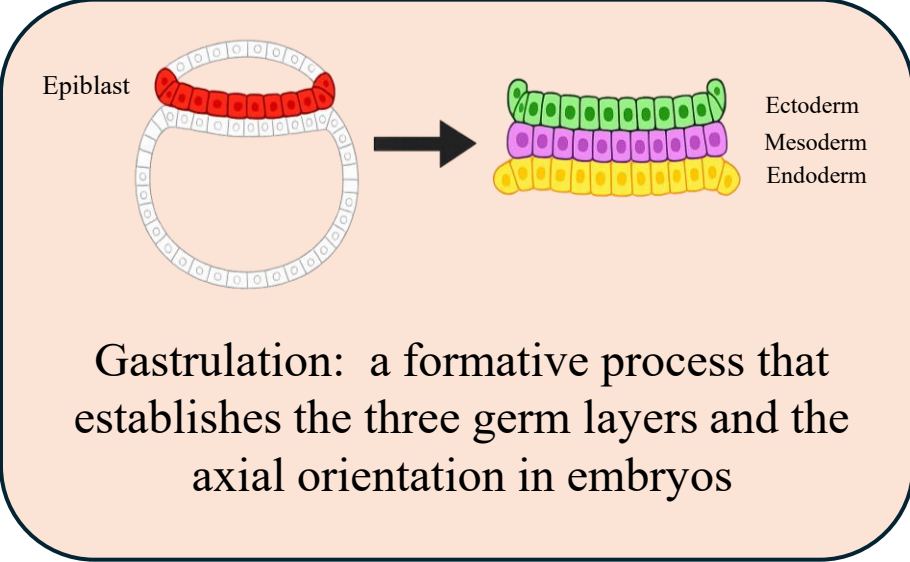
**Changes in the chorion.**

**Changes in the embryonic disc.**



# Gastrulation and Formation of Germ Layers

- ✓ Gastrulation begins with the appearance of the primitive streak on the dorsal surface of the epiblast (caudal end).
- ✓ Epiblast cells migrate inward through the primitive streak and primitive node.
- ✓ These migrating cells differentiate into:
  - ✓ **Endoderm** → replaces hypoblast
  - ✓ **Intraembryonic mesoderm**
  - ✓ **Ectoderm** → remaining epiblast cells
- ✓ This process establishes **cranio-caudal, dorsal-ventral, and left-right axes.**



## Primitive streak

A linear thickening of epiblast cells that appears on the dorsal surface of the embryonic disc at the caudal end during the third week of development. → It marks the site of gastrulation, where epiblast cells migrate inward to form the endoderm and intraembryonic mesoderm, and it establishes the body axes.

## Primitive groove

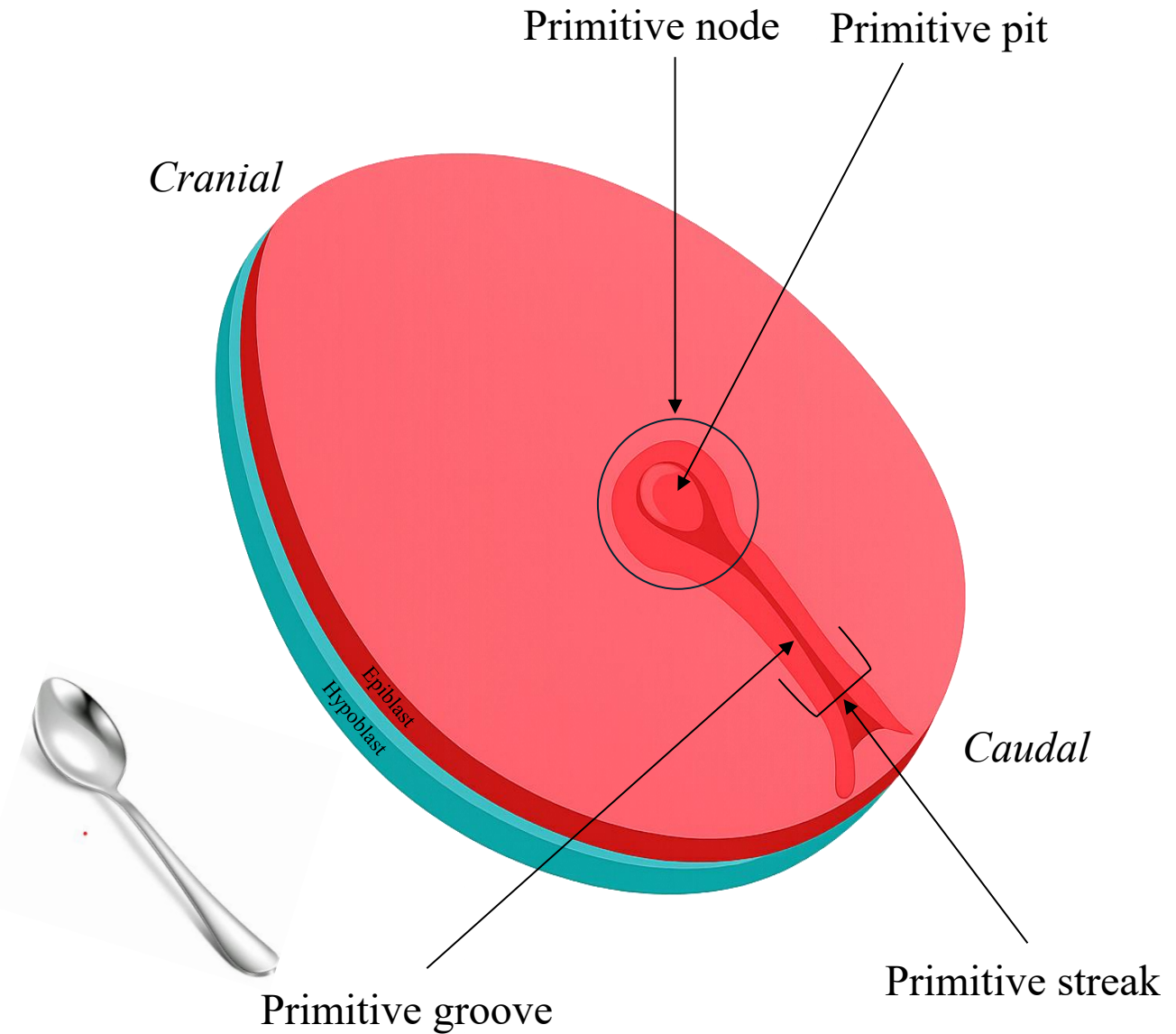
A longitudinal depression that runs along the length of the primitive streak. → It serves as the pathway for migrating epiblast cells during gastrulation.

## Primitive node (Hensen's node)

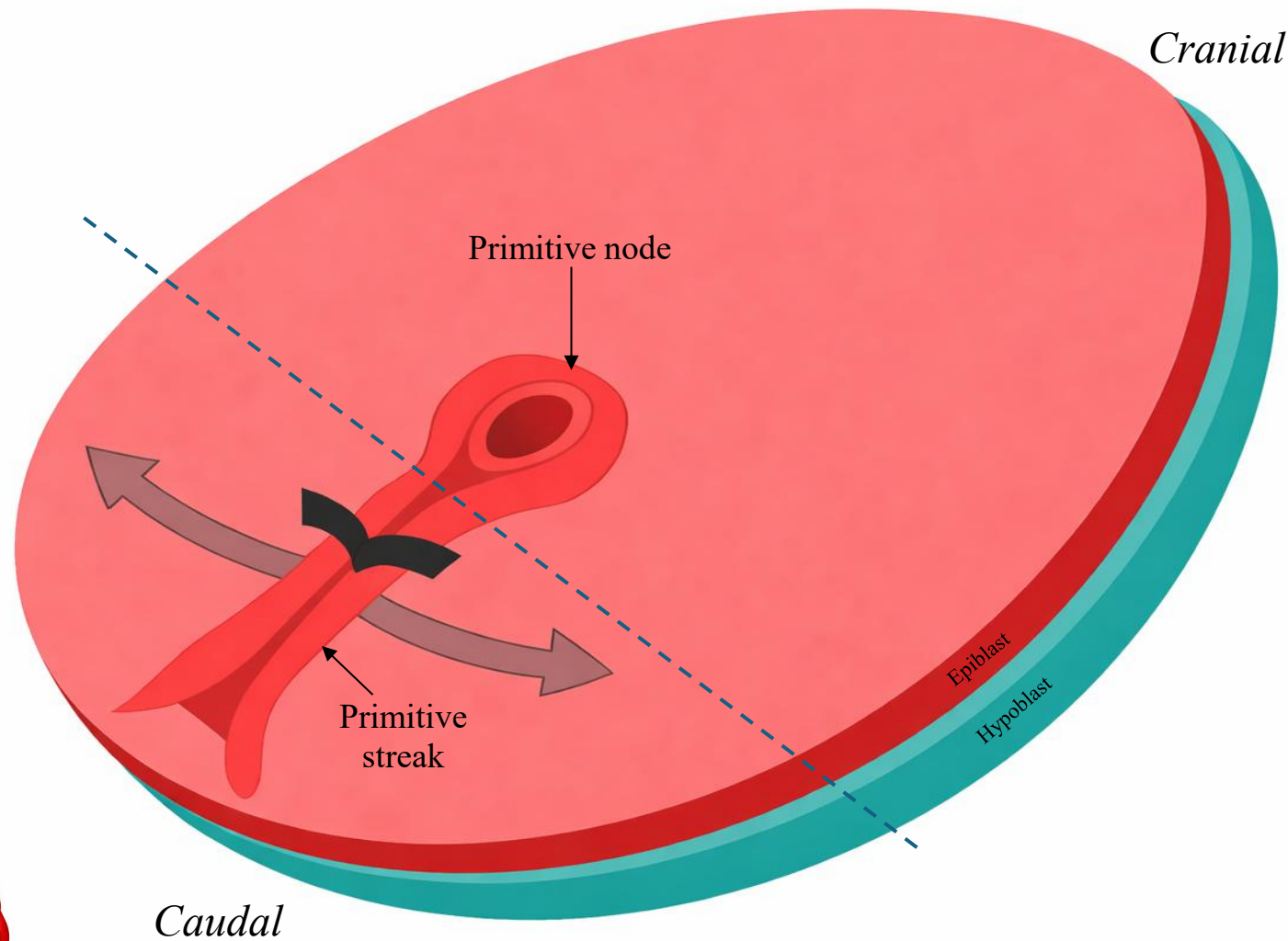
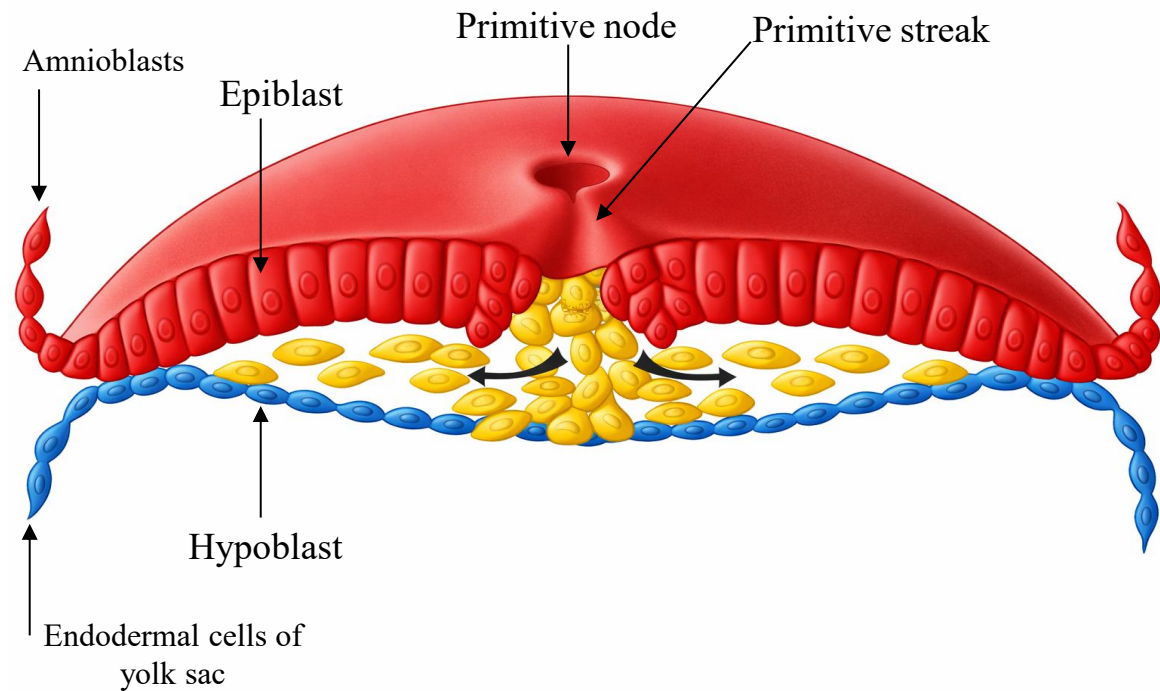
A rounded, elevated region at the cranial end of the primitive streak. → It functions as an organizer, directing cell migration and differentiation, and gives rise to the notochord.

## Primitive pit

A small central depression in the primitive node. → It represents the opening through which epiblast cells invaginate to form the notochord.

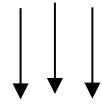


Cells of the epiblast migrate toward the primitive streak. On arrival in the region of the streak they detach from the epiblast, and slip beneath it. This inward movement is known as **invagination**.



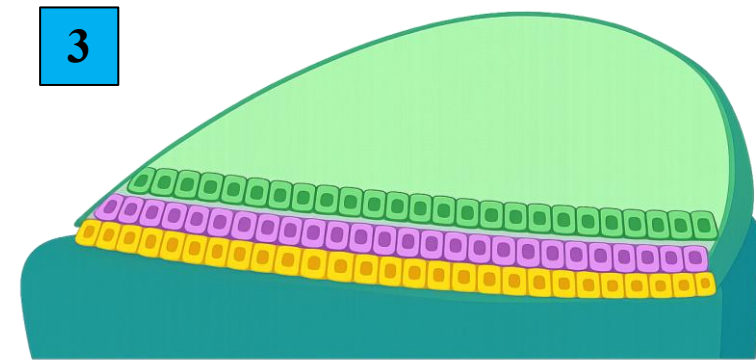


Once the cells of **epiblast** have invaginated, some displace the hypoblast, creating the embryonic **endoderm**, and others come to lie between the epiblast and newly created endoderm to form **mesoderm**. Cells remaining in the epiblast then form **ectoderm**.



*Thus the epiblast, through the process of gastrulation, is the source of all of the germ layers in the embryo.*

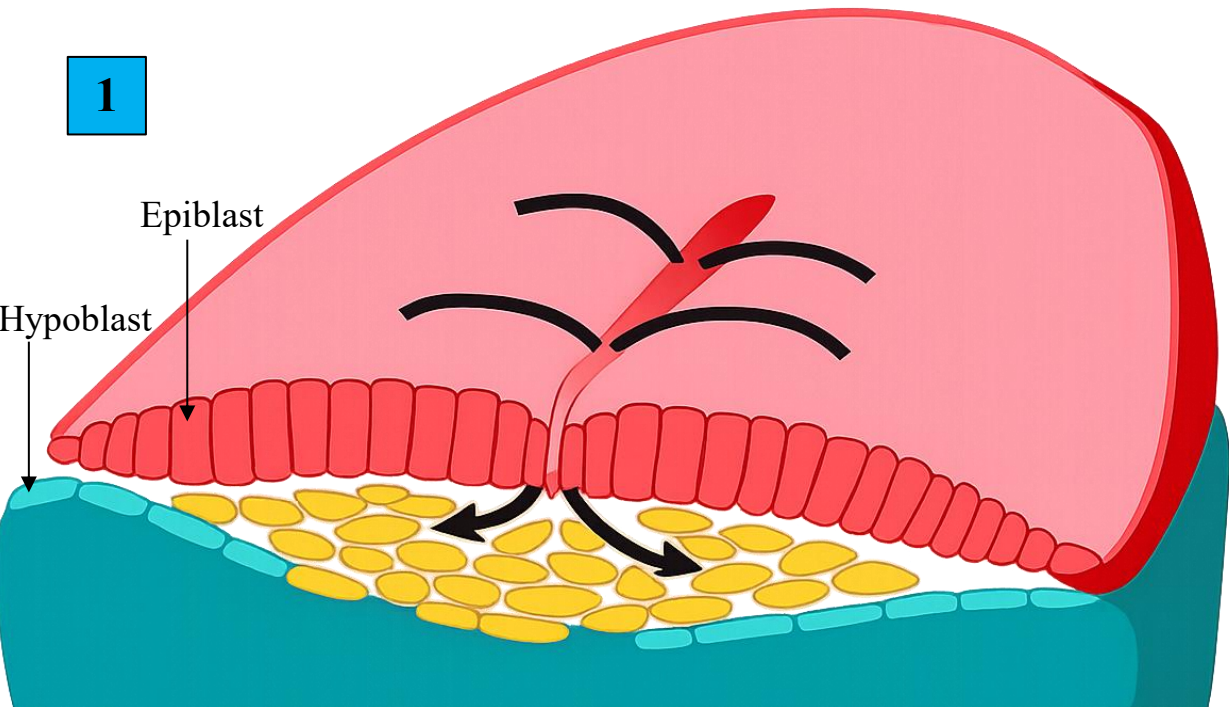
The mesoderm will eventually separate the ectoderm from the endoderm, except at the points where the two layers are fused (i.e. caudally at the cloacal membrane, and cranially at the buccopharyngeal membrane).



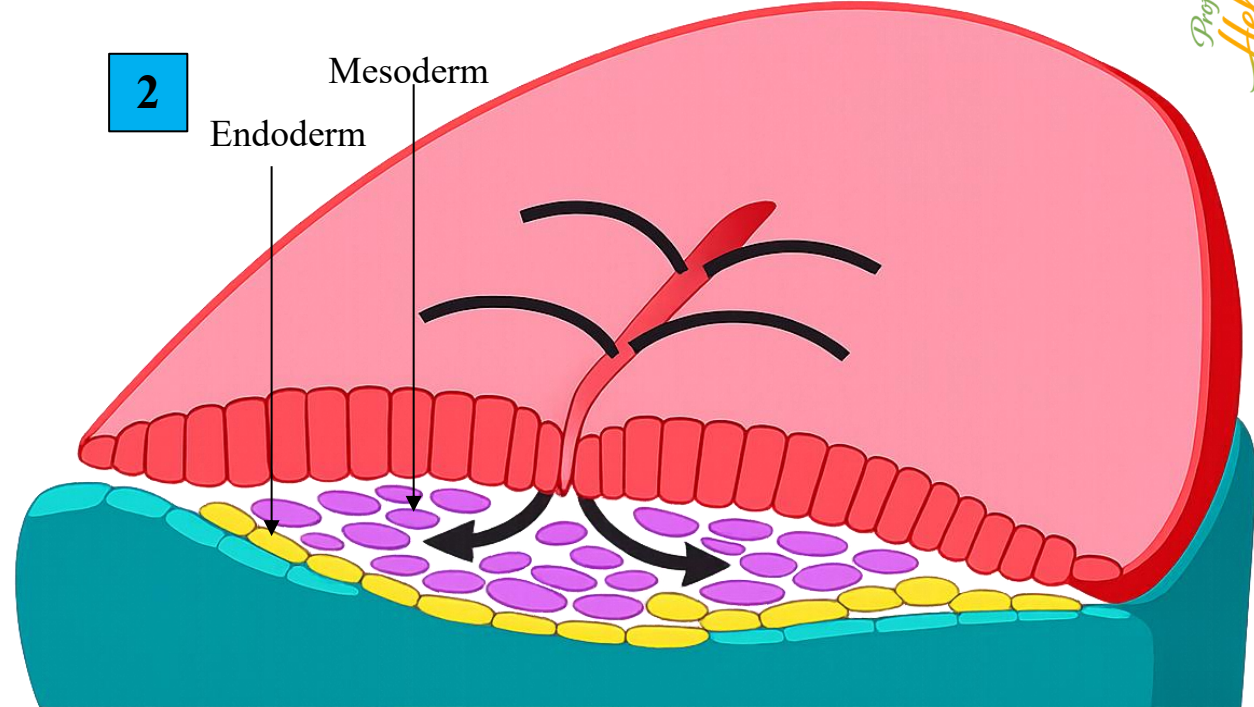
**Ecto-** = outside / outer  
**Meso-** = middle / intermediate  
**Endo-** = inside / inner  
**-derm** = skin / layer

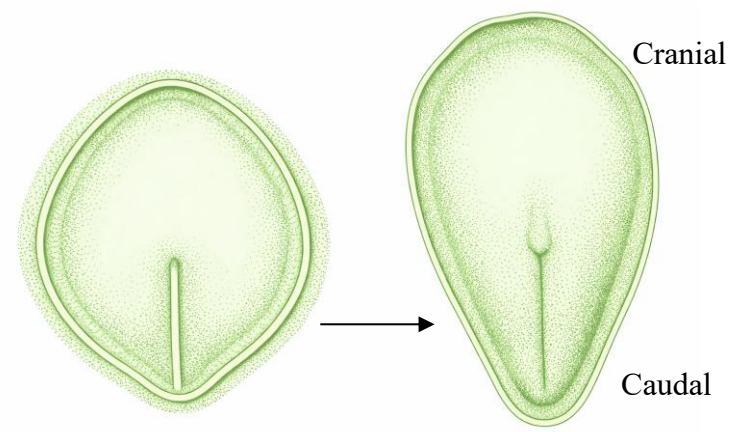

Prof. Dr. Heba Kalbouneh

1



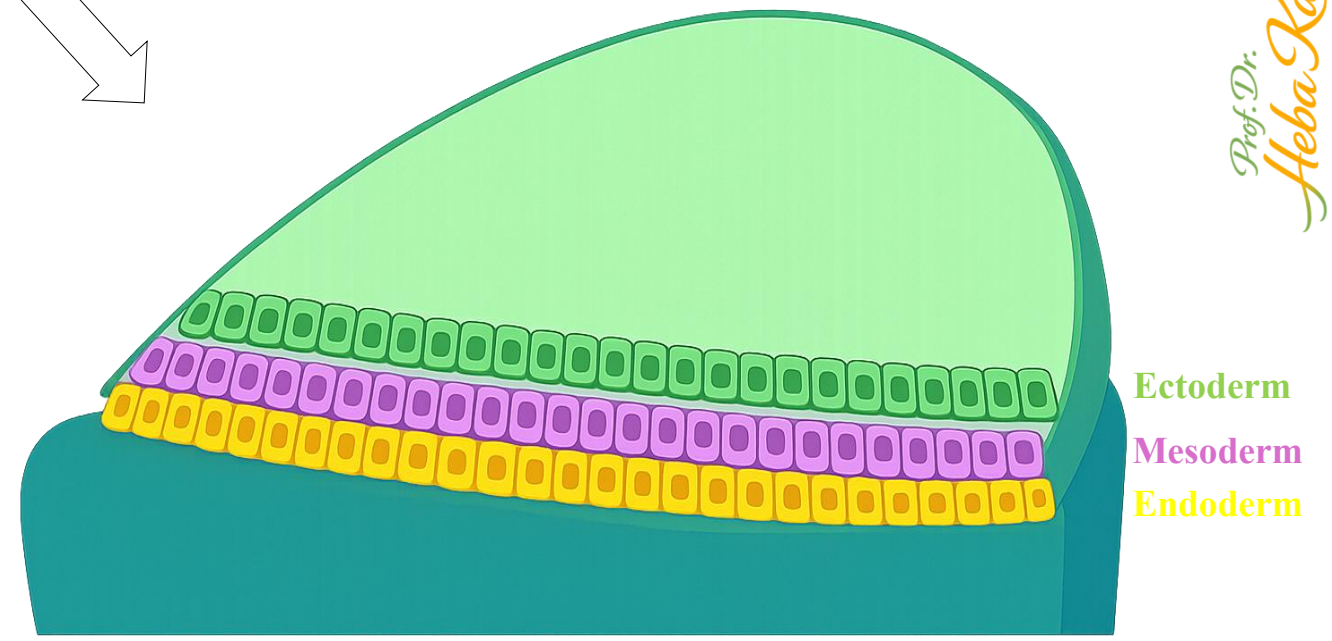
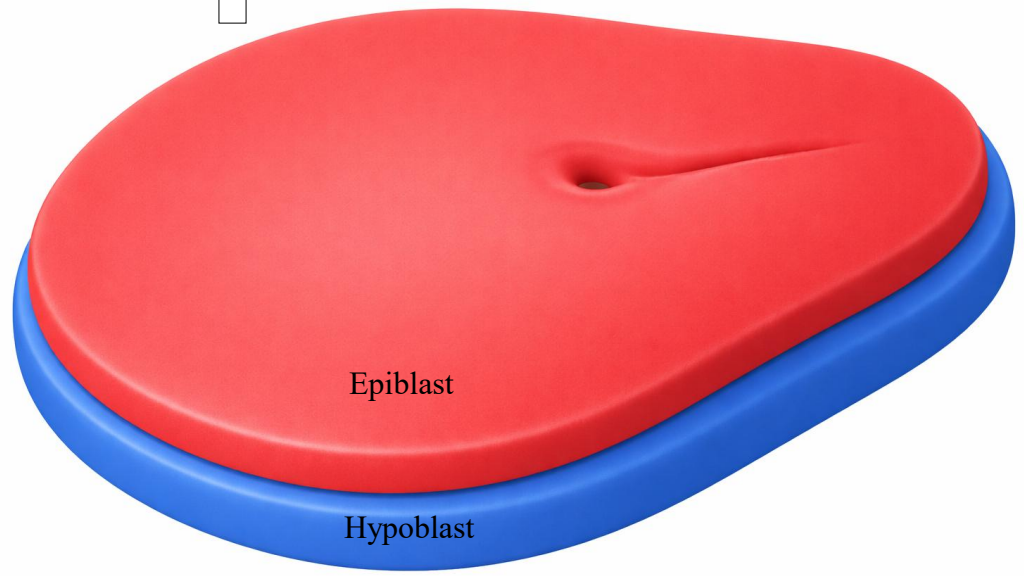
2





Note: The embryonic disc gradually becomes elongated, with a broad cranial and a narrow caudal end.

Gastrulation



Prof. Dr. Heba Kalbouneh

## Derivatives of ectoderm:

Gives rise to structures related to **covering, nervous system, and special senses.**

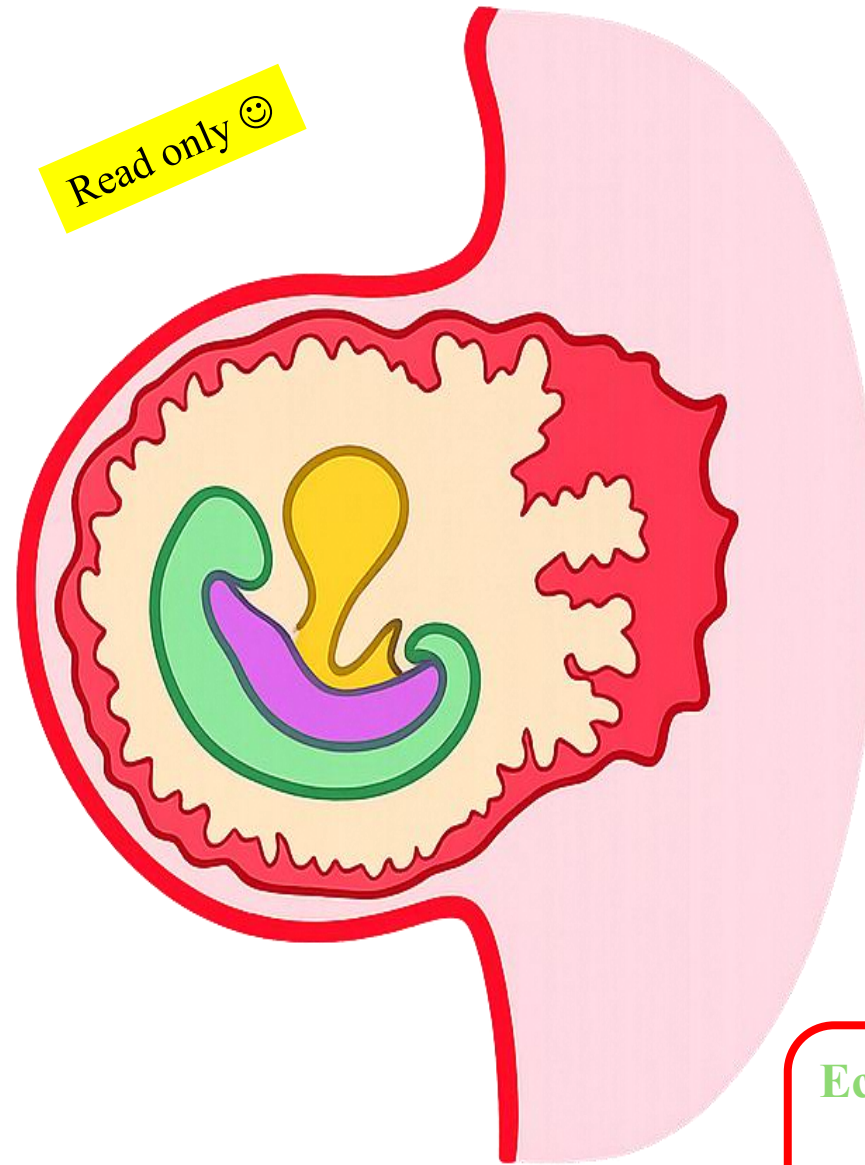
- ✓ Central nervous system: brain, spinal cord
- ✓ Peripheral nervous system
- ✓ Epidermis of skin and its appendages:
  - Hair
  - Nails
  - Sweat, sebaceous, and mammary glands
- ✓ Sensory organs:
  - Lens of eye
  - Retina
  - Inner ear
  - Olfactory epithelium
- ✓ Enamel of teeth
- ✓ Pituitary gland (anterior & posterior parts)

*Derivatives of neural crest cells !!!!*

## Derivatives of Endoderm

Forms **epithelial linings of the gut, respiratory tract, and associated glands.**

- ✓ Epithelial lining of gastrointestinal tract (pharynx → upper anal canal)
- ✓ Epithelial lining of respiratory tract:
  - Larynx
  - Trachea
  - Bronchi
  - Lungs
- ✓ Liver
- ✓ Pancreas
- ✓ Thyroid gland
- ✓ Parathyroid glands
- ✓ Thymus
- ✓ Epithelial lining of:
  - Urinary bladder
  - Urethra



## Derivatives of Mesoderm

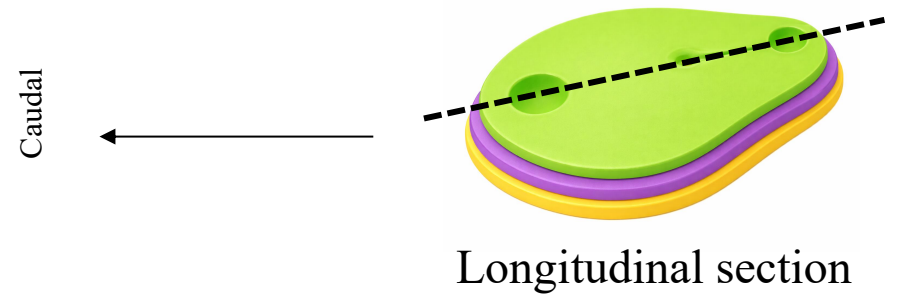
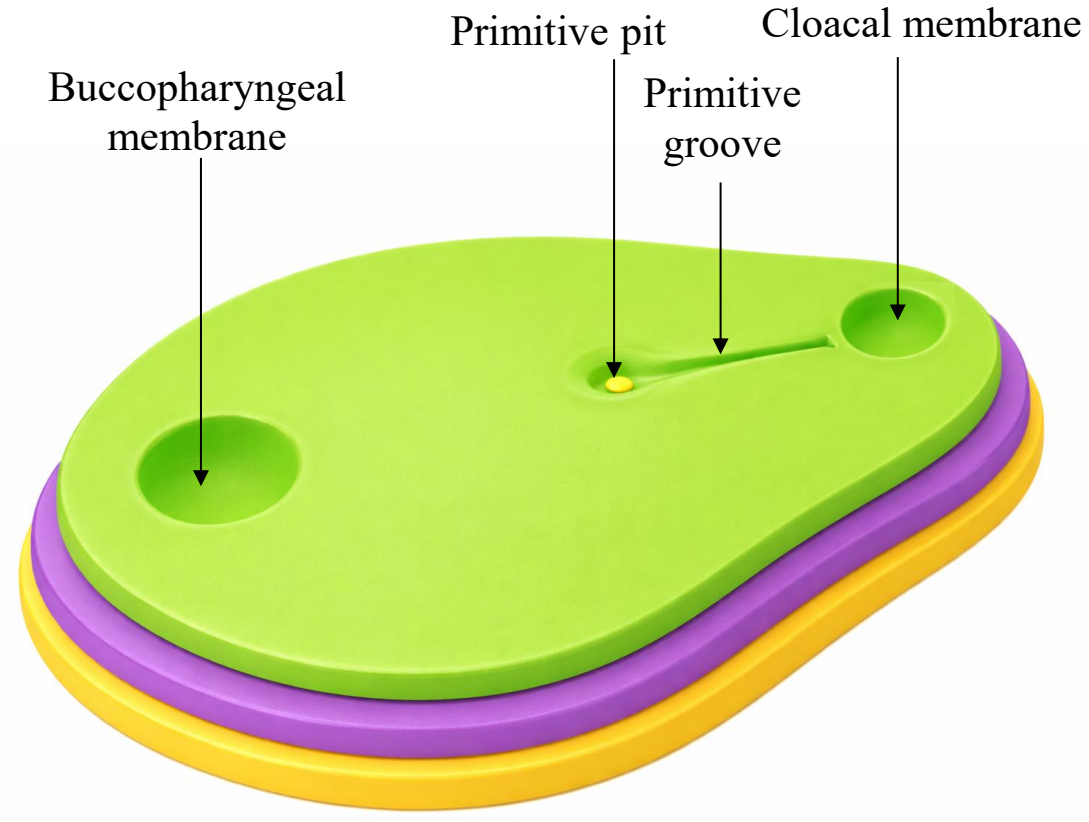
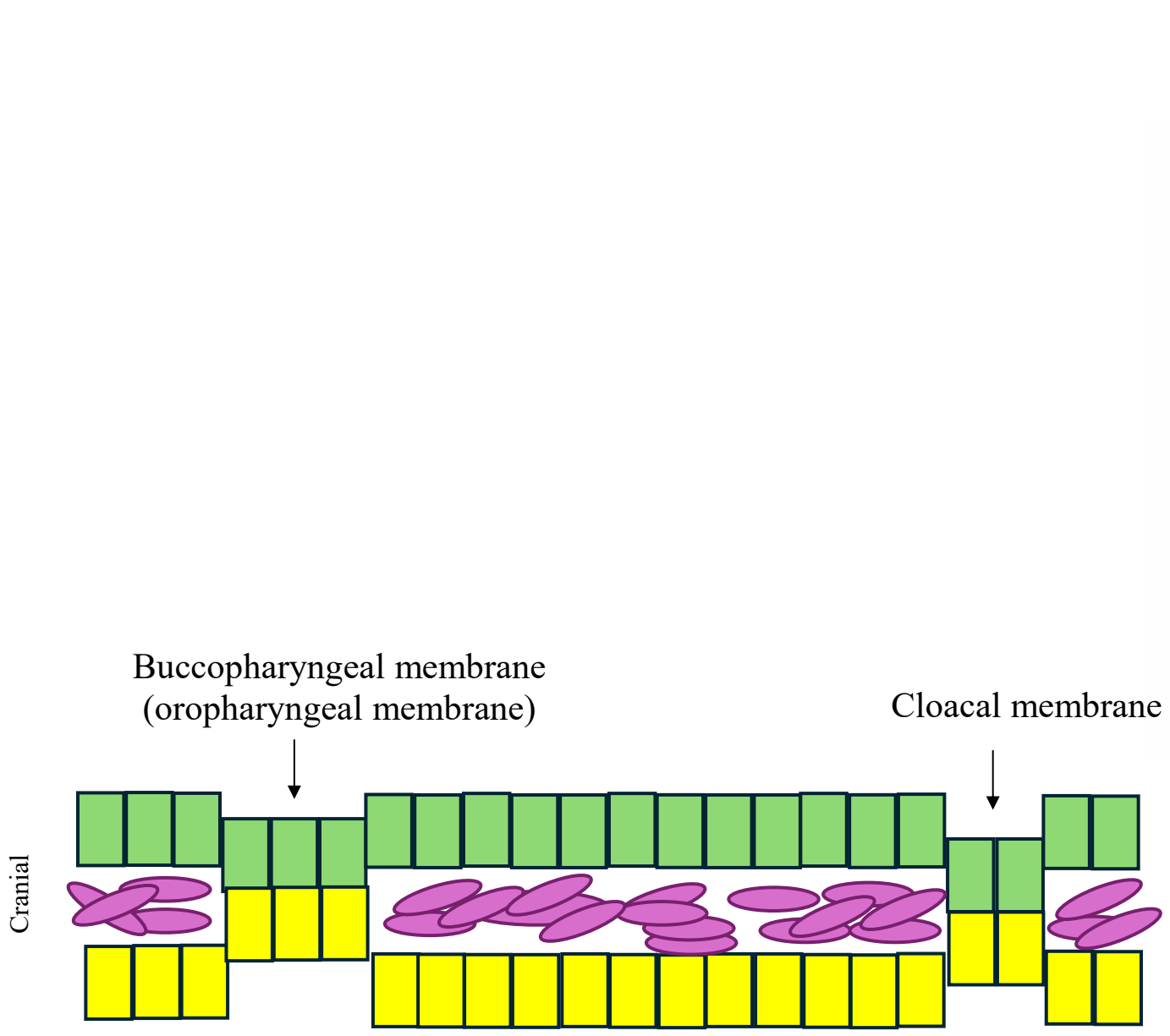
Forms **supporting tissues, muscles, cardiovascular and urogenital systems.**

- ✓ Musculoskeletal system:
  - Bone
  - Cartilage
  - Skeletal muscle
  - Connective tissue
- ✓ Cardiovascular system:
  - Heart
  - Blood and blood vessels
- ✓ Urogenital system:
  - Kidneys
  - Gonads
  - Reproductive ducts
- ✓ Serous membranes:
  - Peritoneum
  - Pleura
  - Pericardium
- ✓ Dermis of skin
- ✓ Spleen
- ✓ Adrenal cortex

**Ectoderm** → *covering & communication*

**Mesoderm** → *movement & support*

**Endoderm** → *lining & glands*


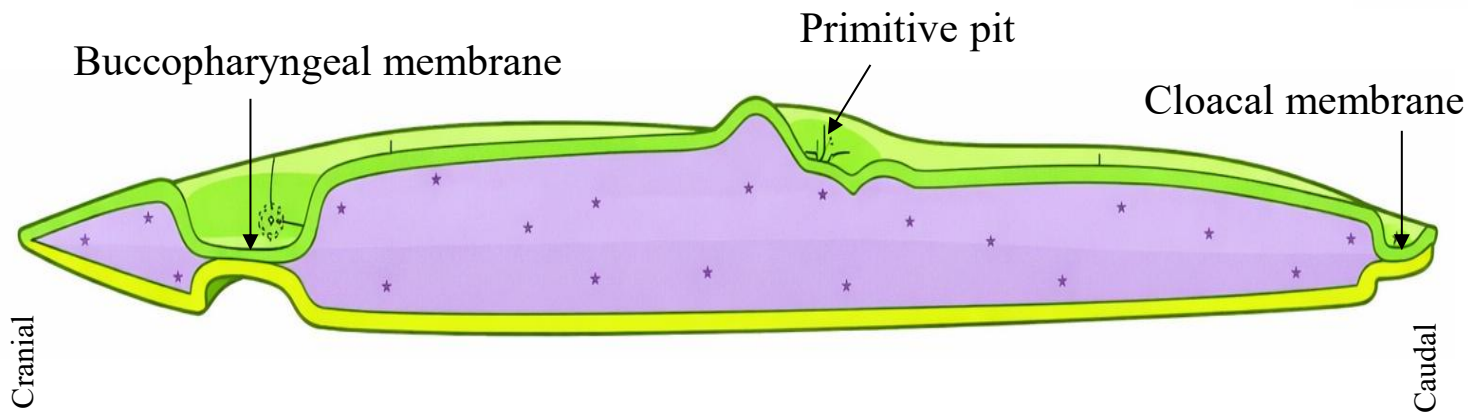
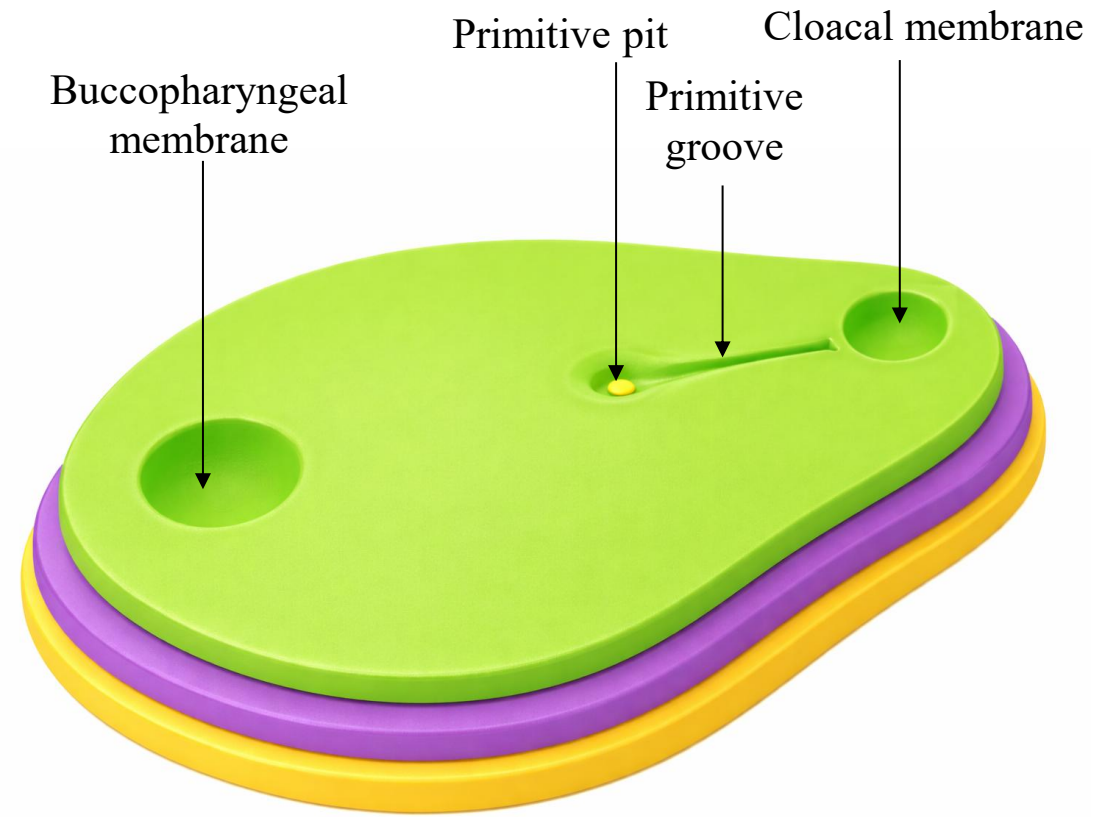


**Buccopharyngeal (oropharyngeal) membrane** forms at the cranial end of the embryonic disc. It is composed of ectoderm + endoderm only (no mesoderm)

→ Marks the future opening of the mouth

**Cloacal membrane** forms at the caudal end of the embryonic disc. It is composed of ectoderm + endoderm only (no mesoderm)

→ Marks the future site of the anus and urogenital openings

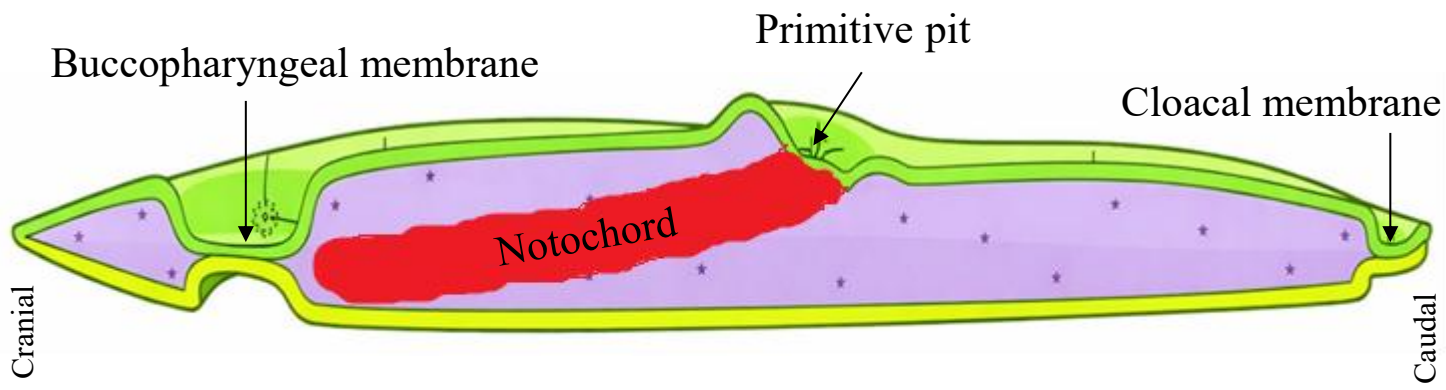
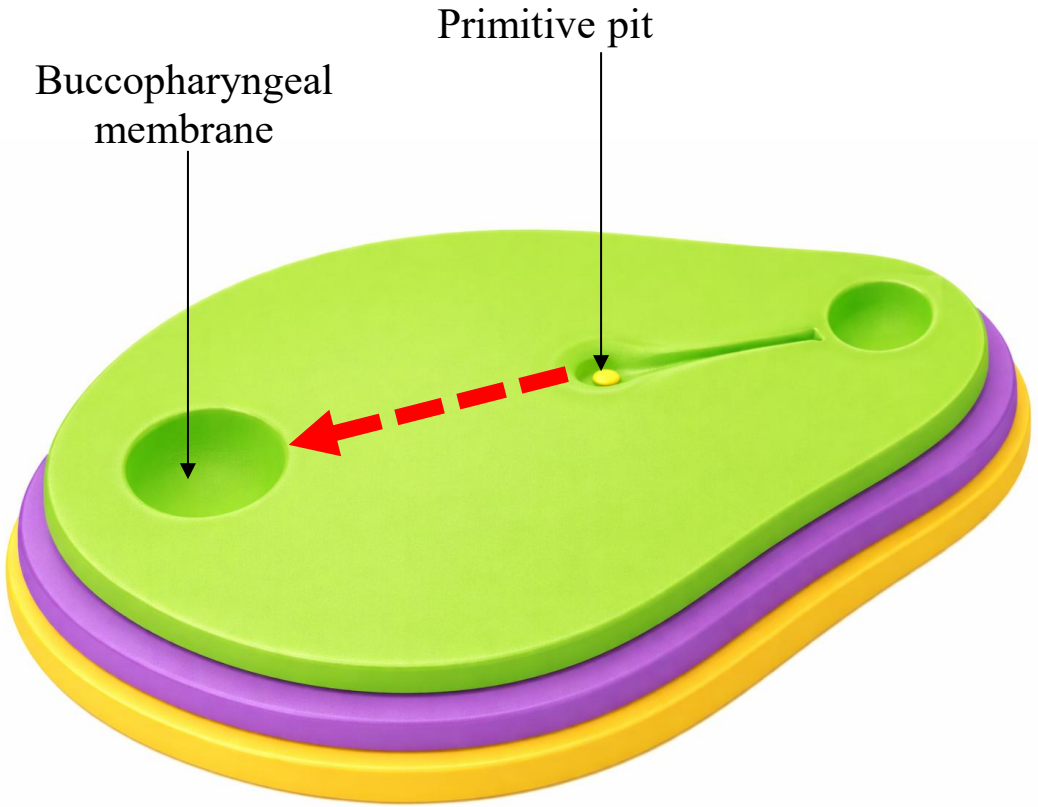


Longitudinal section

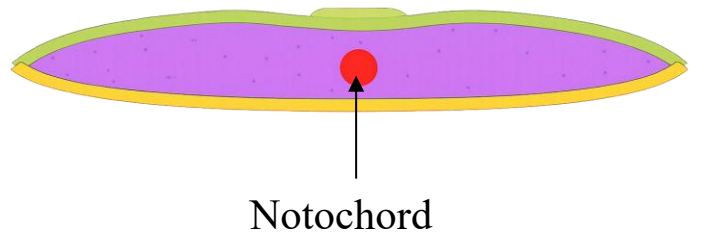
# Formation of the Notochord

- ✓ Cells migrating from the primitive node form the notochord.
- ✓ The notochord:
  - Defines the primitive axis
  - Induces overlying ectoderm to form the neural plate
  - Contributes to the nucleus pulposus of intervertebral discs

↓ ↓ ↓  
Serves as the basis for the axial skeleton



Longitudinal section



Transverse section

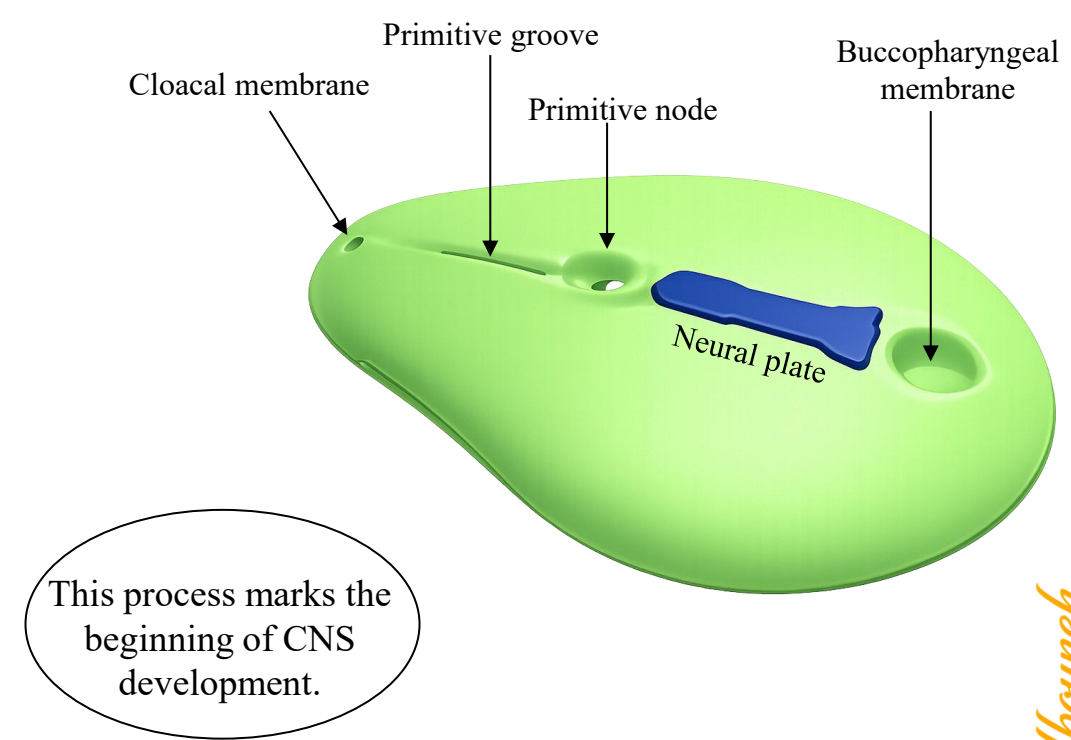
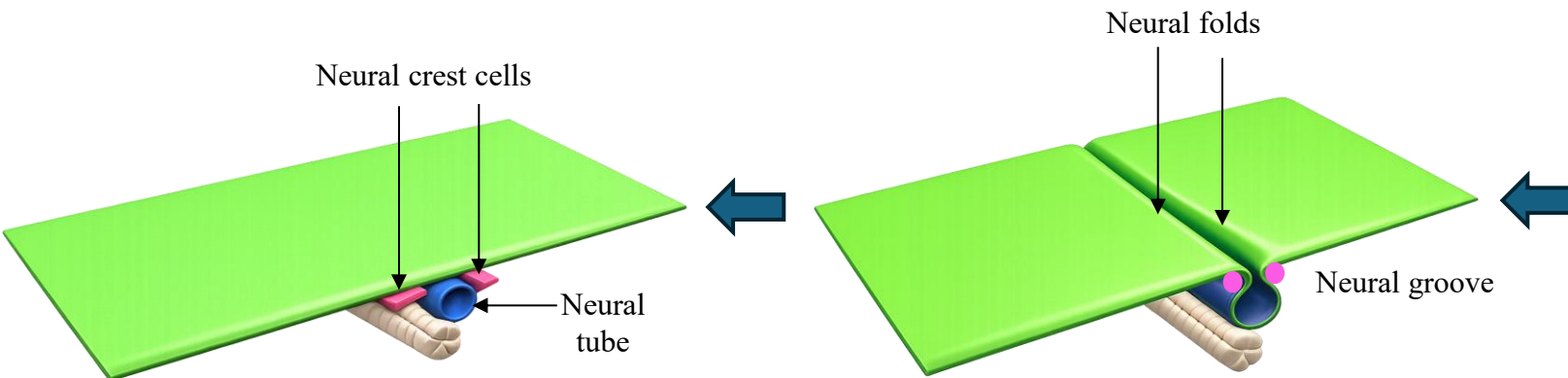
Prof. Dr. Heba Kalbouneh

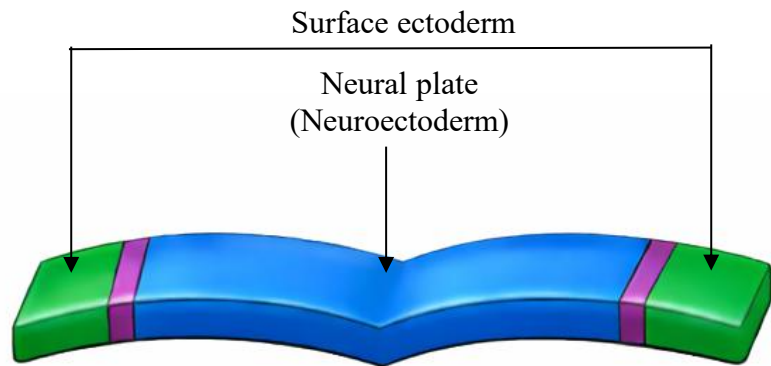
# Beginning of Neurulation

*A primordium is the earliest recognizable stage of development of an organ or structure* البرعم البدائي

- ✓ The notochord induces ectoderm to thicken and form the **neural plate**.
- ✓ The neural plate begins to invaginate, forming the **neural groove** and **neural folds**.
- ✓ As the neural folds continue to rise, they approach each other and fuse in the midline, converting the neural groove into the **neural tube**, the primordium of the brain and spinal cord.
- ✓ During fusion, cells at the crest of the neural folds detach to form **neural crest cells**, which migrate to different regions of the embryo and give rise to diverse structures.

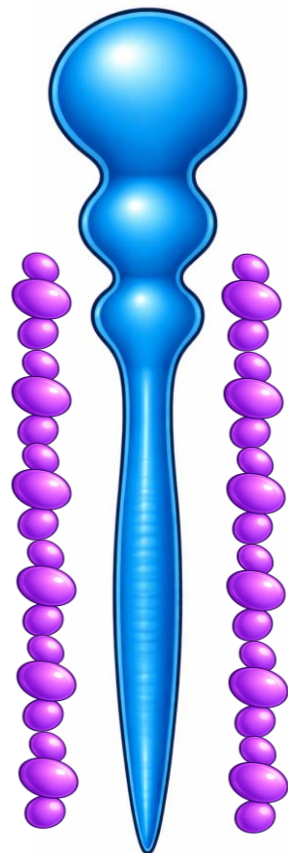
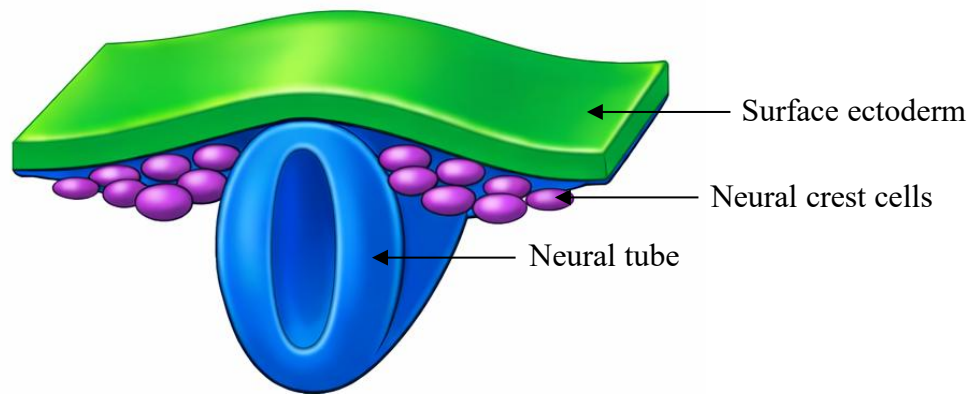
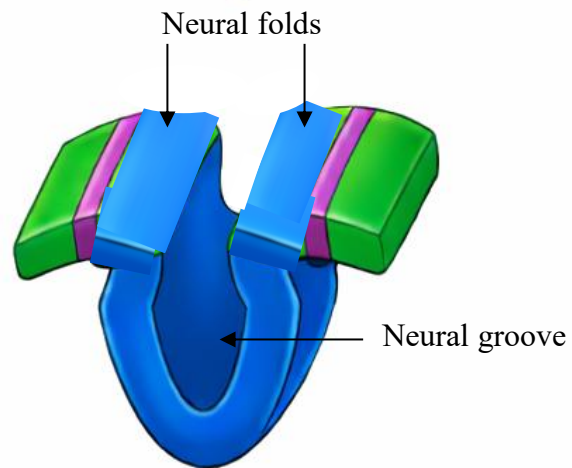
*Note: Fusion of the neural folds (neural tube formation) starts at the end of the 3rd week*





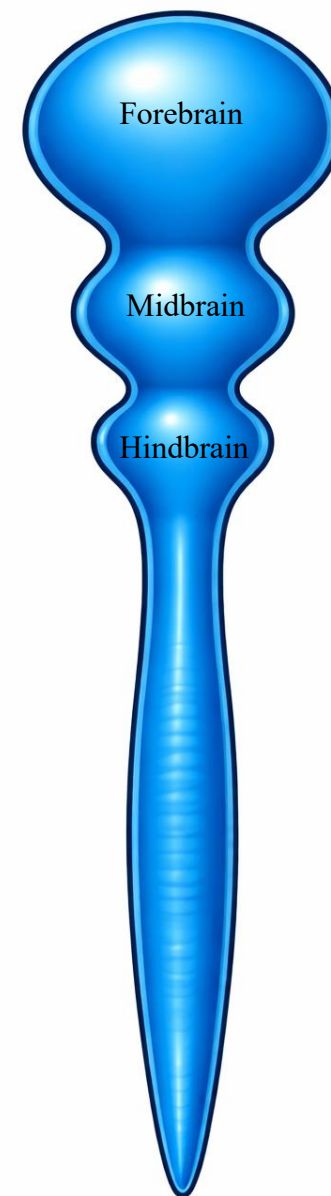In early neural tube development, the brain forms three primary vesicles:

1. Forebrain
2. Midbrain
3. Hindbrain



Brain

Spinal cord



# Dorsal view of the embryo

16 days

18 days

19 days

20 days

22 days

23 days

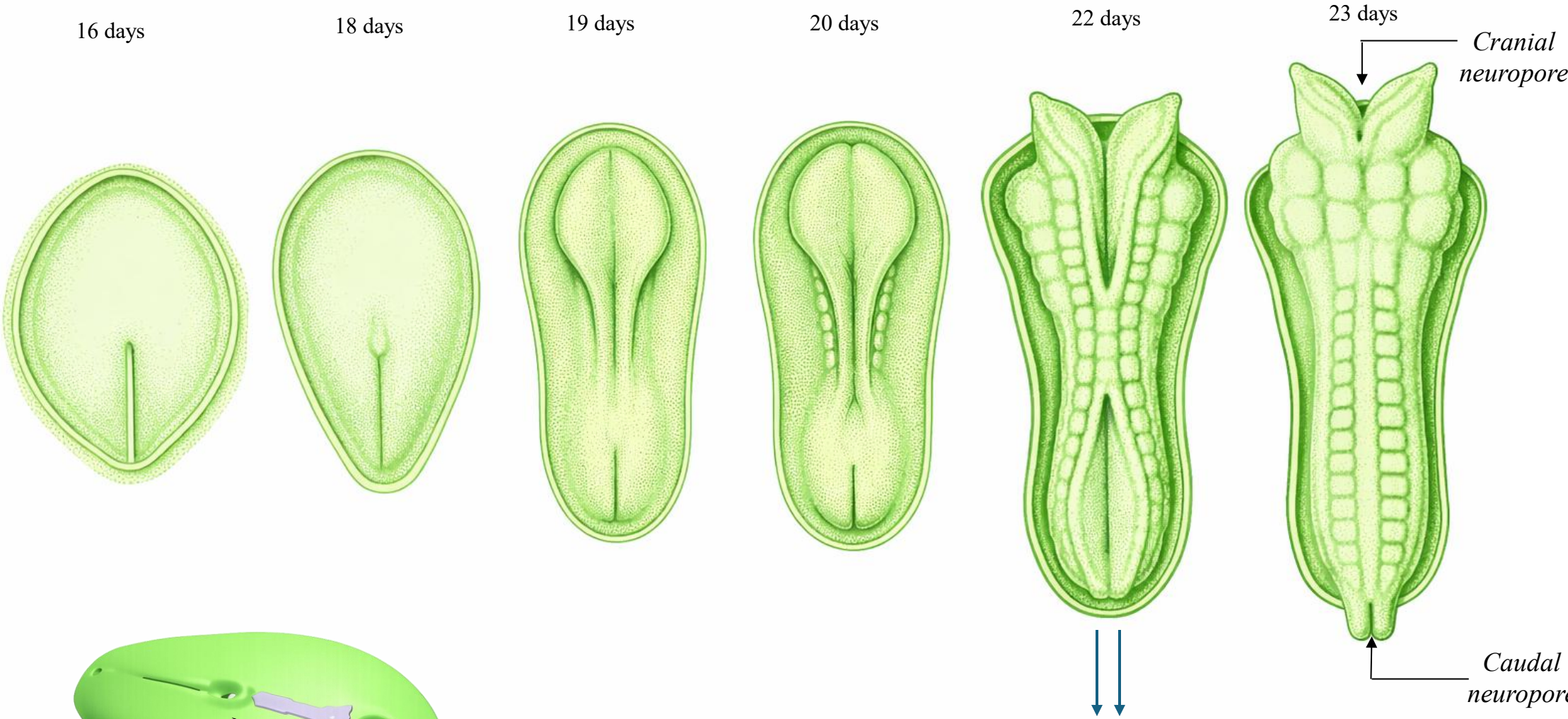
*Cranial neuropore*

*Caudal neuropore*

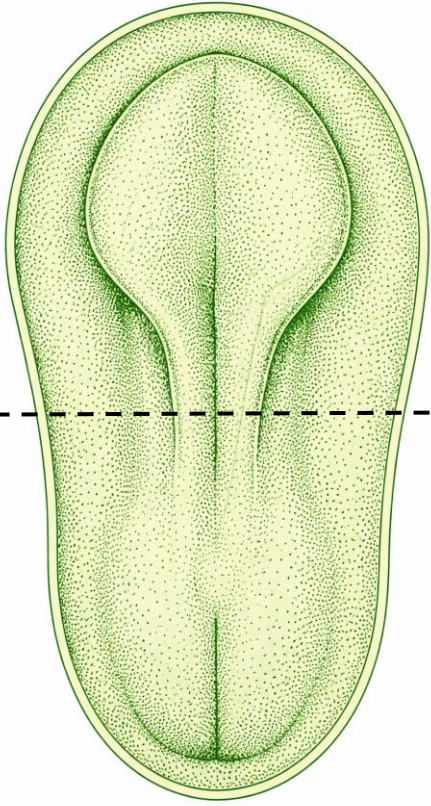
Neural plate

*Note: Fusion of the neural folds to form the neural tube begins at the end of the third week (around day 22) and is completed during the fourth week with closure of the cranial and caudal neuropores.*

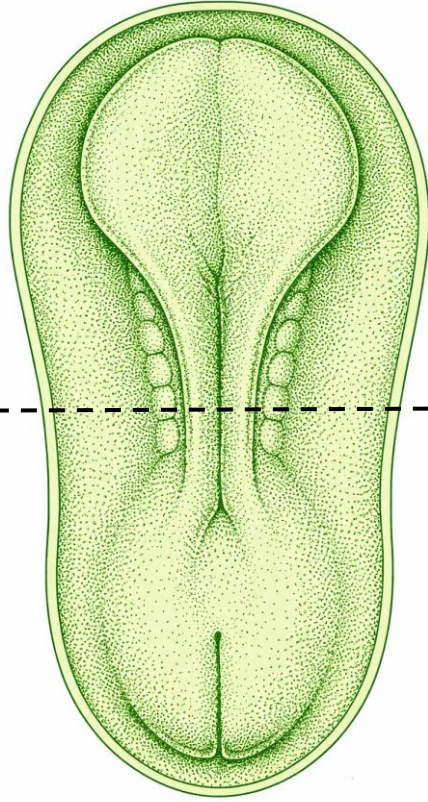
*Prof. Dr.  
Heba Kalbounieh*



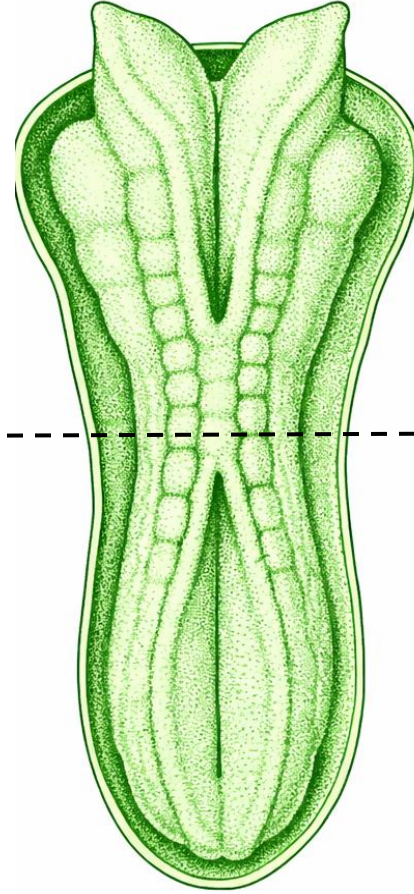
19 days



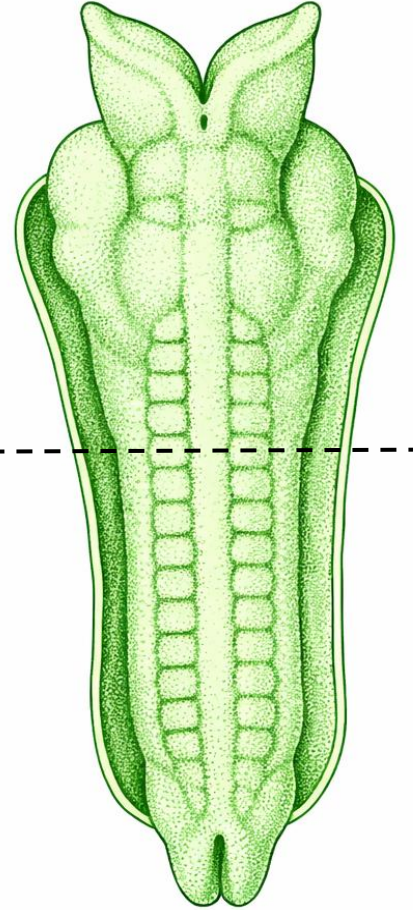
20 days



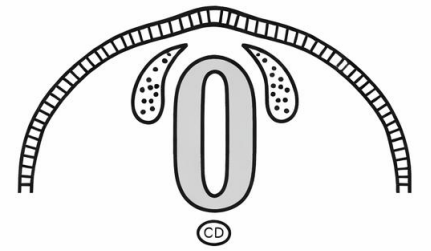
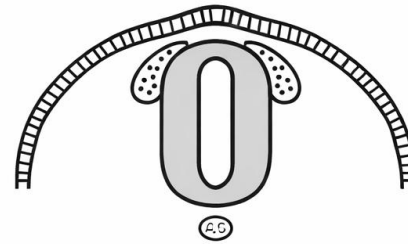
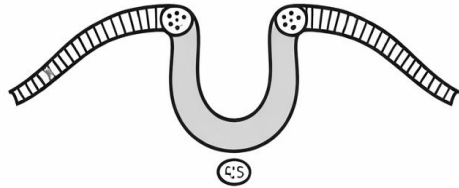
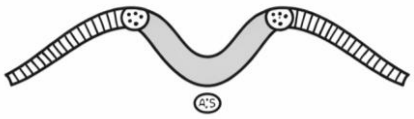
22 days



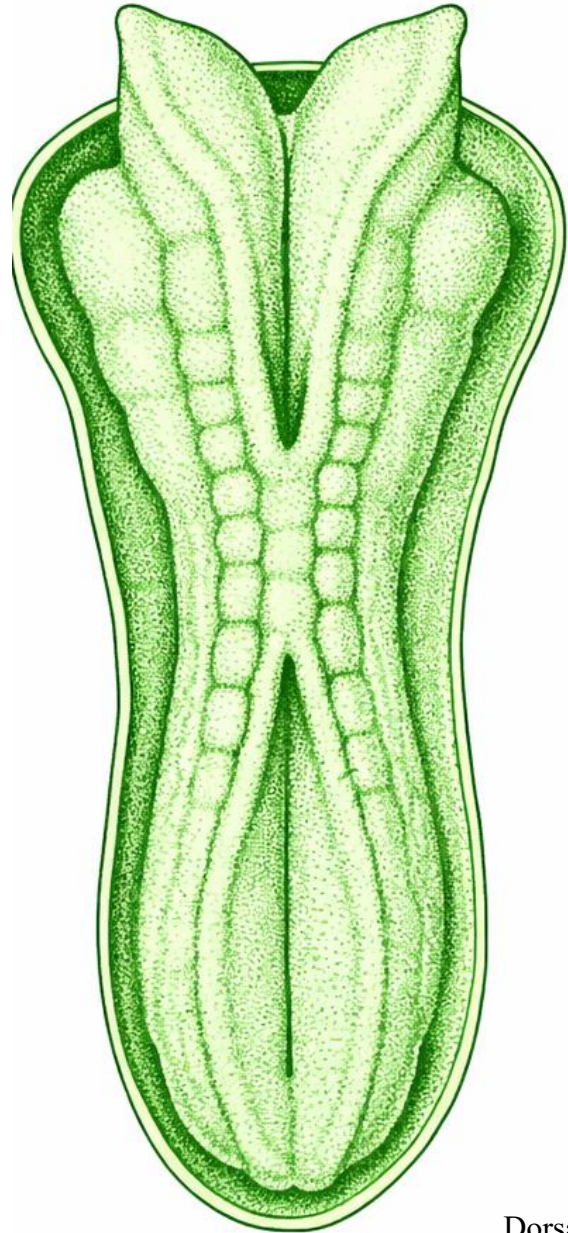
23 days



*Prof. Dr.  
Heba Kalbouneh*

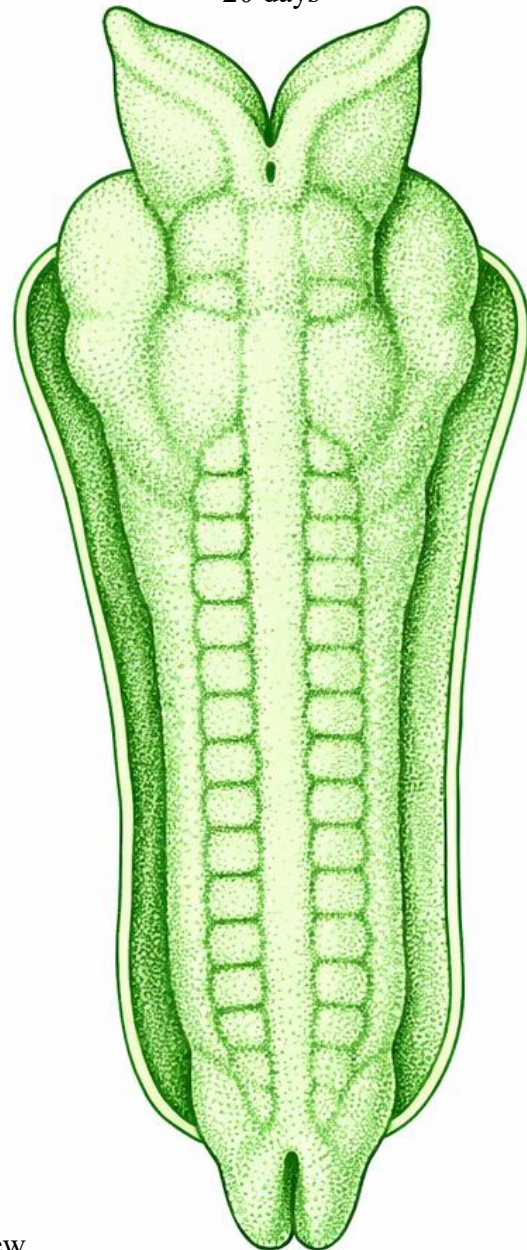


19 days

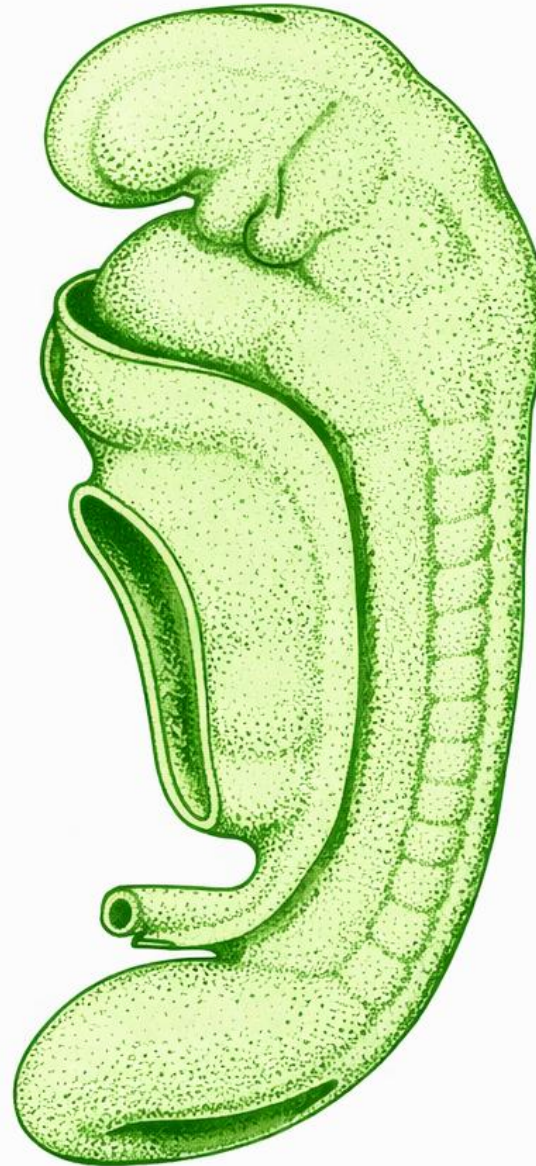


Dorsal view

20 days




25 days



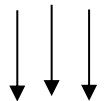
Lateral view

28 days

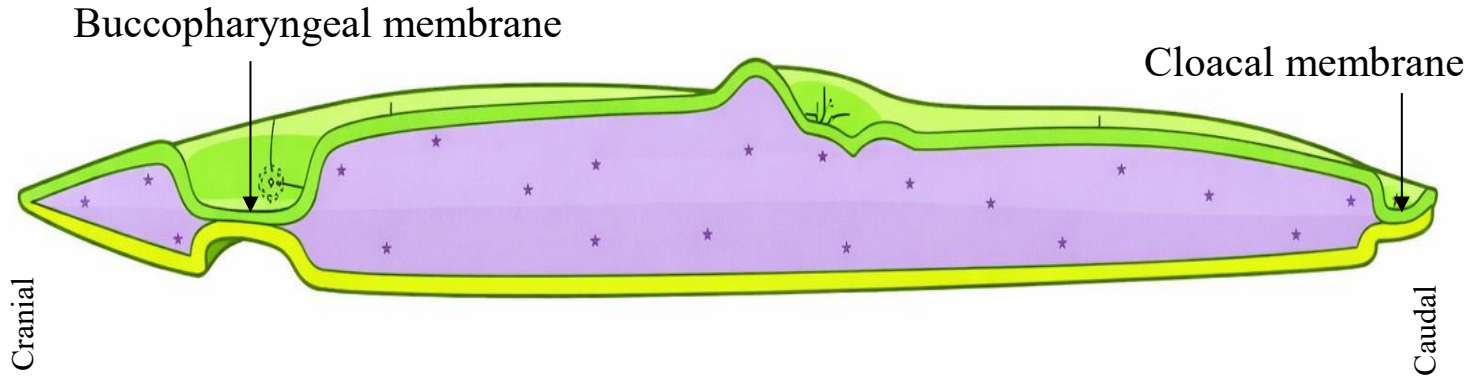
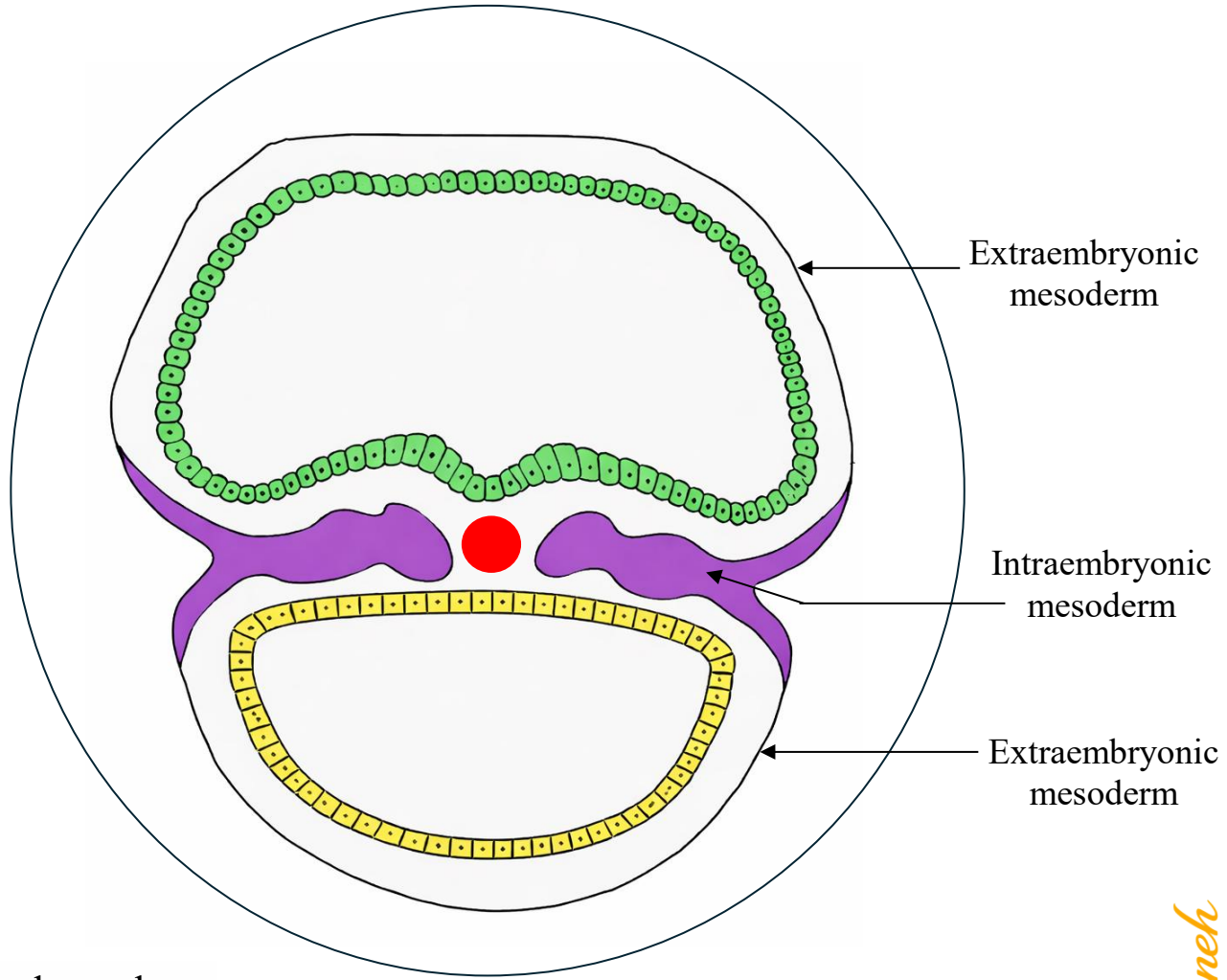


# Formation of Intraembryonic Mesoderm

- ✓ Intraembryonic mesoderm merges with the extraembryonic mesoderm at the periphery of the embryonic disc.
- ✓ By the end of the 3<sup>rd</sup> week, mesoderm lies between the embryonic ectoderm and embryonic endoderm everywhere EXCEPT in the region of the:
  - ✓ Buccopharyngeal membrane
  - ✓ Cloacal membrane



In these regions, the embryonic ectoderm and endoderm are fused, and mesoderm is absent.



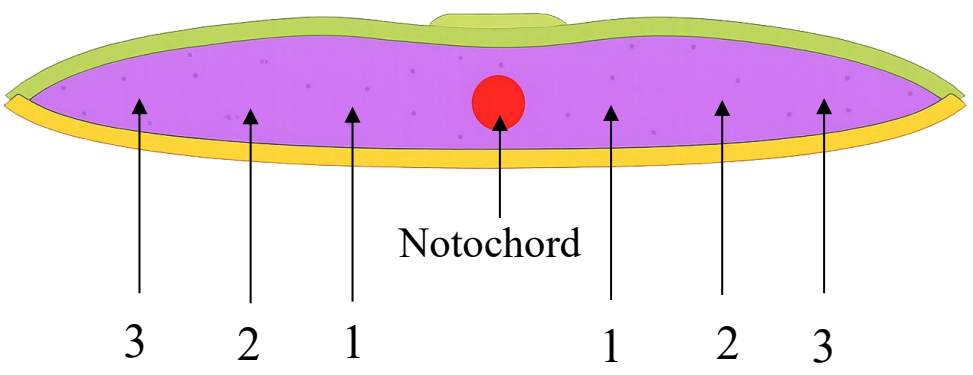
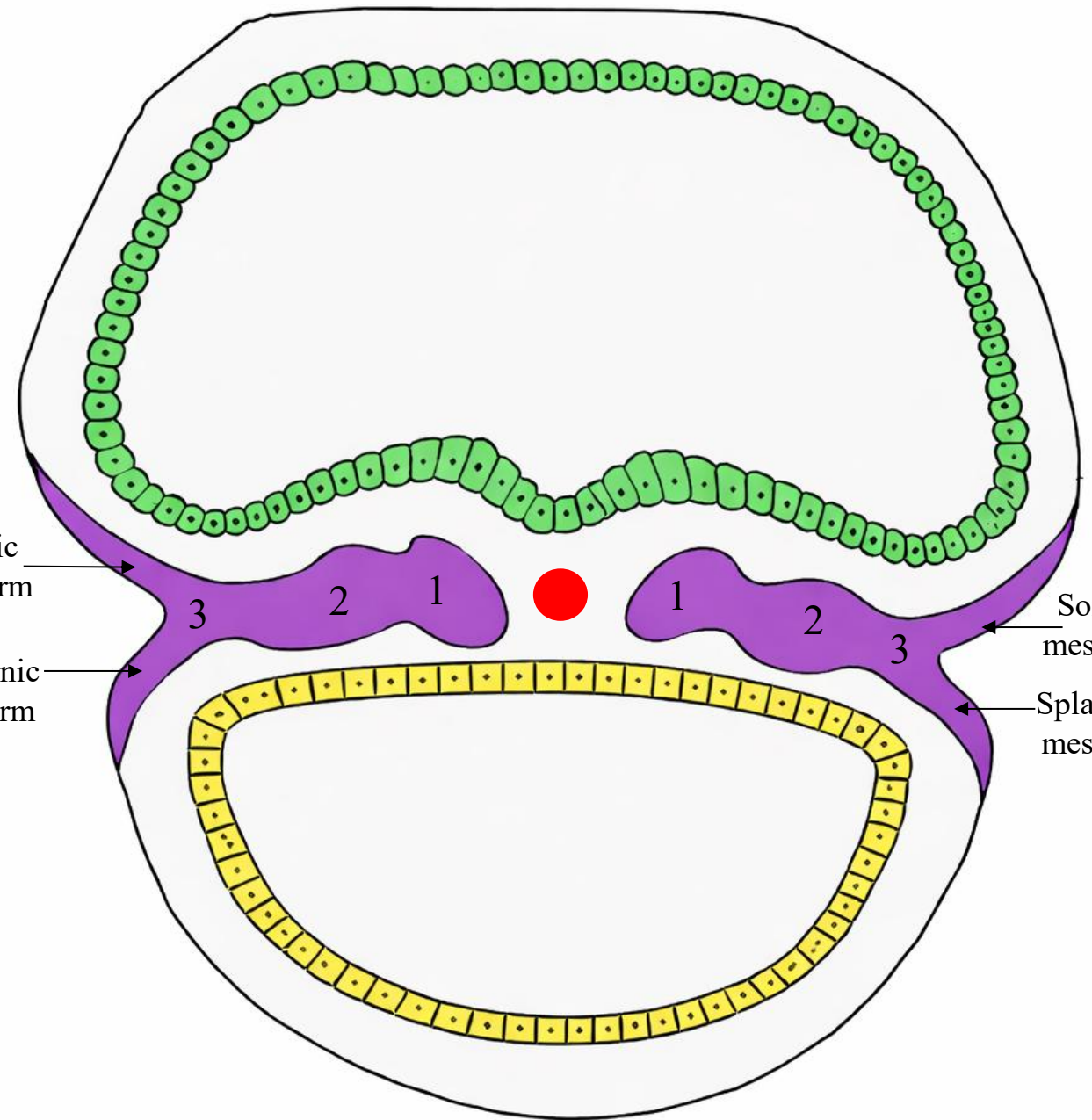
# Differentiation of Intraembryonic Mesoderm

The intraembryonic mesoderm differentiates into:

- 1- Paraxial mesoderm
- 2- Intermediate mesoderm
- 3- Lateral plate mesoderm

The lateral plate mesoderm splits into **two layers**:

- Somatic (parietal) layer
- Splanchnic (visceral) layer



Notochord

# Intra-embryonic Mesoderm (Lateral Plate Mesoderm)

After the intra-embryonic coelom forms, the lateral plate mesoderm splits into two layers:

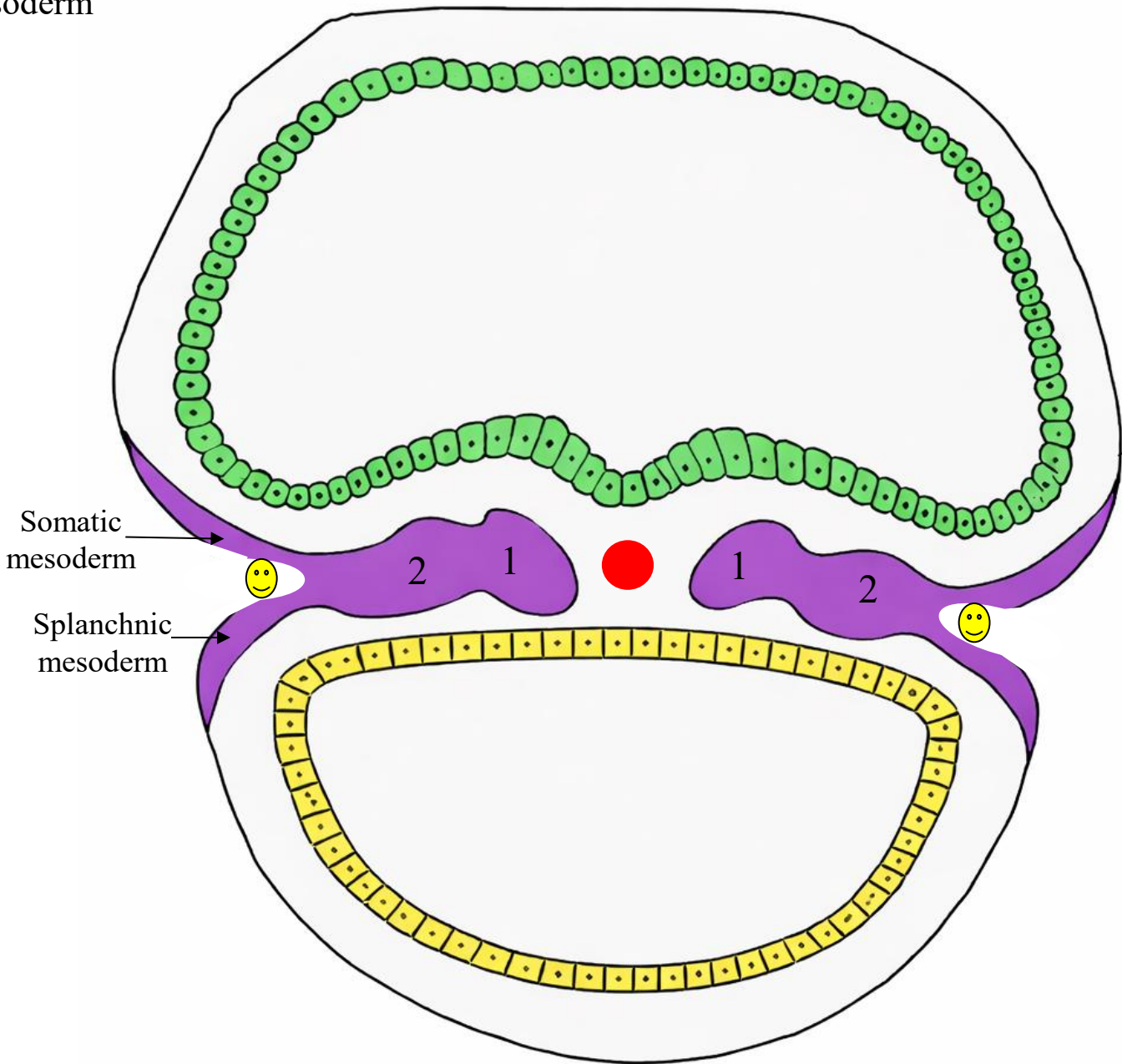
## Intraembryonic somatic mesoderm

- Also called:
- ✓ Parietal mesoderm
  - ✓ Somatopleure (when combined with ectoderm)
- Description:
- ✓ Lies adjacent to ectoderm
  - ✓ Forms the body wall
- Somatopleure = Ectoderm + somatic mesoderm

## Intraembryonic splanchnic mesoderm

- Also called:
- ✓ Visceral mesoderm
  - ✓ Splanchnopleure (when combined with endoderm)
- Description:
- ✓ Lies adjacent to endoderm
  - ✓ Forms the gut wall and visceral organs
- Splanchnopleure = Endoderm + splanchnic mesoderm

☺ Intra-embryonic coelom

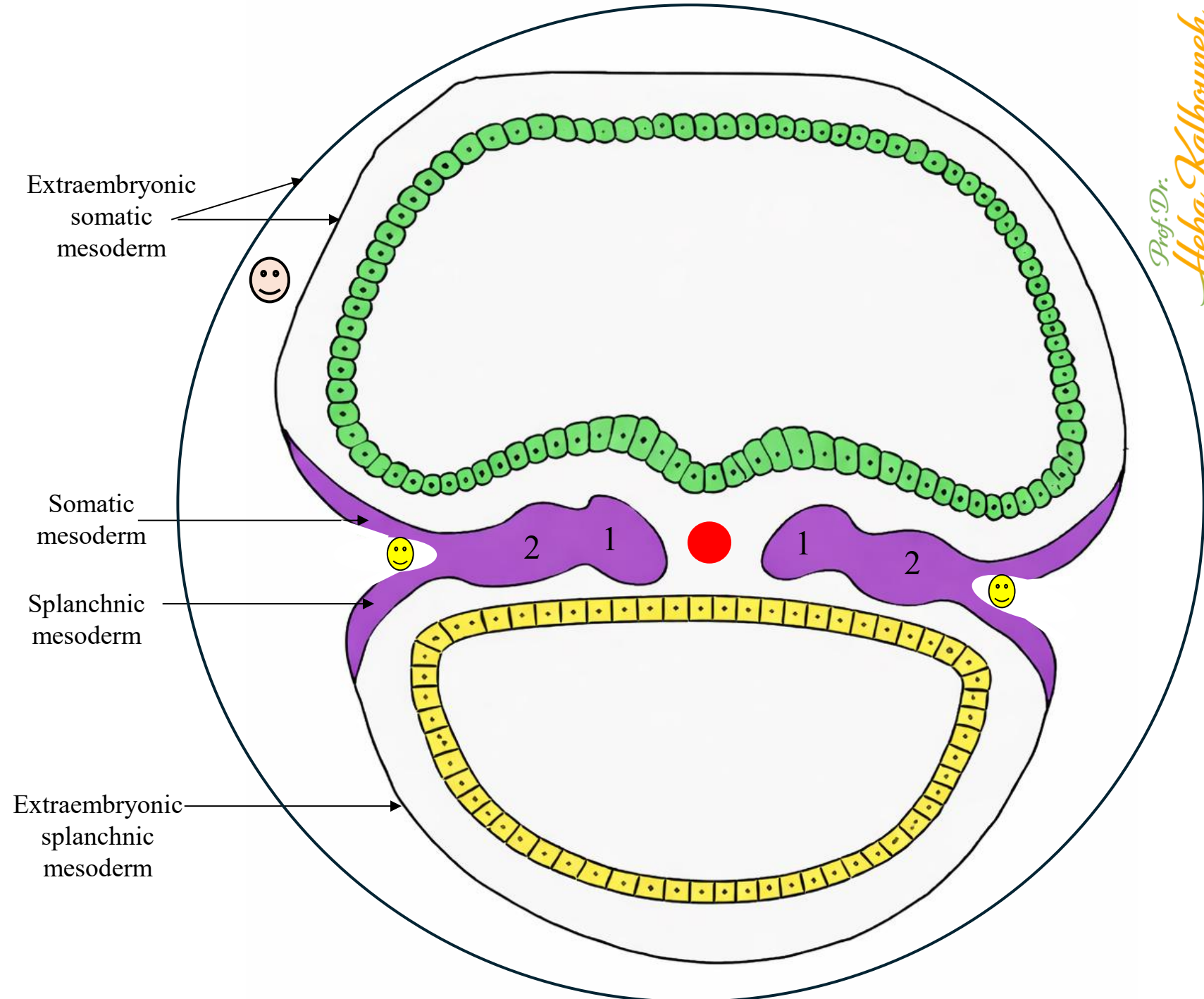




Notes:

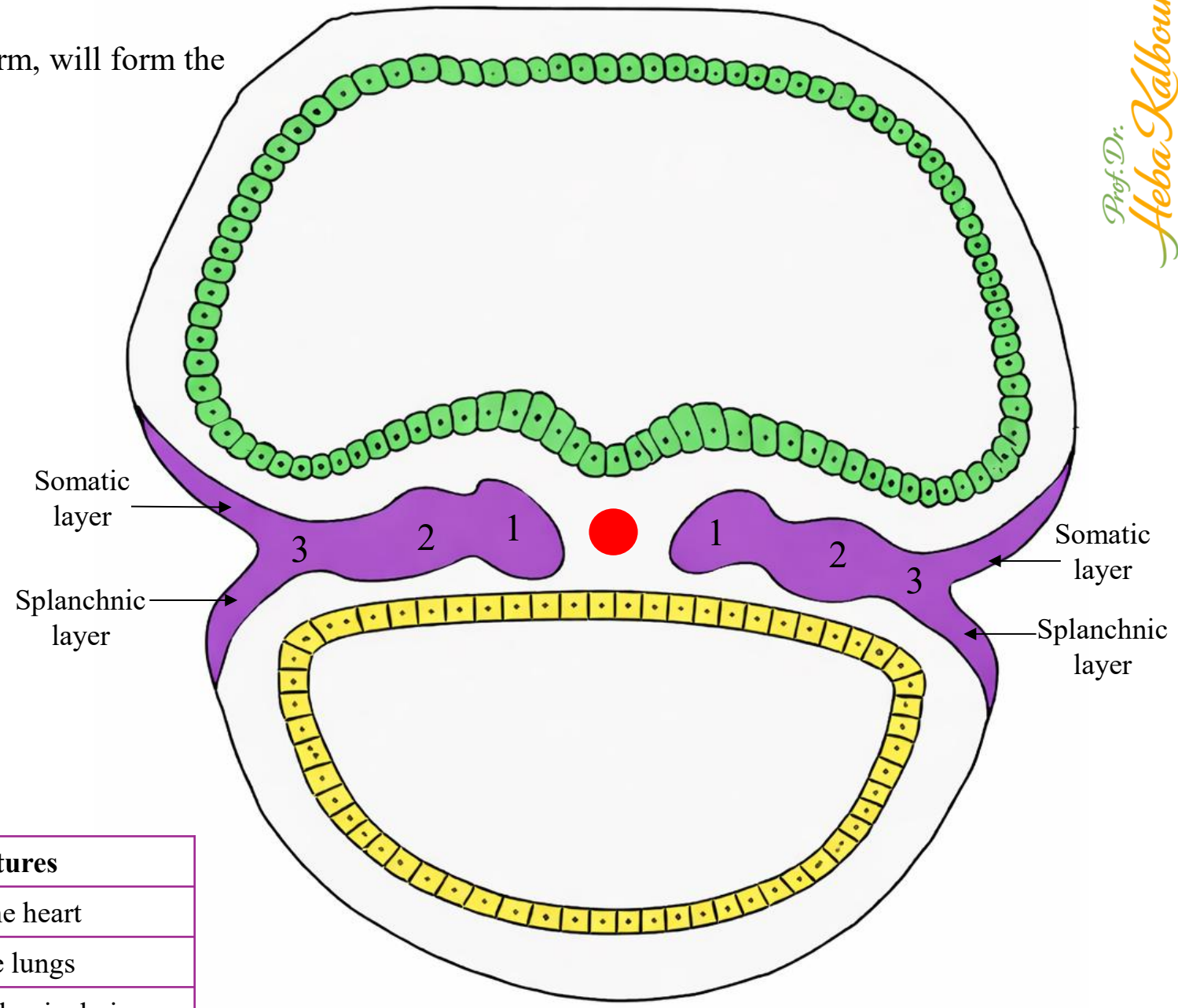
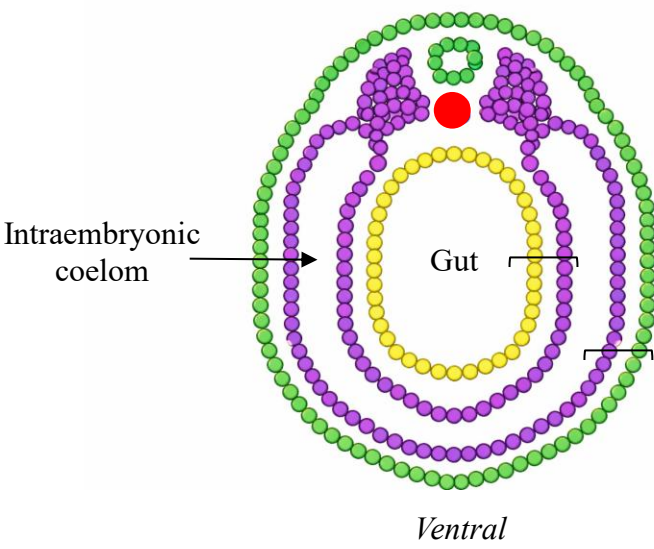
- ✓ The somatic layer of the lateral plate mesoderm (intra-embryonic mesoderm) is continuous with the somatic layer of the extra-embryonic mesoderm.
- ✓ The splanchnic layer of the lateral plate mesoderm (intra-embryonic mesoderm) is continuous with the splanchnic layer of the extra-embryonic mesoderm.
- ✓ The intra-embryonic coelom is continuous with the extra-embryonic coelom (chorionic cavity). This continuity is present at the margins of the embryonic disc, where the intra-embryonic coelom communicate freely with the extra-embryonic coelom (chorionic cavity) before later partitioning into the definitive body cavities.

- ☺ Intra-embryonic coelom
- 😊 Extra-embryonic coelom (chorionic cavity)

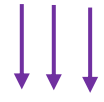


**Somatic mesoderm**, together with overlying ectoderm, will form the **lateral and ventral body wall.**

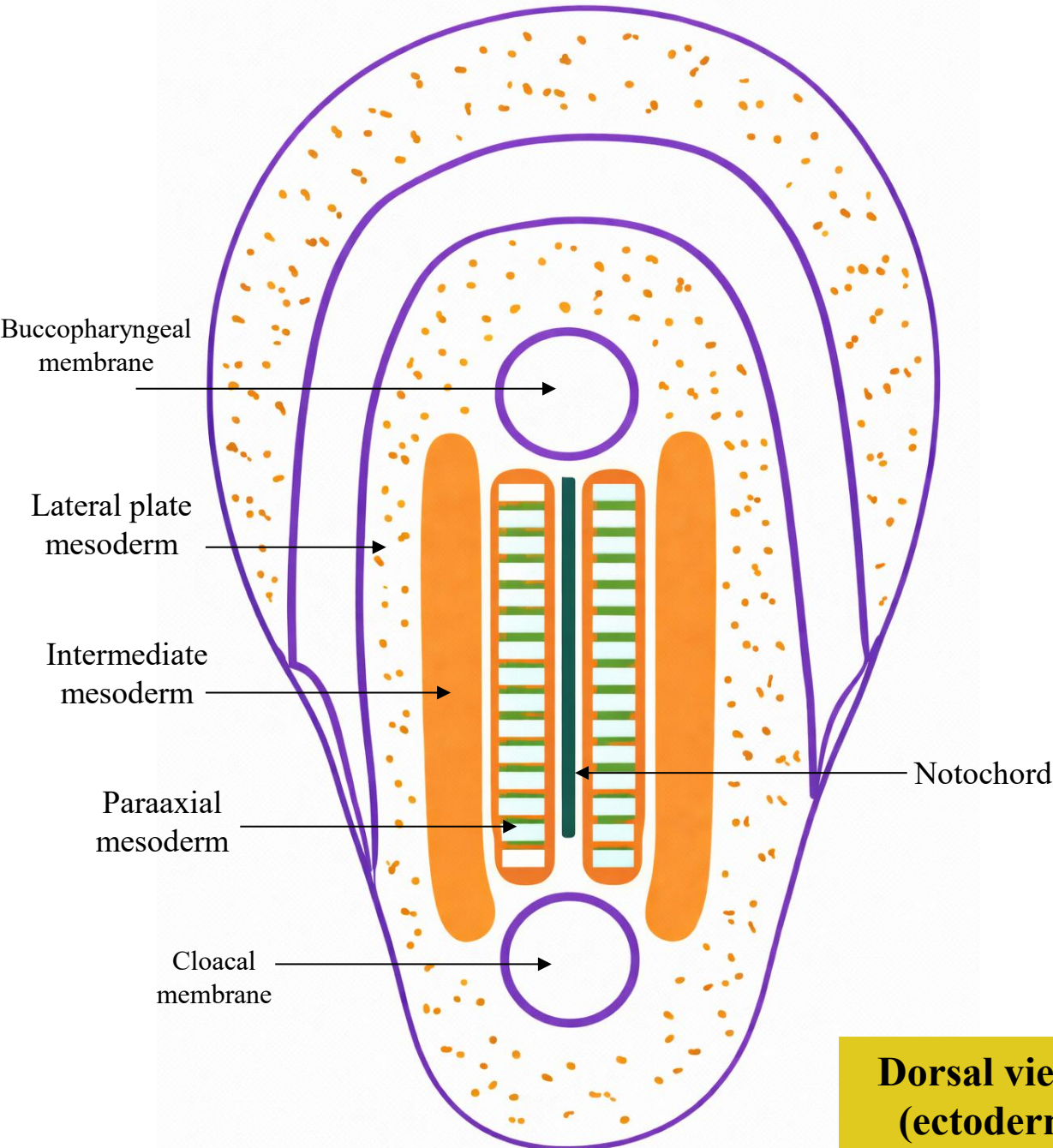
**Splanchnic mesoderm**, together with embryonic endoderm, will form the **wall of the gut.**



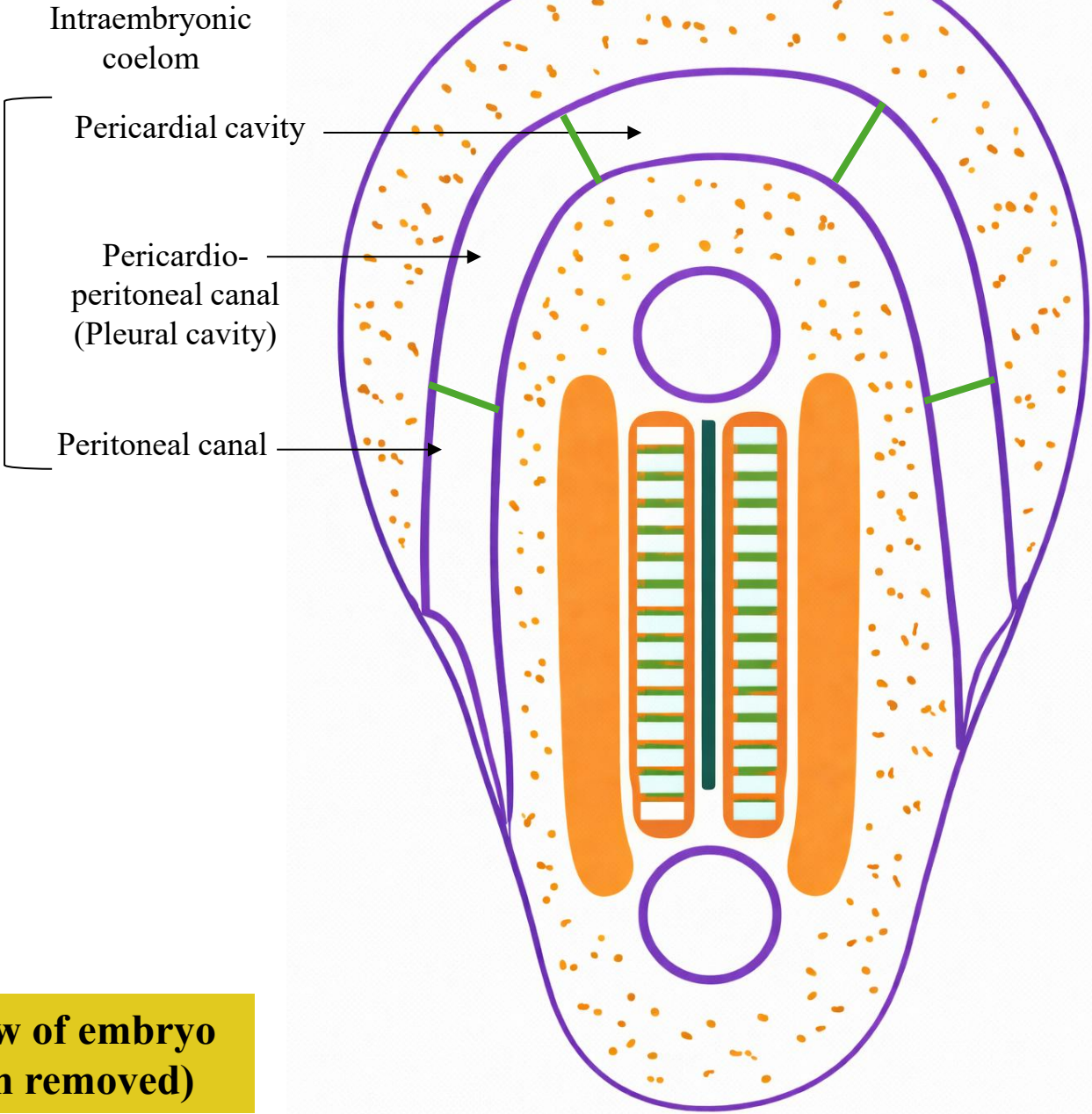
The intraembryonic coelom develops into the **three main body cavities:**



Cavity	Location	Main Structures
Pericardial cavity	Thoracic region	Surrounds the heart
Pleural cavities	Thoracic region	Surround the lungs
Peritoneal cavity	Abdominal region	Contains abdominal viscera

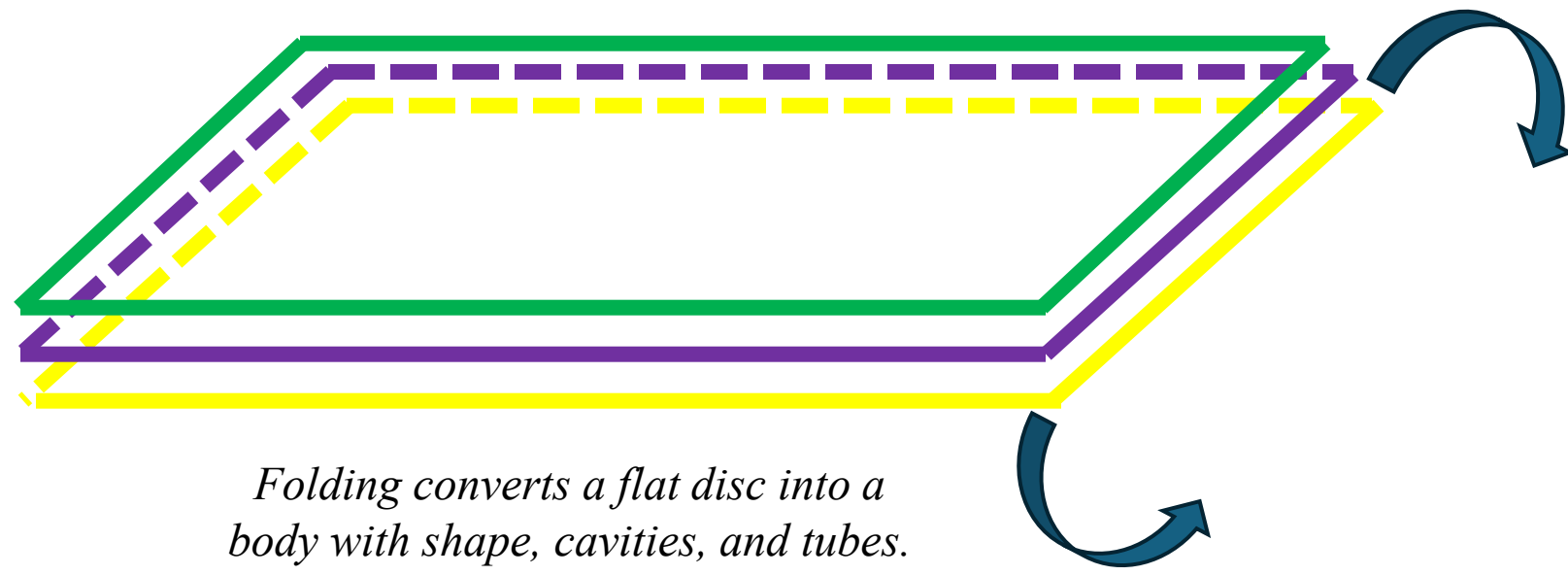


**Dorsal view of embryo (ectoderm removed)**




# Embryonic Folding →→→ From trilaminar disc to human body form

Trilaminar disc  
(3<sup>rd</sup> week)

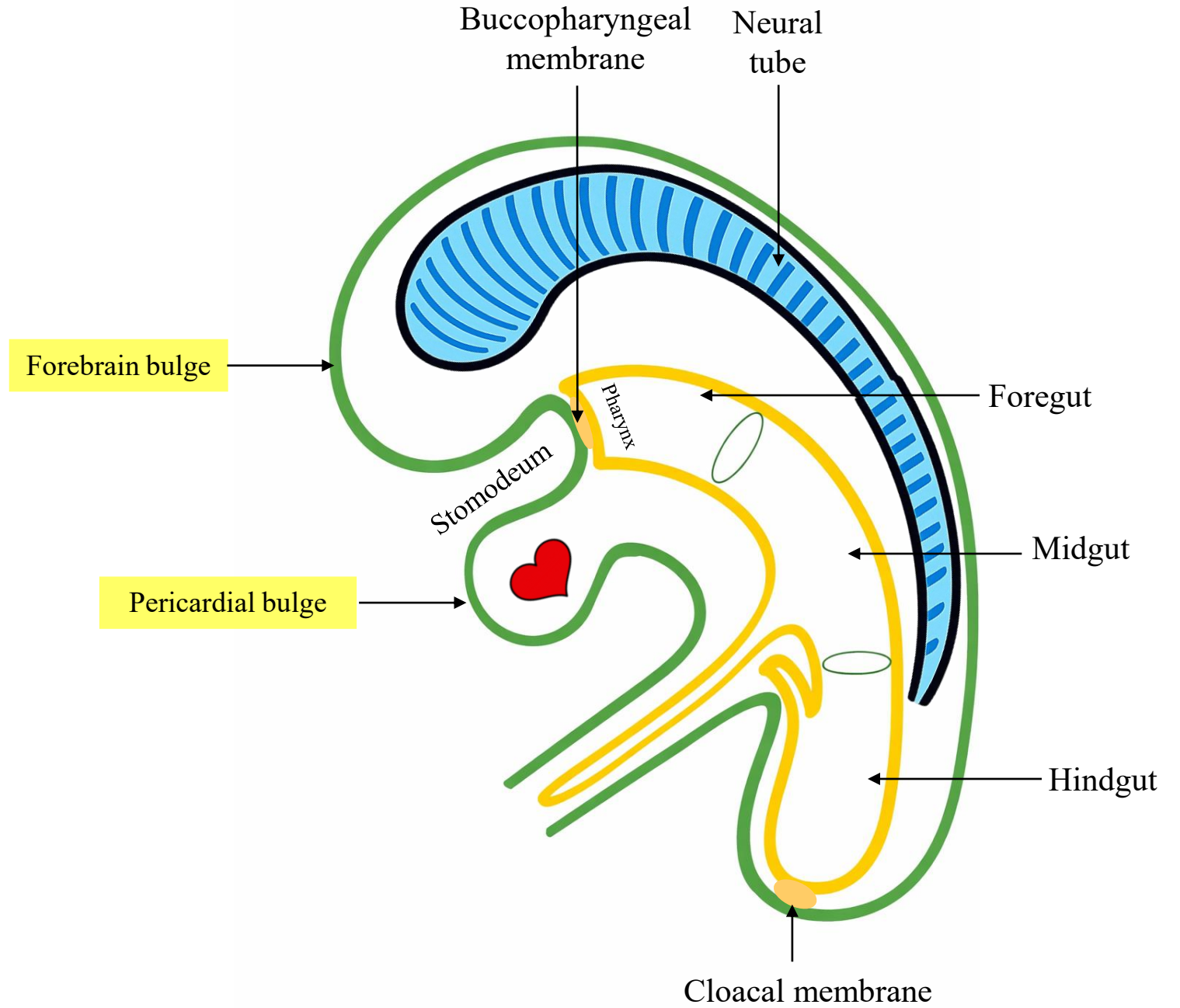


Folding  
(4<sup>th</sup> week)



Mesenchyme

## L.S. in folded embryo



# Differentiation of Intraembryonic Mesoderm

The intraembryonic mesoderm differentiates into:

## 1- Paraxial mesoderm → forms somites

Somites give rise to:

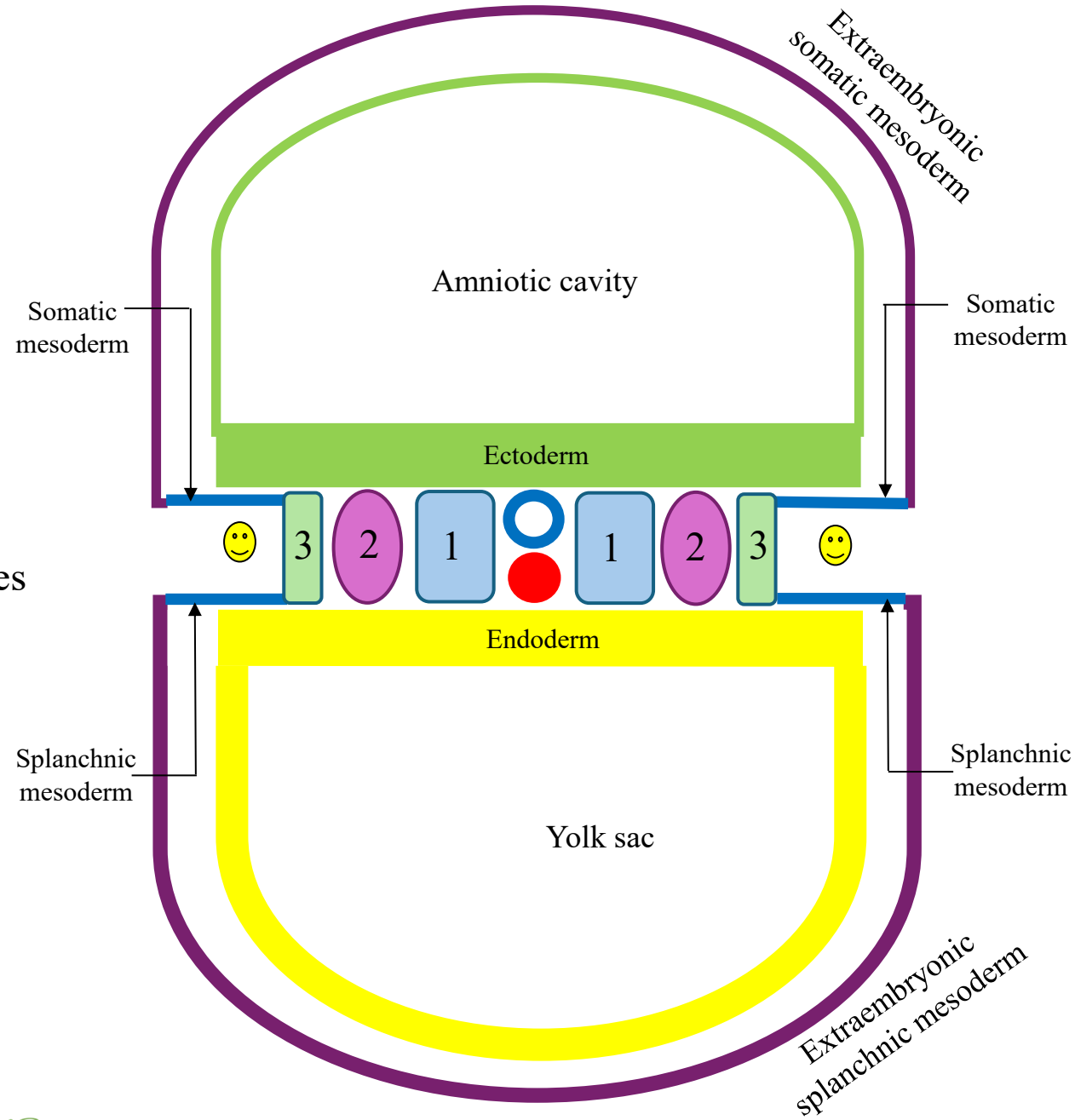
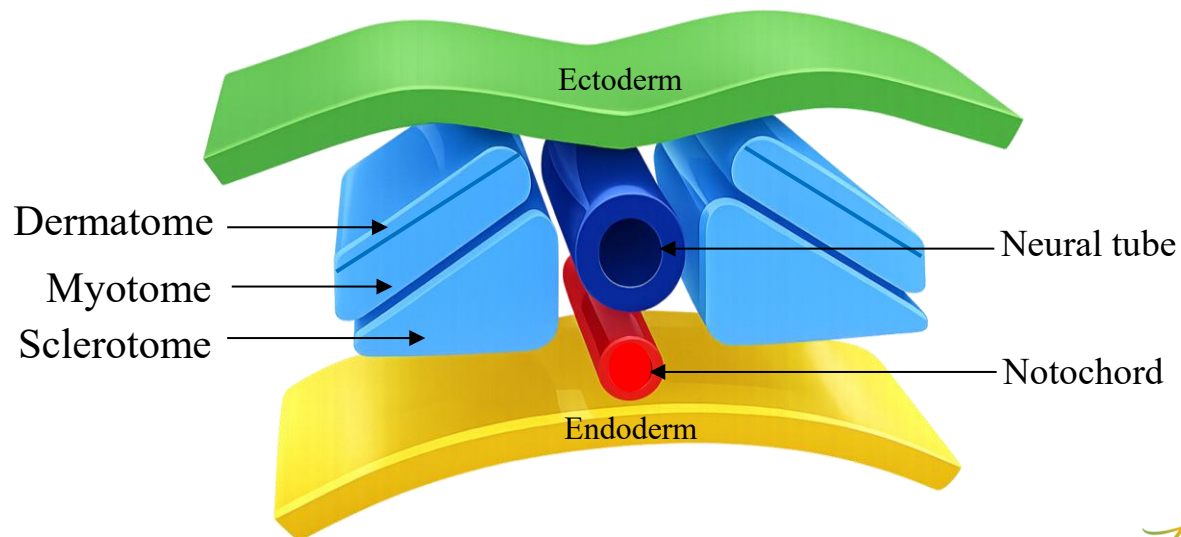
- **Sclerotome** (vertebrae & ribs)
- **Myotome** (skeletal muscles)
- **Dermatome** (dermis)

## 2- Intermediate mesoderm → urogenital system

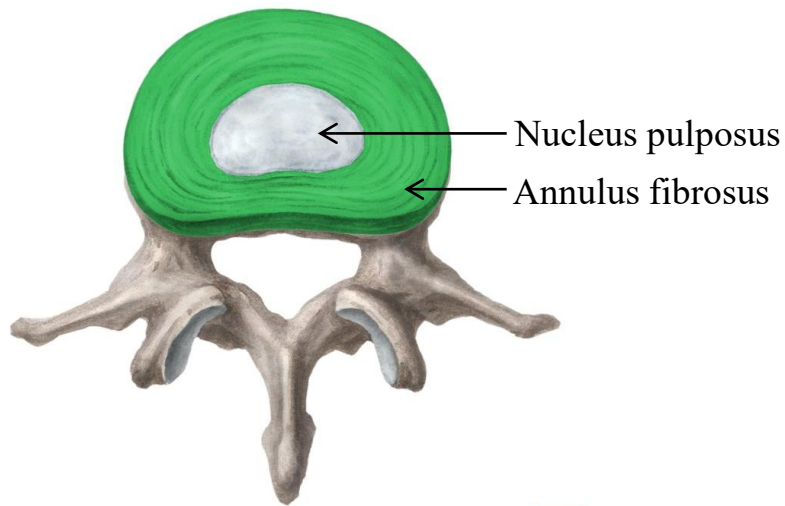
## 3- Lateral plate mesoderm → splits into:

- **Somatic (parietal) layer**
- **Splanchnic (visceral) layer**

→ forms the **intraembryonic coelom** → forms main body cavities



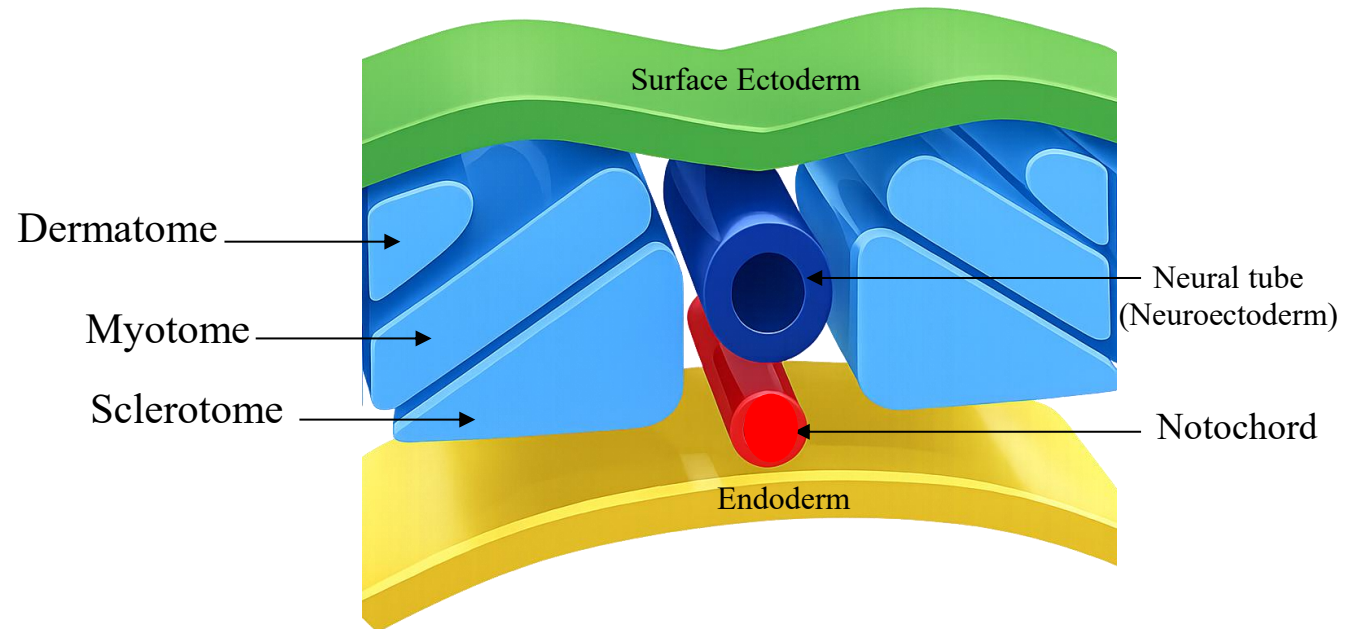
Somite Component	Main Derivative
<b>Sclerotome</b>	Vertebrae, ribs, and intervertebral discs (annulus fibrosus)
<b>Myotome</b>	Skeletal muscles of the back, body wall (intercostal, abdominal), and limbs
<b>Dermatome</b>	Dermis of the skin



© www.kenhub.com KEN HUB

*Remember:*

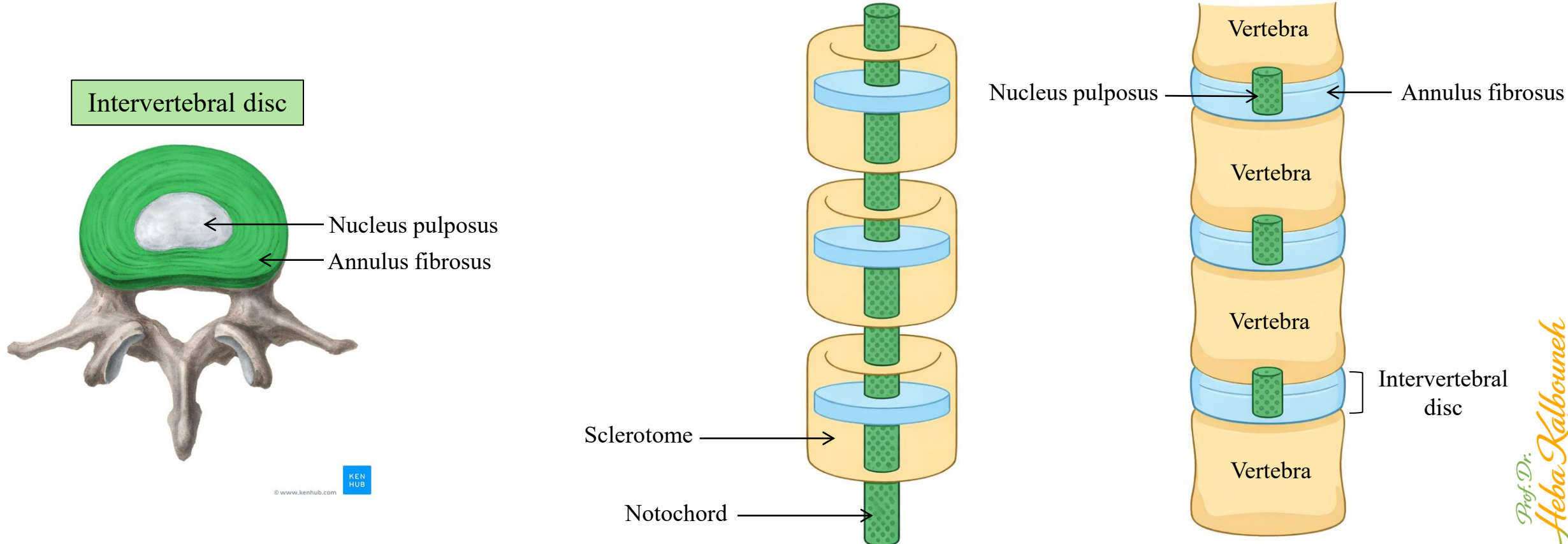
*The notochord mostly degenerates  
It persists only as the nucleus pulposus*



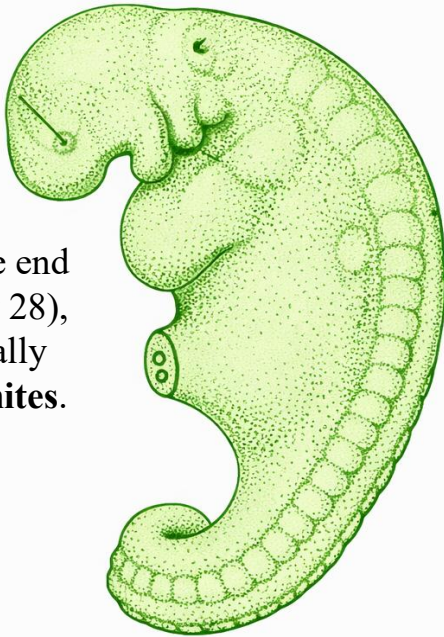
The myotome splits into:

- ✓ **Epimere (epaxial myotome)** → deep back muscles  
*Innervated by dorsal rami*
- ✓ **Hypomere (hypaxial myotome)** → body wall and limb muscles  
*Innervated by ventral rami*

The **notochord** is a transient, rod-shaped mesodermal structure that plays a crucial role in early embryonic development. It serves as the **primary axial support of the embryo** and establishes the **primitive axis**, helping to define the future vertebral column. More importantly, the notochord functions as a **major signaling center**, releasing molecular signals that induce the overlying ectoderm to differentiate into the **neural plate**, the precursor of the central nervous system. It also influences the differentiation of surrounding mesoderm, particularly the **paraxial mesoderm**, guiding the formation of somites and vertebrae. During vertebral development, most of the notochord degenerates, but its remnants persist within the **intervertebral discs as the nucleus pulposus**, contributing to the structure and cushioning function of the spine.



- ✓ Somites begin forming around day 20 → They are added in a craniocaudal direction (from head toward tail).
- ✓ They form at a rate of ~3 pairs per day.
- ✓ At the end of the fifth week, 42 to 44 pairs are present.
- ✓ There are 4 occipital, 8 cervical, 12 thoracic, 5 lumbar, 5 sacral, and 8 to 10 coccygeal pairs.
- ✓ The first occipital and the last 5 to 7 coccygeal somites later disappear, while the remaining somites form the axial skeleton.
- ✓ During this period of development the age of the embryo is expressed in number of somites.



Example: By the end of week 4 (~day 28), embryos typically have **24–27 somites**.

**A 25-somite embryo (approximately 28 days old)**

*Somites are blocks of mesoderm located on either side of the neural tube in the developing vertebrate embryo.*

Week 1 = days 1–7  
 Week 2 = days 8–14  
 Week 3 = days 15–21  
 Week 4 = days 22–28  
 Week 5 = days 29–35

**Number of Somites Correlated to Approximate Age (Days)**

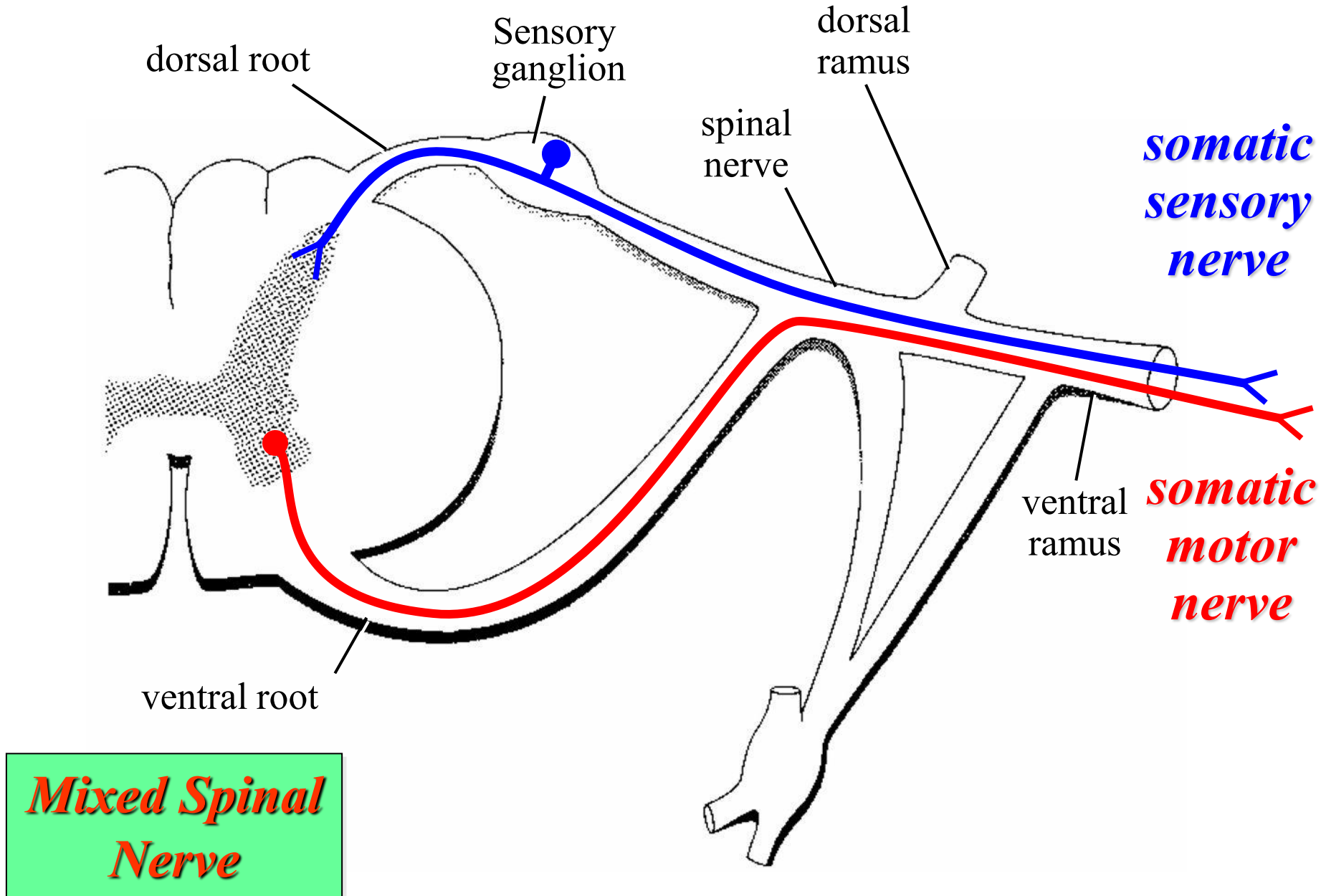
Read only 😊

Approximate Age (days)	Number of Somites
20	1–4
21	4–7
22	7–10
23	10–13
24	13–16
25	16–19
26	19–21
27	21–24
28	24–27
29	27–30
30	30–33
End of 5 <sup>th</sup> week	42–44

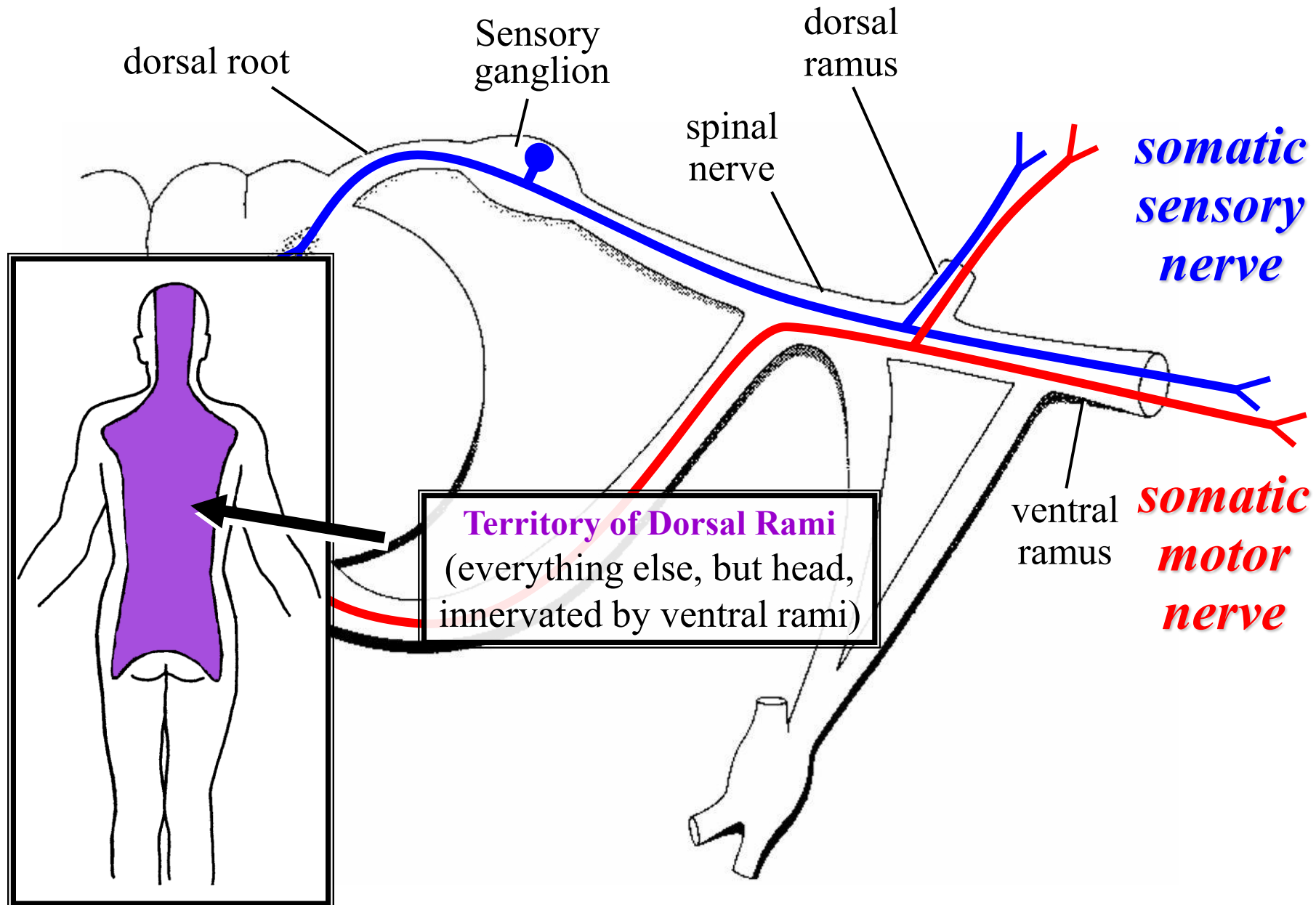
**“Why do we use somite number instead of days?”**  
 Because:

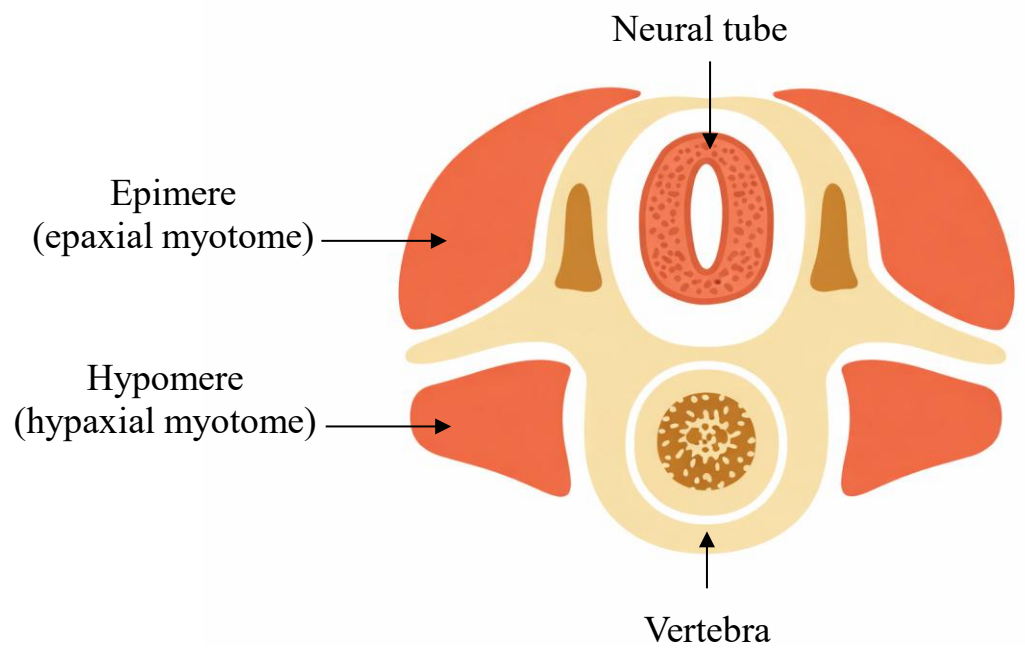
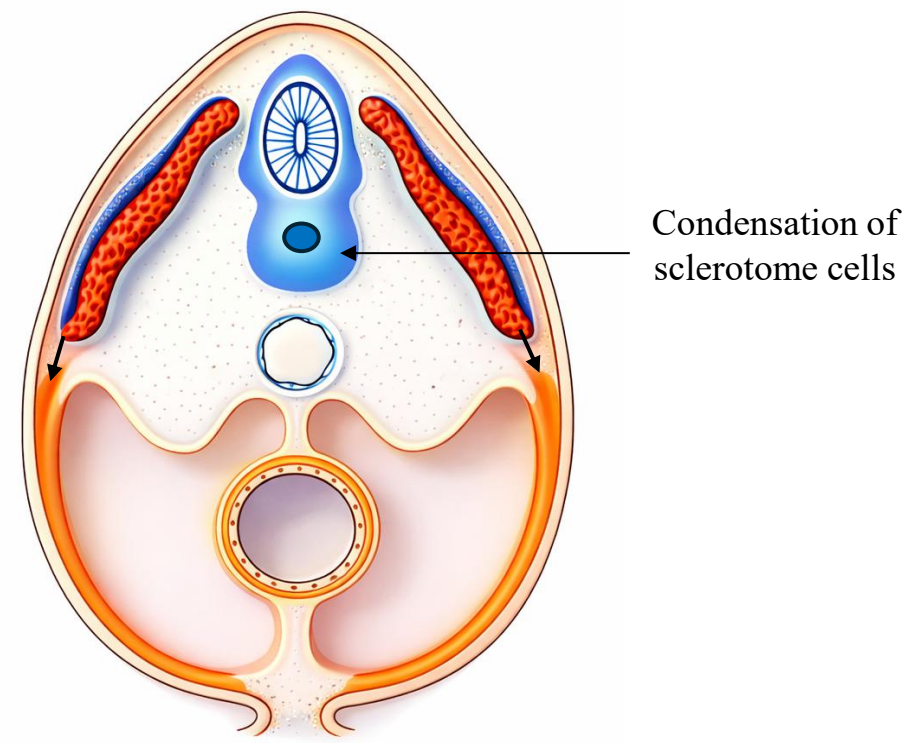
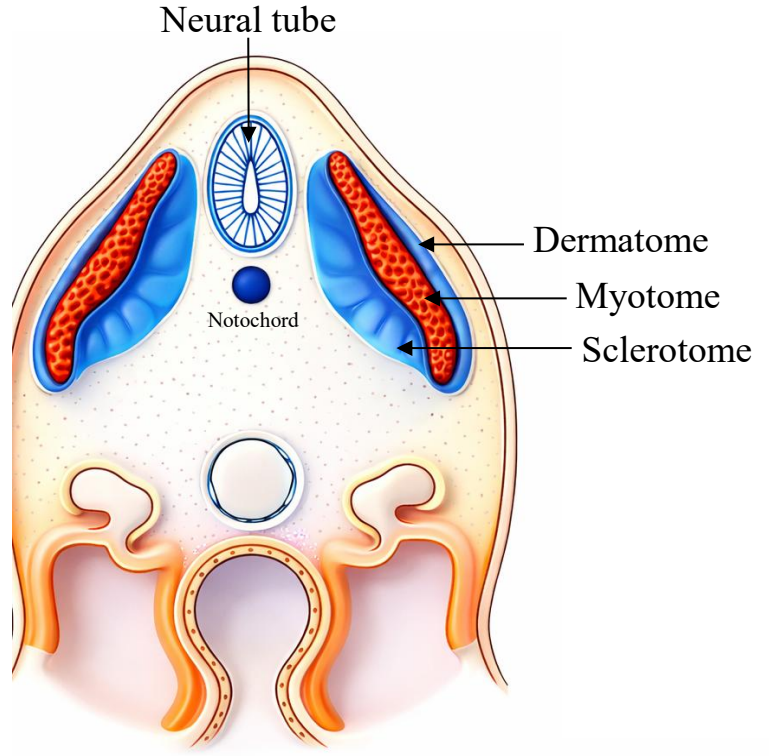
- Early embryos develop at slightly different speeds
- Somite number is more accurate than gestational age in days

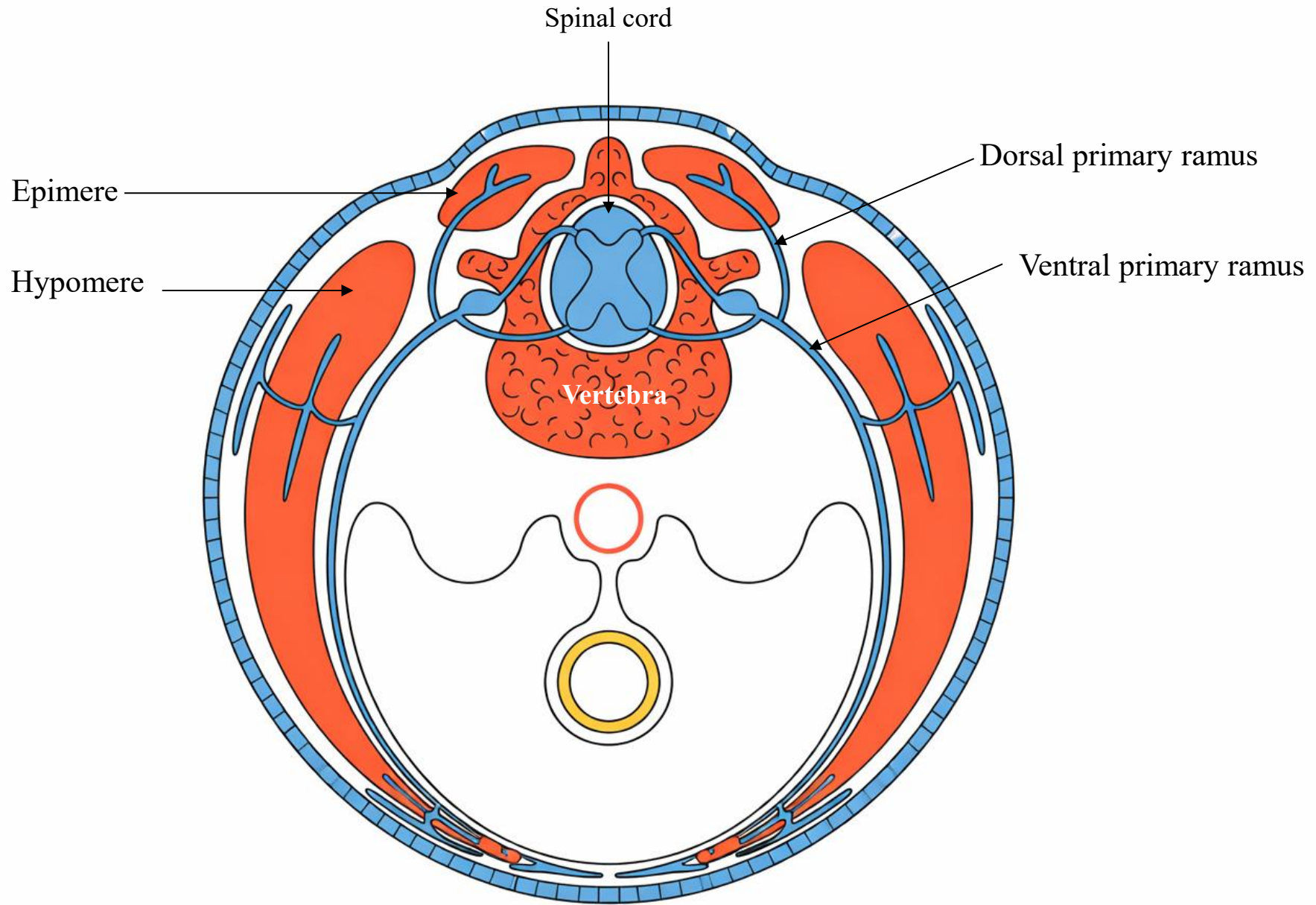
# Structure of Spinal Nerves: Somatic Pathways



# Structure of Spinal Nerves: Dorsal & Ventral Rami



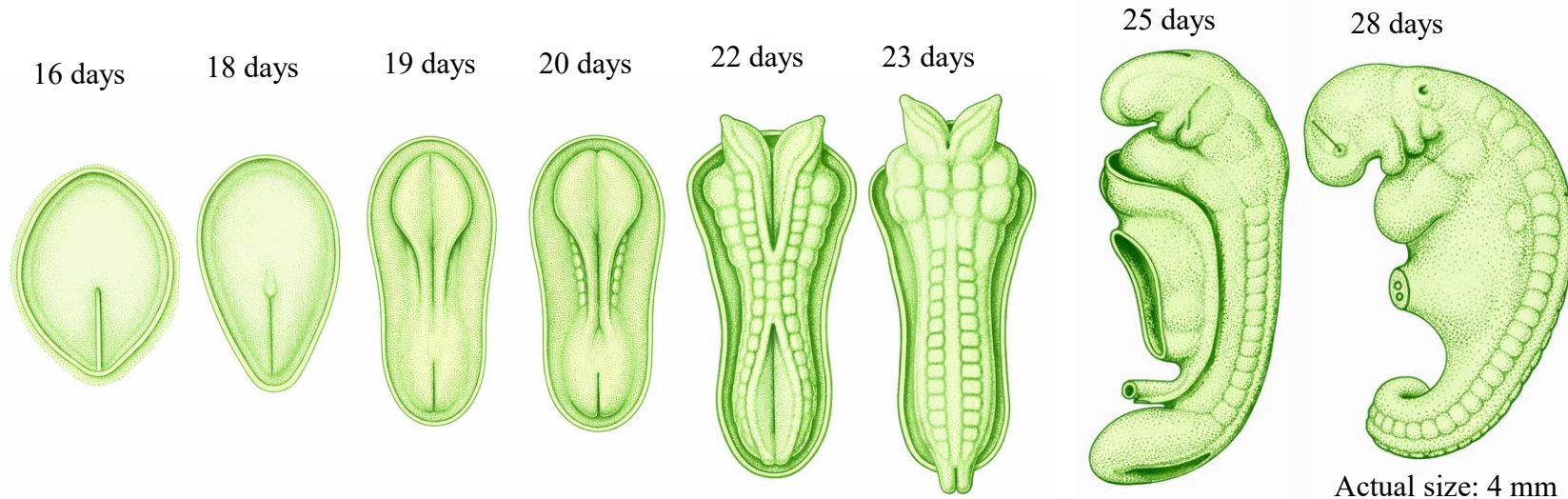




يَا أَيُّهَا النَّاسُ إِن كُنْتُمْ فِي رَيْبٍ مِّنَ الْبَعْثِ فَإِنَّا خَلَقْنَاكُمْ مِّن نُّرَابٍ ثُمَّ مِّن  
نُّطْفَةٍ ثُمَّ مِّن عَلَقَةٍ ثُمَّ مِّن مُّضْغَةٍ مُّخَلَّقَةٍ وَغَيْرِ مُخَلَّقَةٍ لِّنُبَيِّنَ لَكُمْ وَنُقِرُّ فِي  
الْأَرْحَامِ مَا نَشَاءُ إِلَىٰ أَجَلٍ مُّسَمًّى ثُمَّ نُخْرِجُكُمْ طِفْلًا ثُمَّ لِتَبْلُغُوا أَشُدَّكُمْ  
(سورة الحج: ٥)

During the embryonic period, some structures are clearly differentiated  
(organized somites and organ primordia), while others remain  
undifferentiated mesenchyme

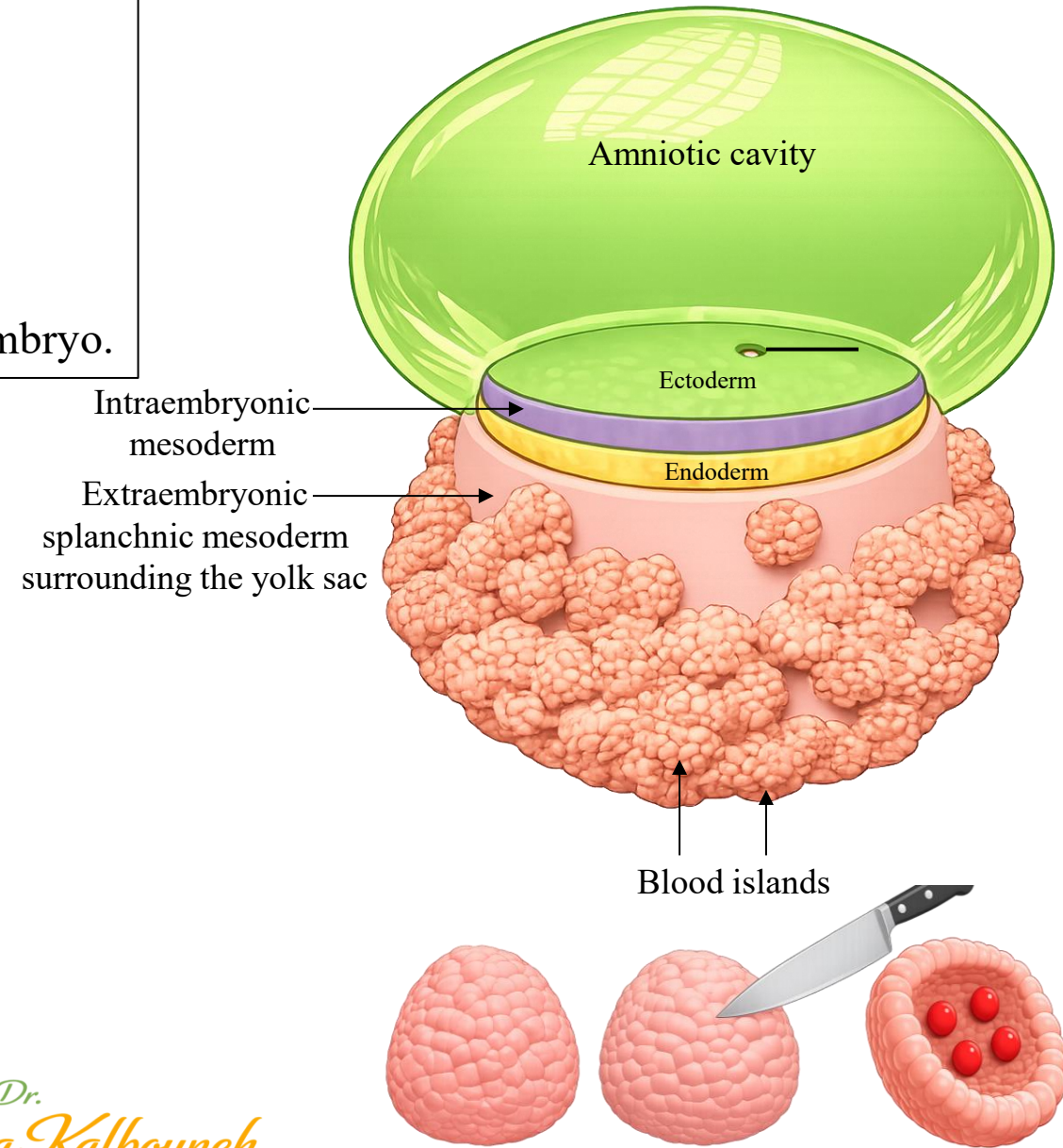
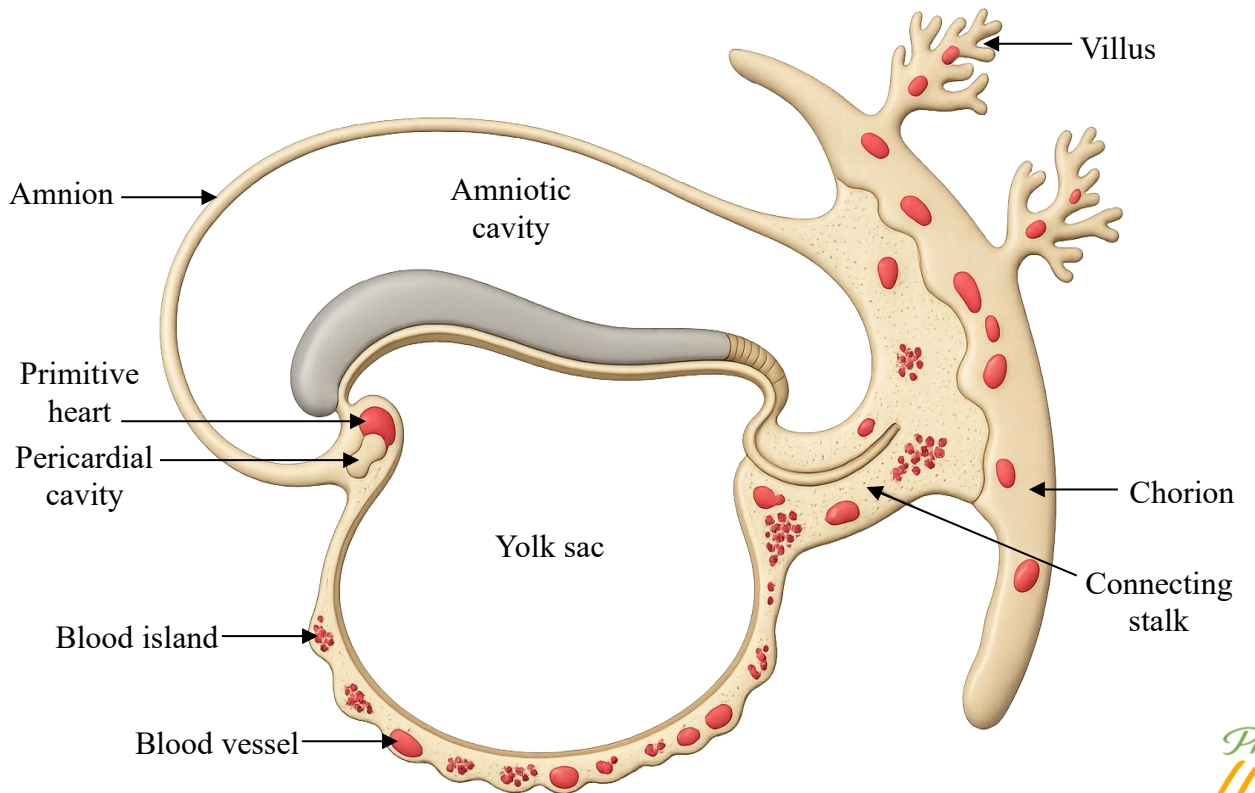
مخلقة وغير مخلقة

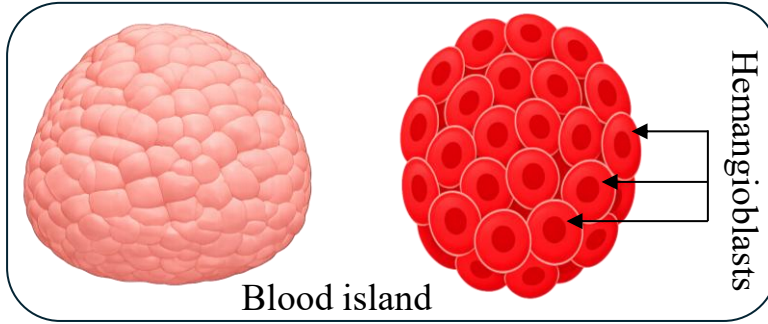
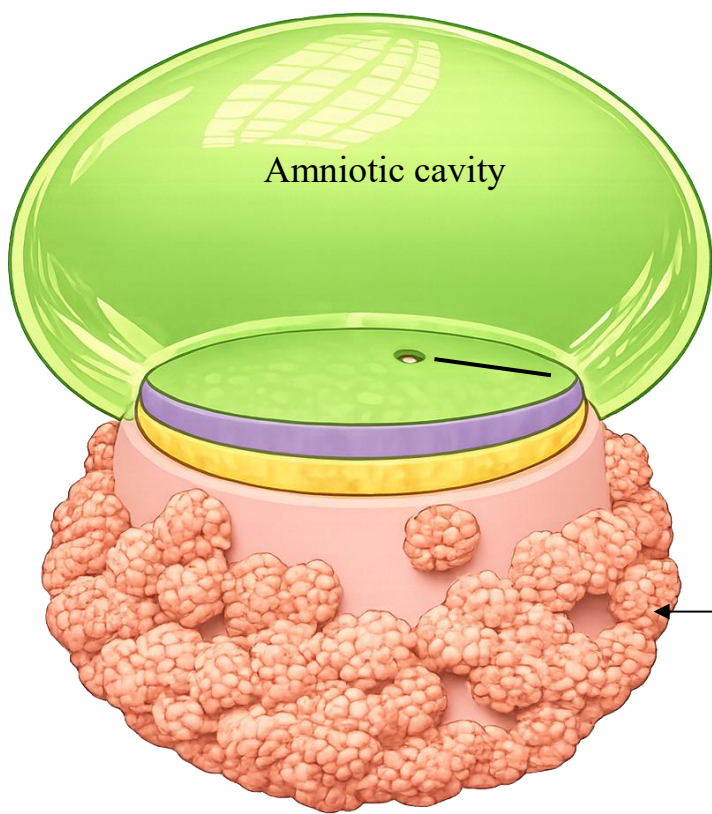


# Development of the Cardiovascular System

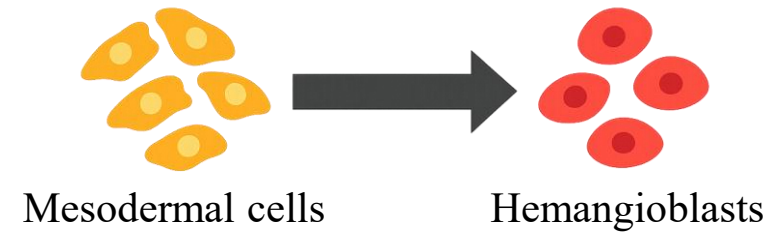
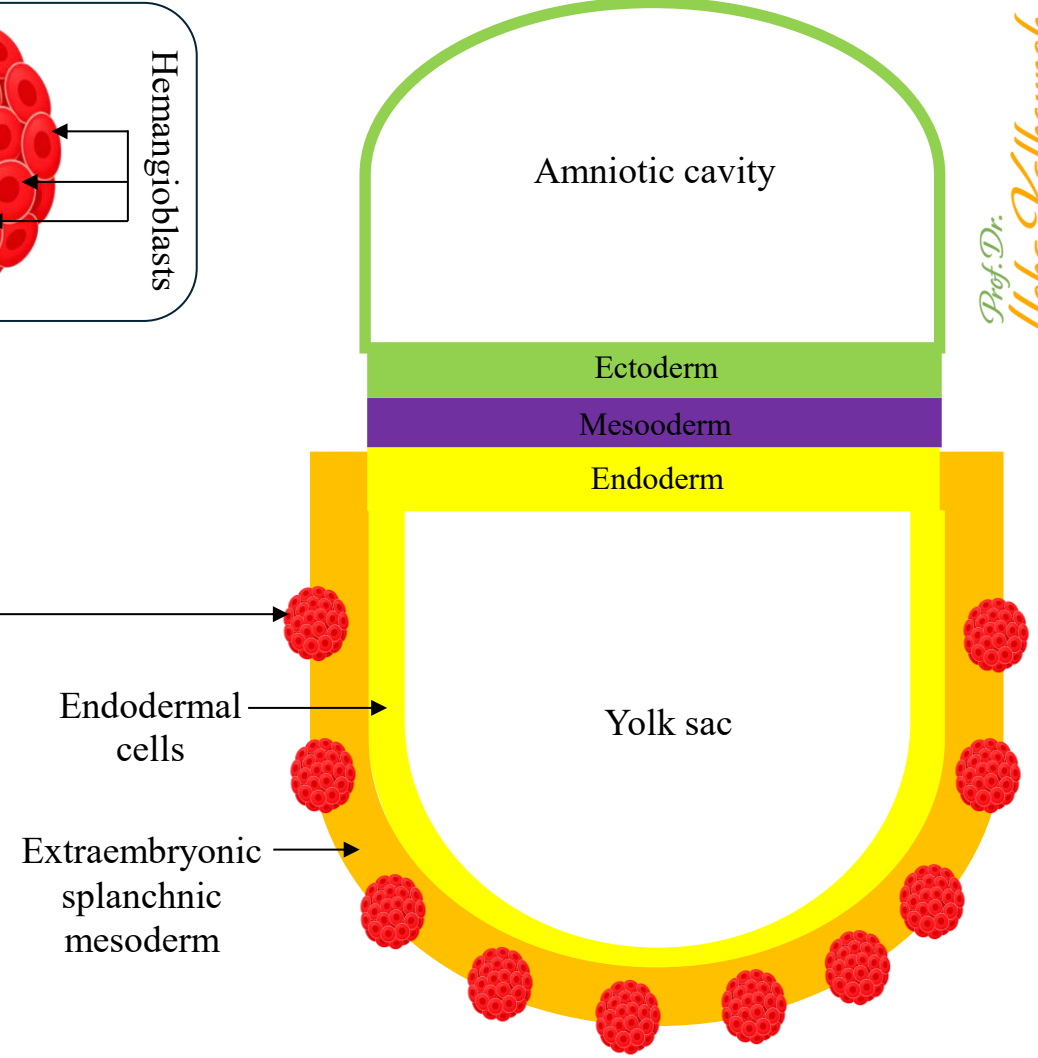
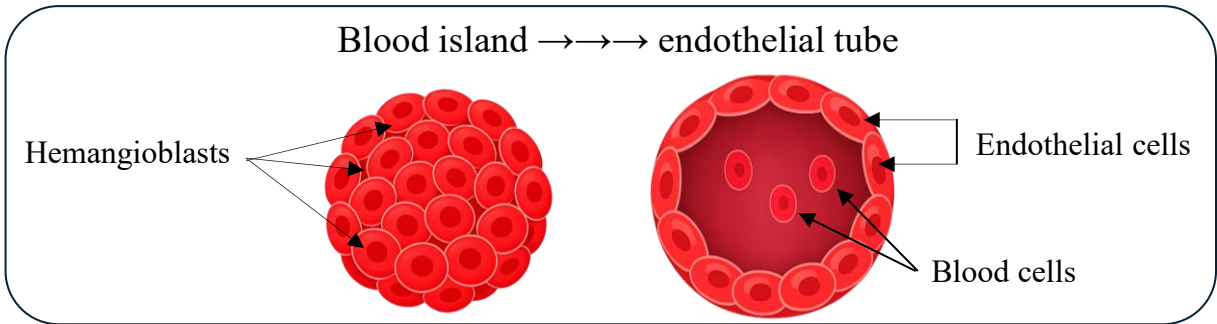
- ✓ Blood islands appear in:
  - Extraembryonic mesoderm (yolk sac wall, chorion)
  - Intraembryonic mesoderm
- ✓ These give rise to:
  - Blood cells
  - Endothelial cells
- ✓ The primitive heart tube begins to form by the end of week 3.
- ✓ The cardiovascular system is the first functional system in the embryo.

*Remember: The yolk sac wall consists of two layers:  
 1. Endodermal cells (inner lining of the yolk sac)  
 2. Extraembryonic splanchnic mesoderm (outer layer)*





- ✓ Mesodermal cells differentiate into hemangioblasts
- ✓ Hemangioblasts aggregate to form blood islands
- ✓ Cavities are formed inside blood island forming endothelial tube with:
  - Peripheral cells (angioblasts) → **endothelial cells**
  - Central cells (hemocytoblast) → **blood cells**

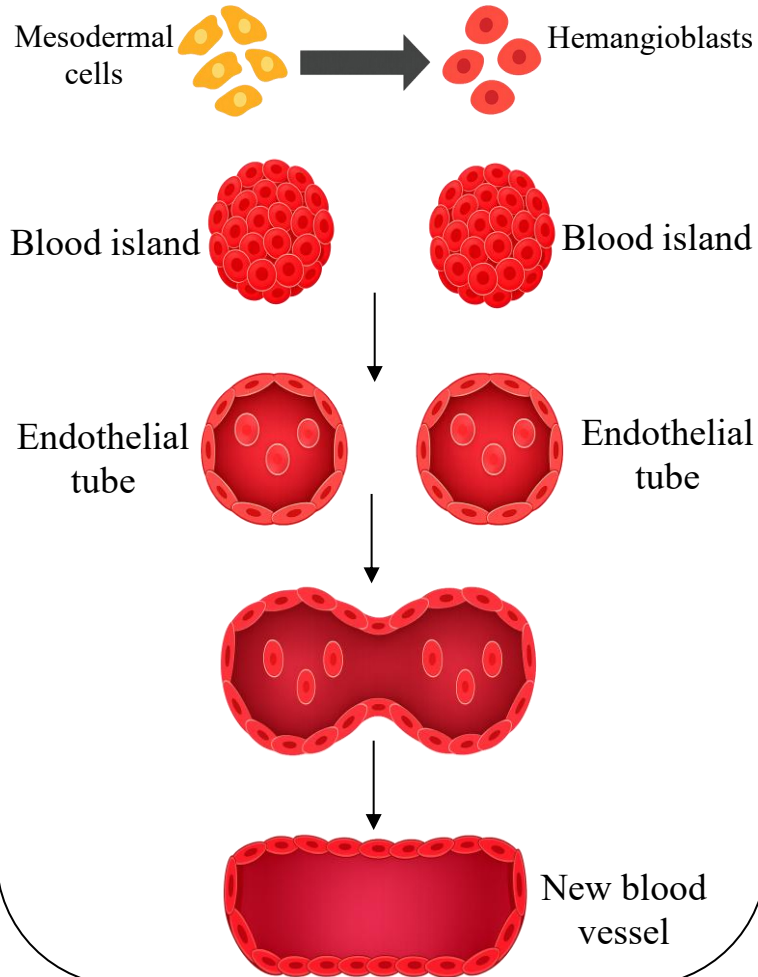


*Vasculogenesis* → starts the system

## Vasculogenesis

Formation of new blood vessels  
from mesodermal cells

*Vessels made from scratch*

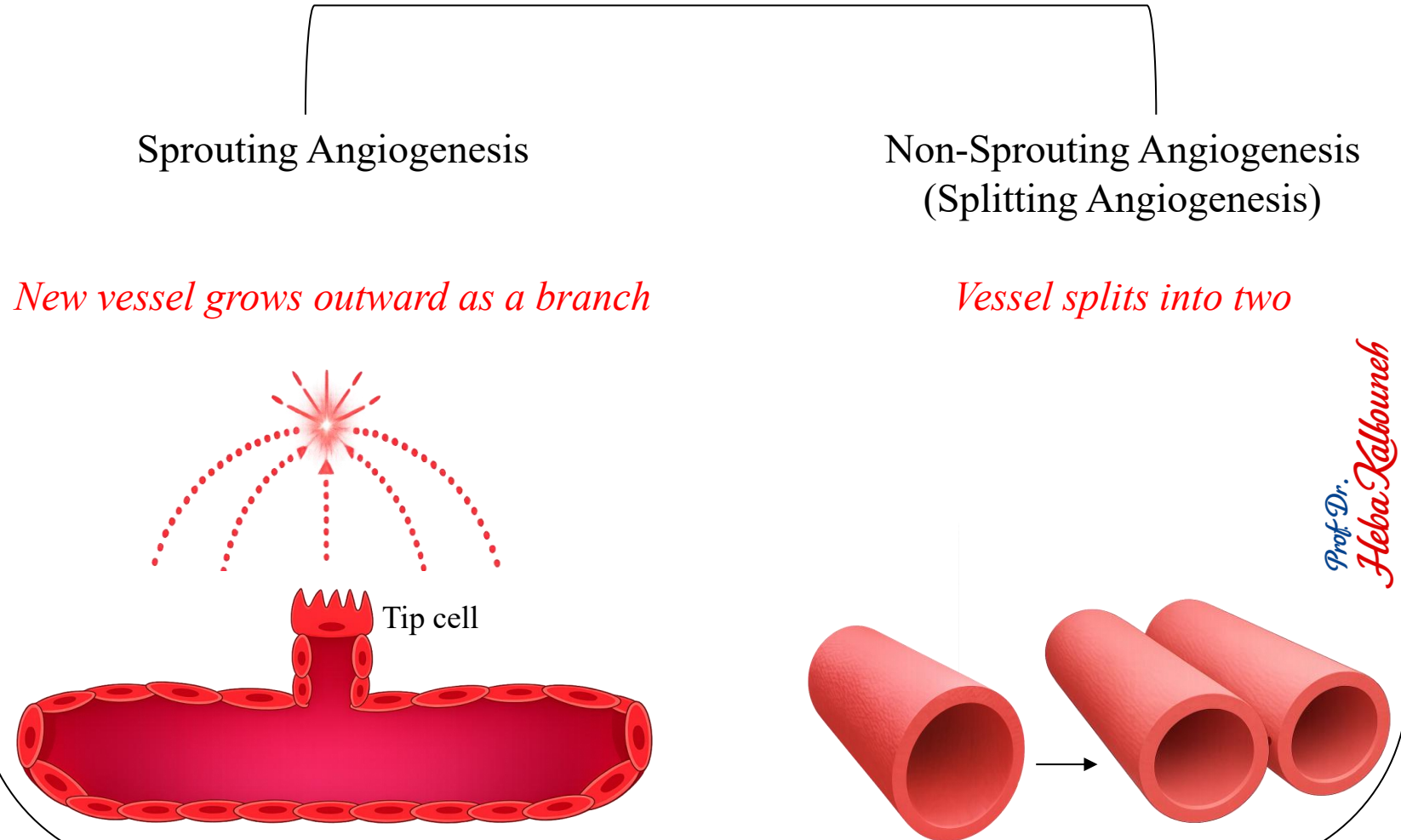


*Angiogenesis* → grows and reshapes it


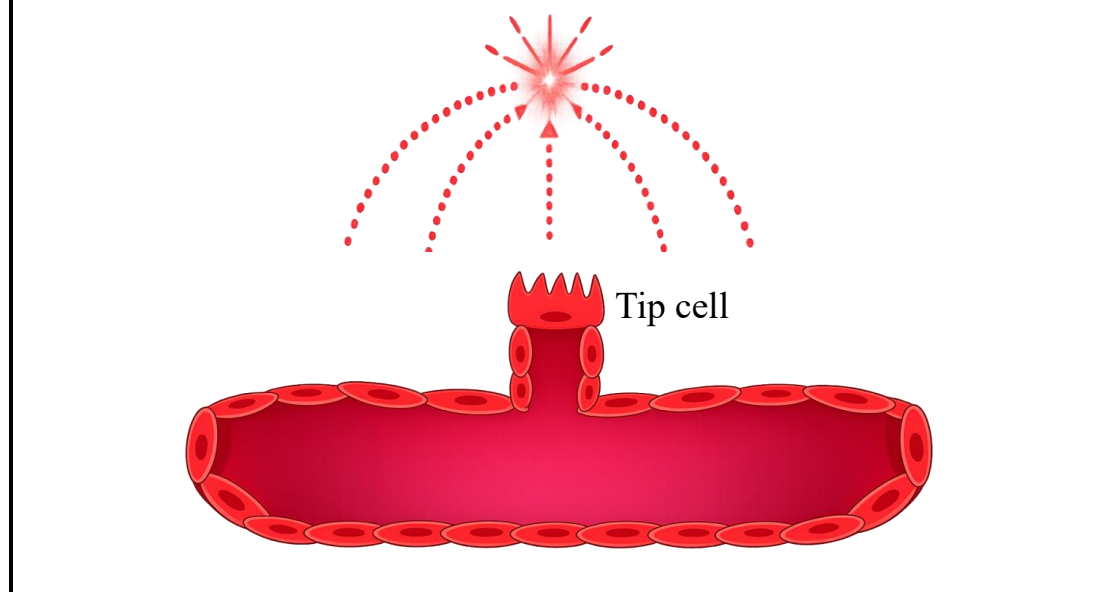
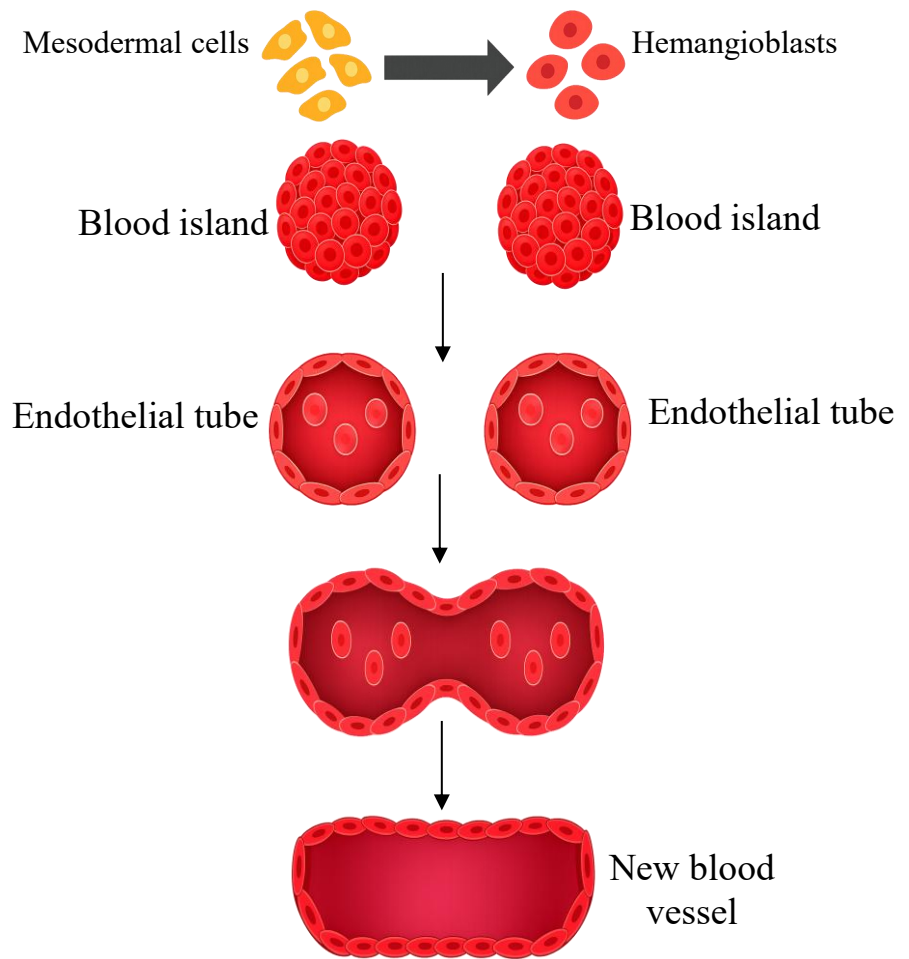
## Angiogenesis

Formation of new blood vessels from existing vessels

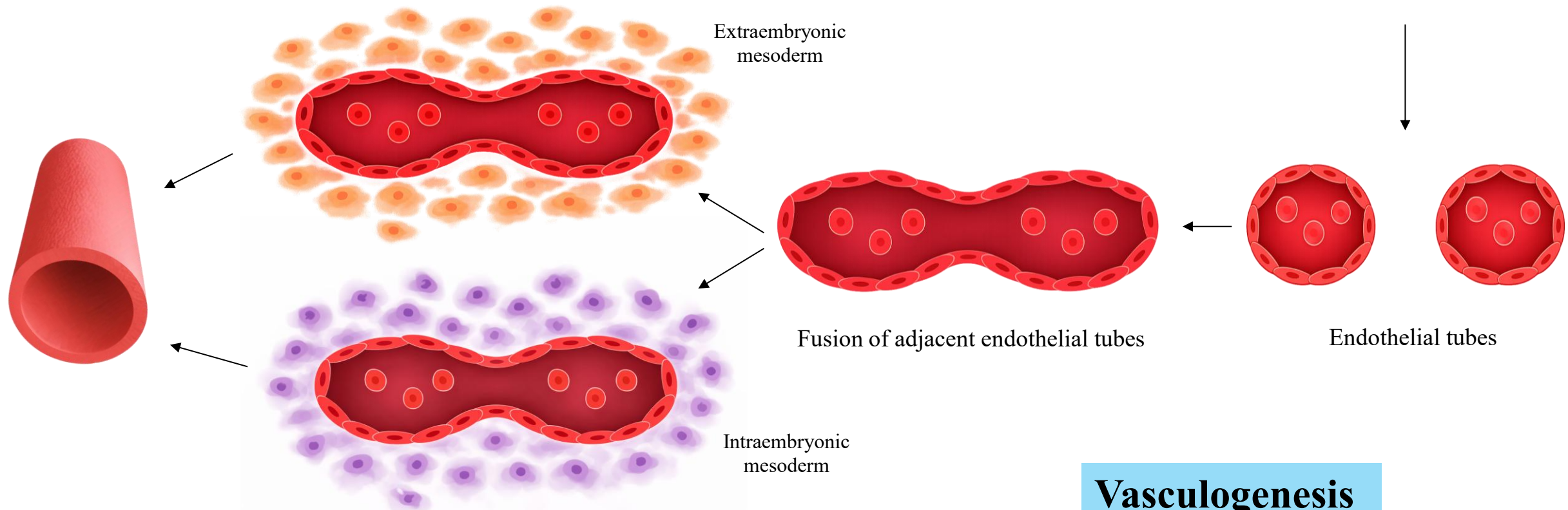
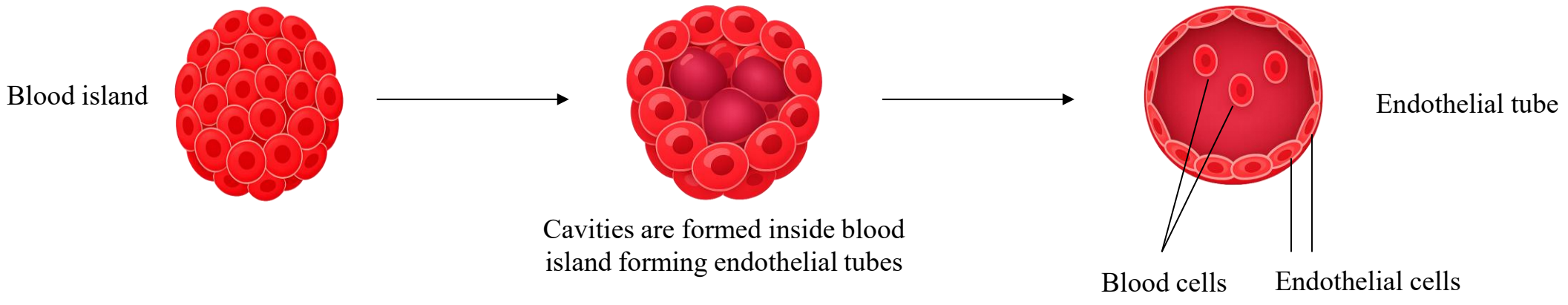
*Vessels made from vessels*



Feature	Vasculogenesis	Angiogenesis
Definition	Formation of new blood vessels from mesodermal cells	Formation of new blood vessels from existing vessels
Starting point	Mesodermal cells → hemangioblasts	Pre-existing vessels
Time	Early 3rd week of development	Late 3rd week onward
Main process	Formation of blood islands and endothelial tubes	Sprouting and splitting of existing vessels
Function	Establishes the first blood vessels	Expands and remodels the vascular network

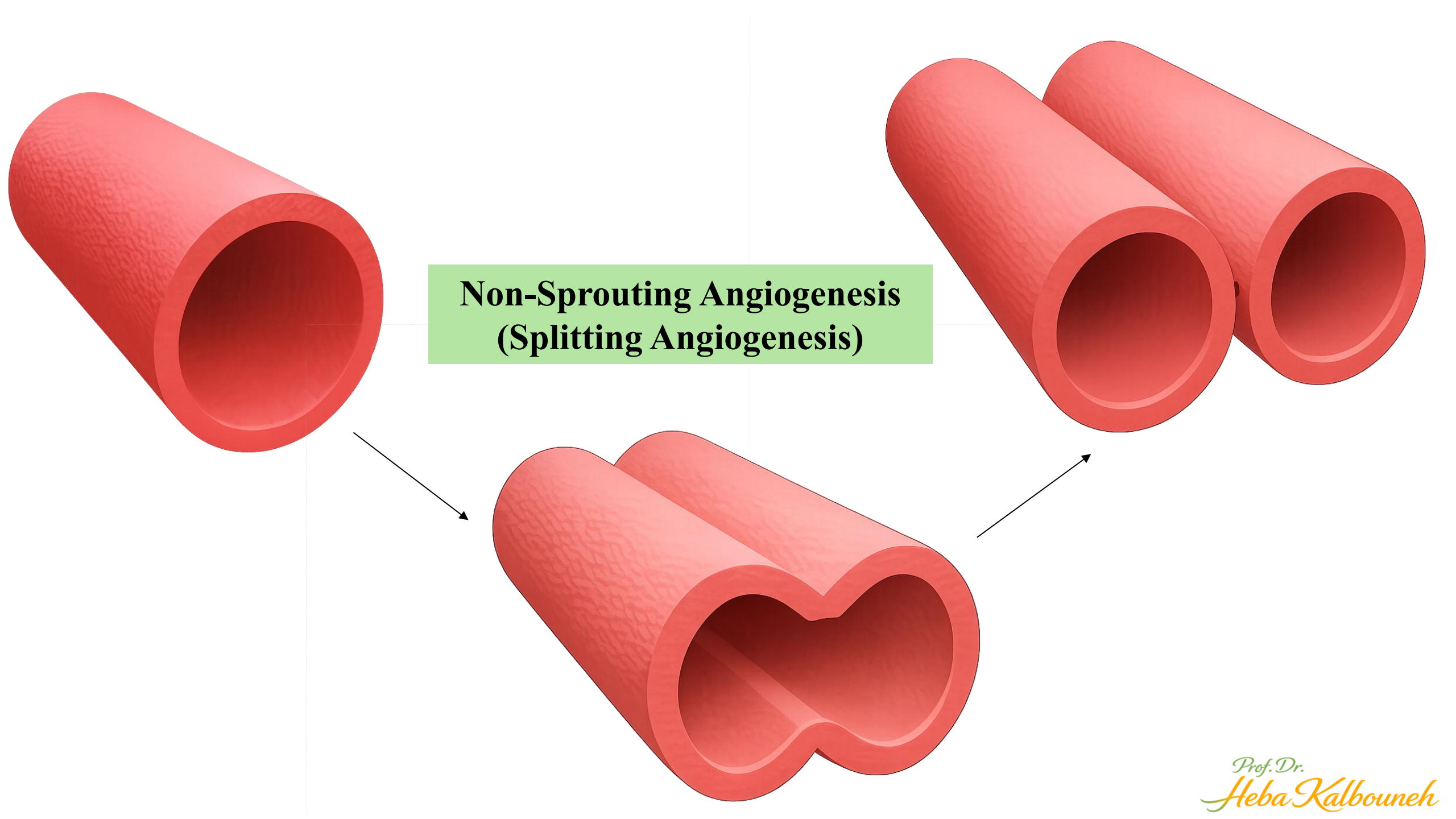


*Prof. Dr. Heba Kalbouneh*



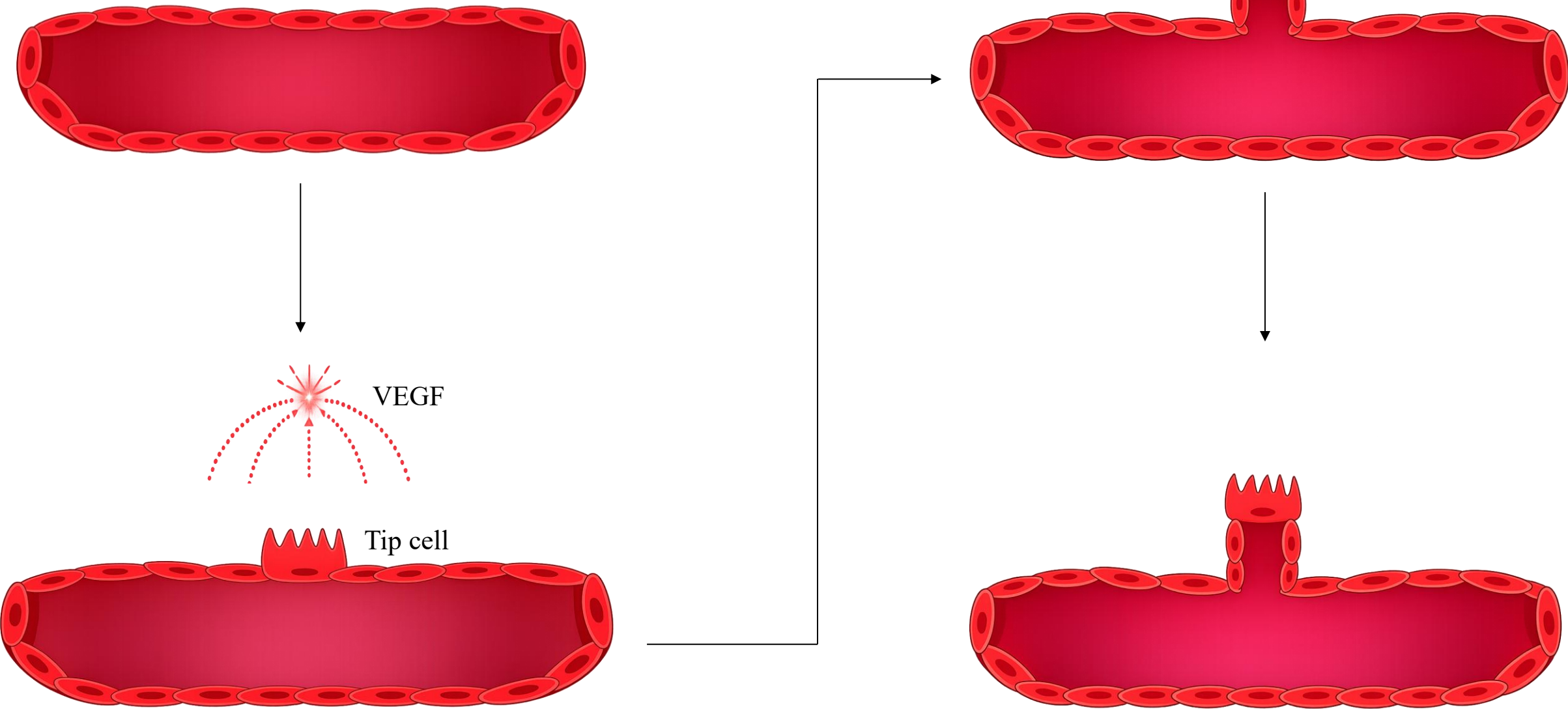
Surrounding mesoderm completes the vessel wall by differentiating into smooth muscle and connective tissue.

**Vasculogenesis**



**Non-Sprouting Angiogenesis  
(Splitting Angiogenesis)**

# Sprouting Angiogenesis

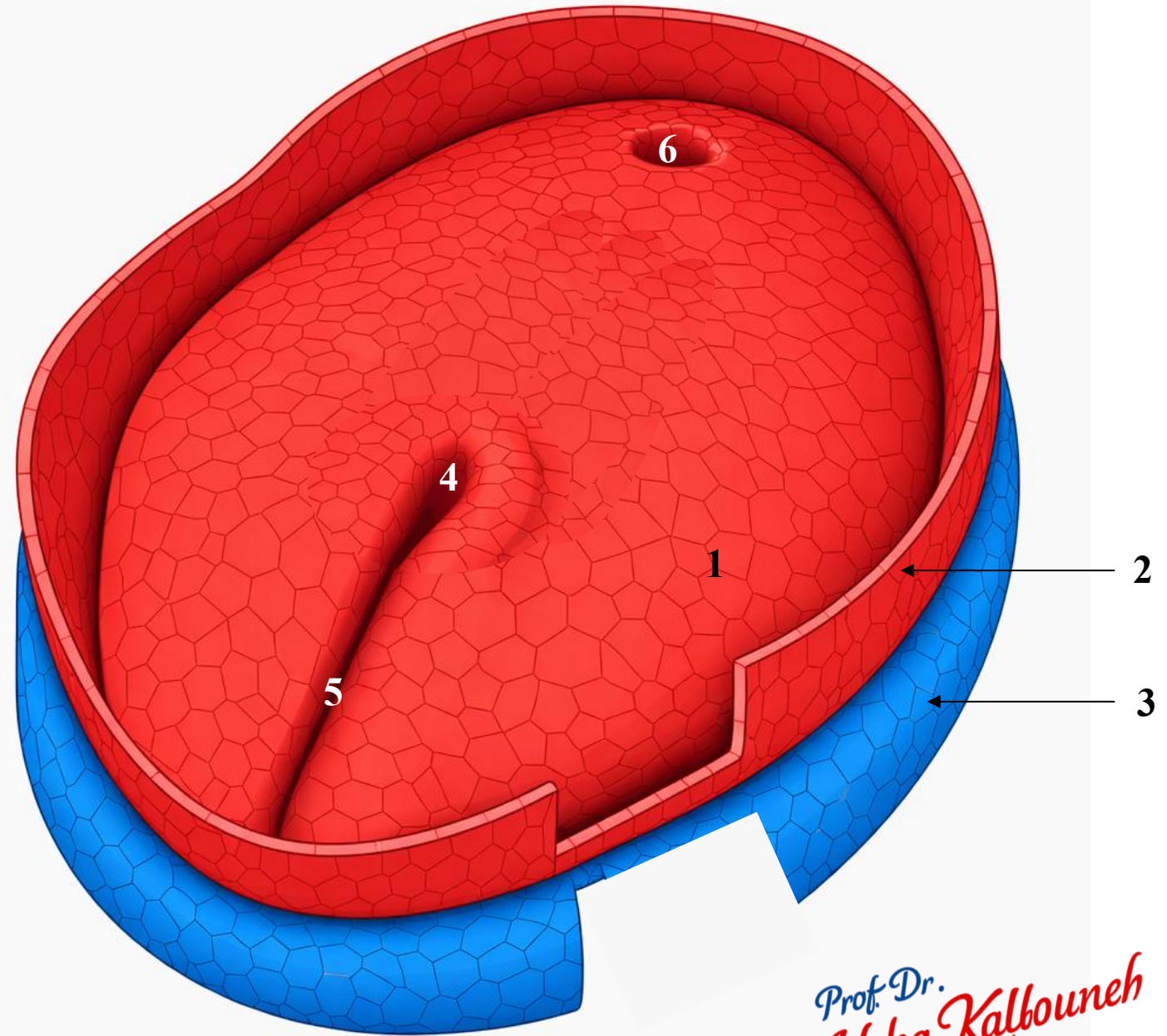


# Identify

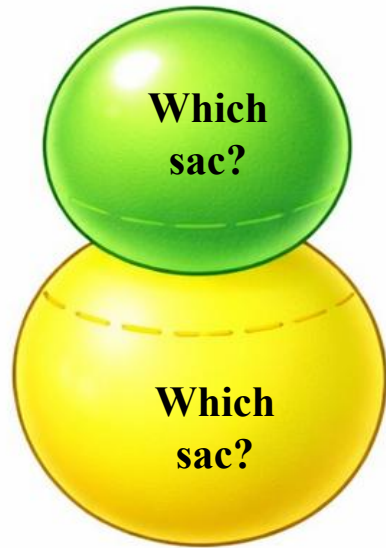
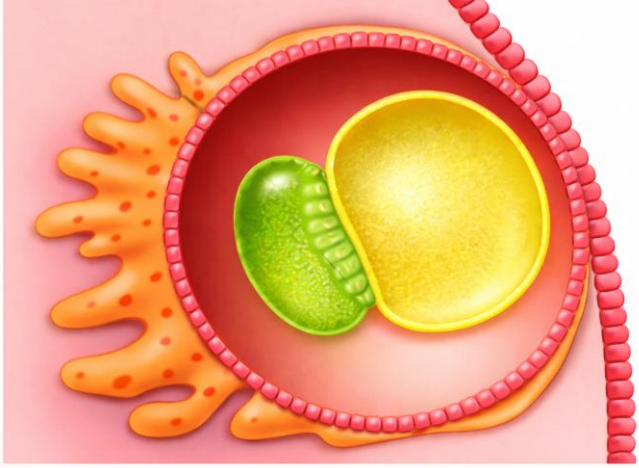
During which week of human development is this stage typically observed?

- A. First week
- B. Second week
- C. Third week
- D. Fourth week

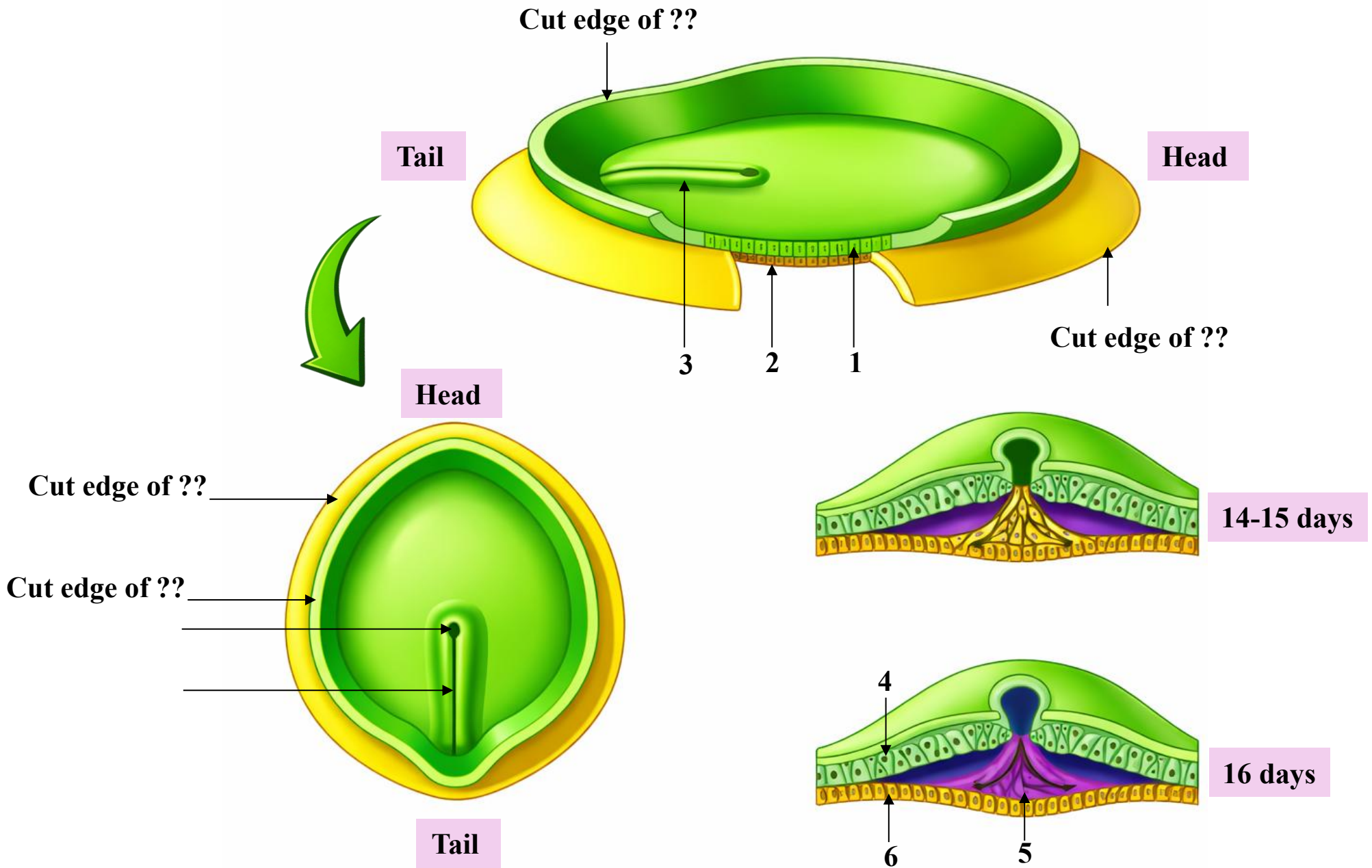
What major developmental event will transform this structure into the trilaminar disc?



Prof. Dr.  
*Heba Kalbouneh*

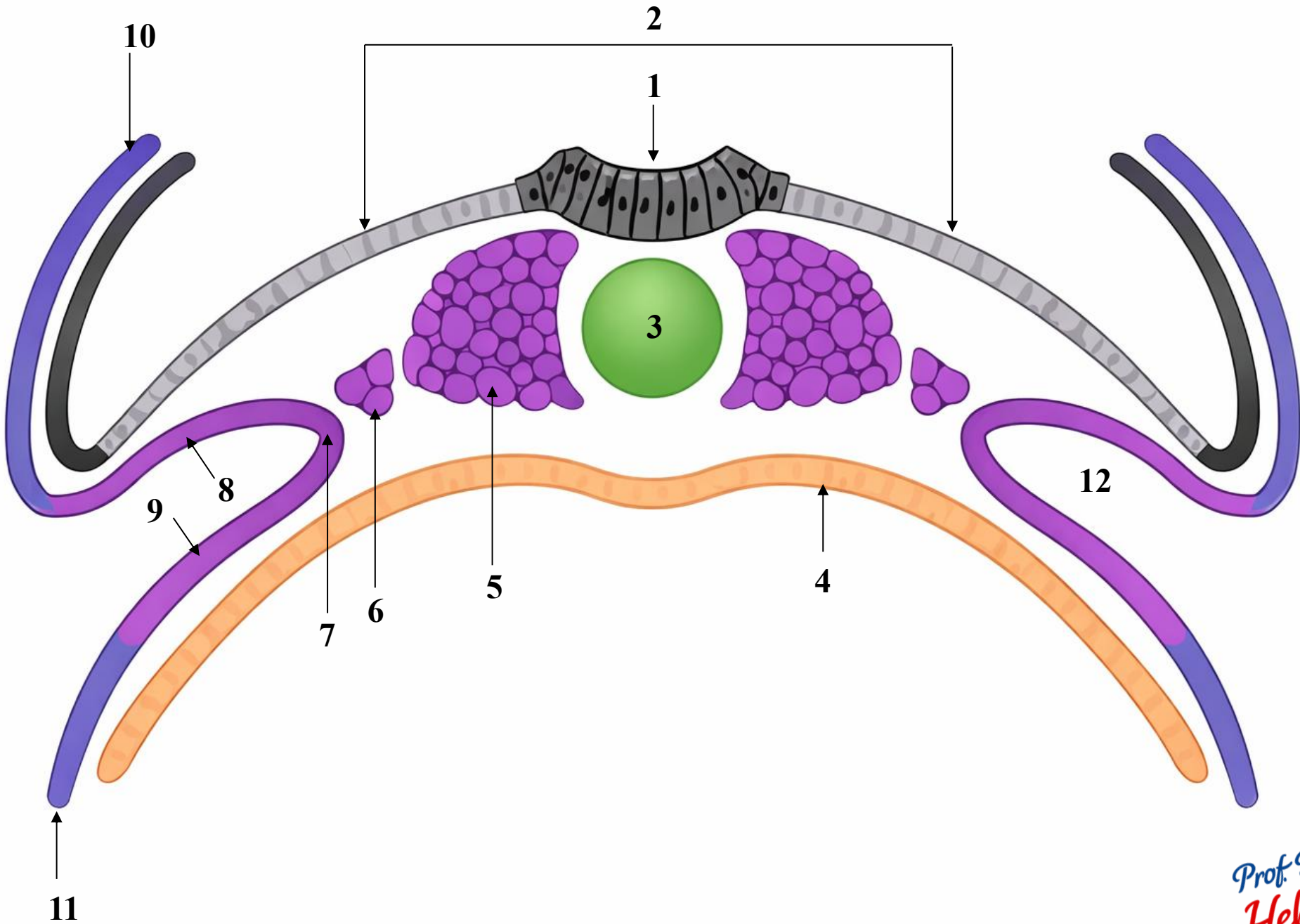


**Bilaminar  
embryonic  
disc**



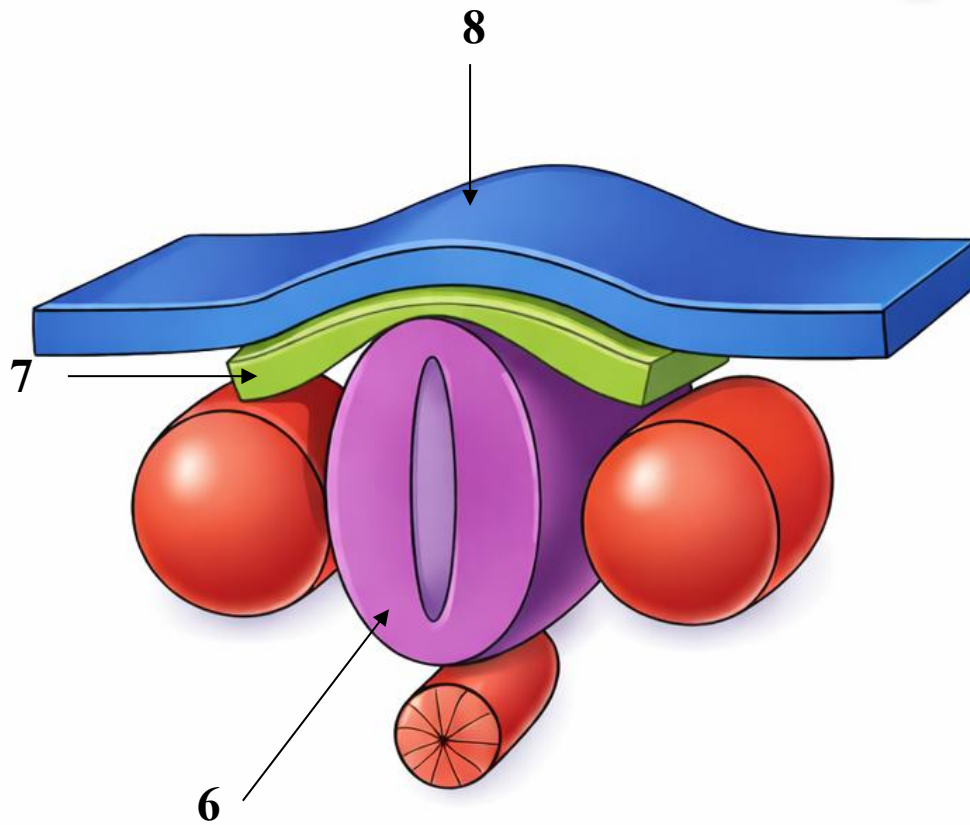
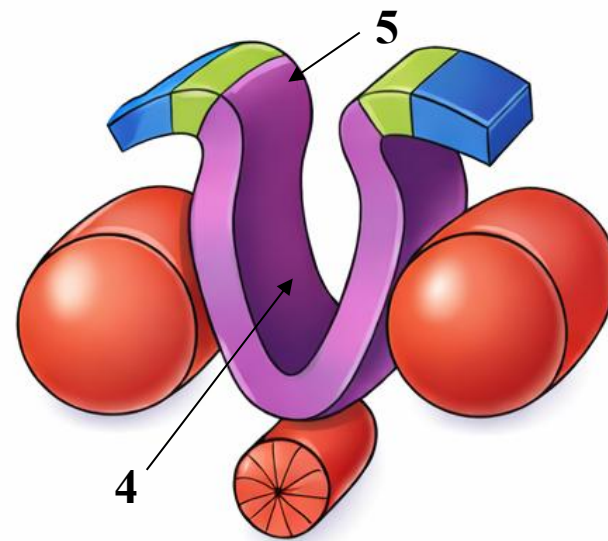
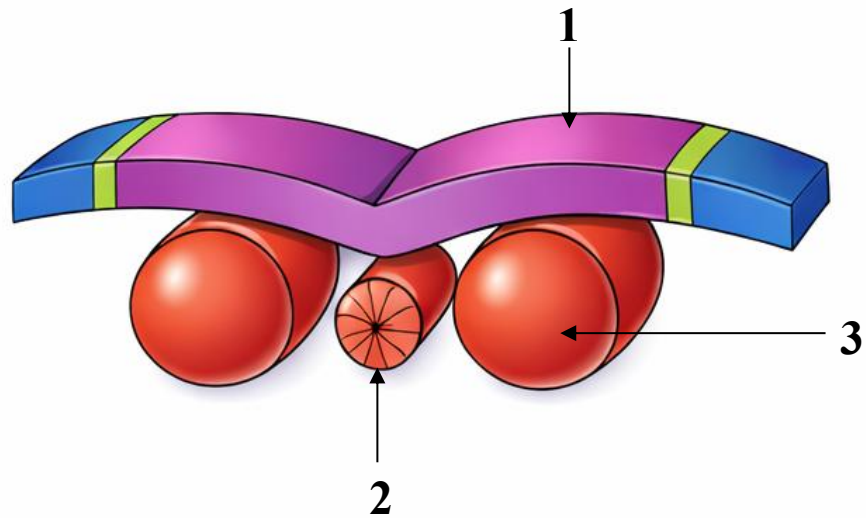
Bilaminar embryonic disc, superior view

**Identify**

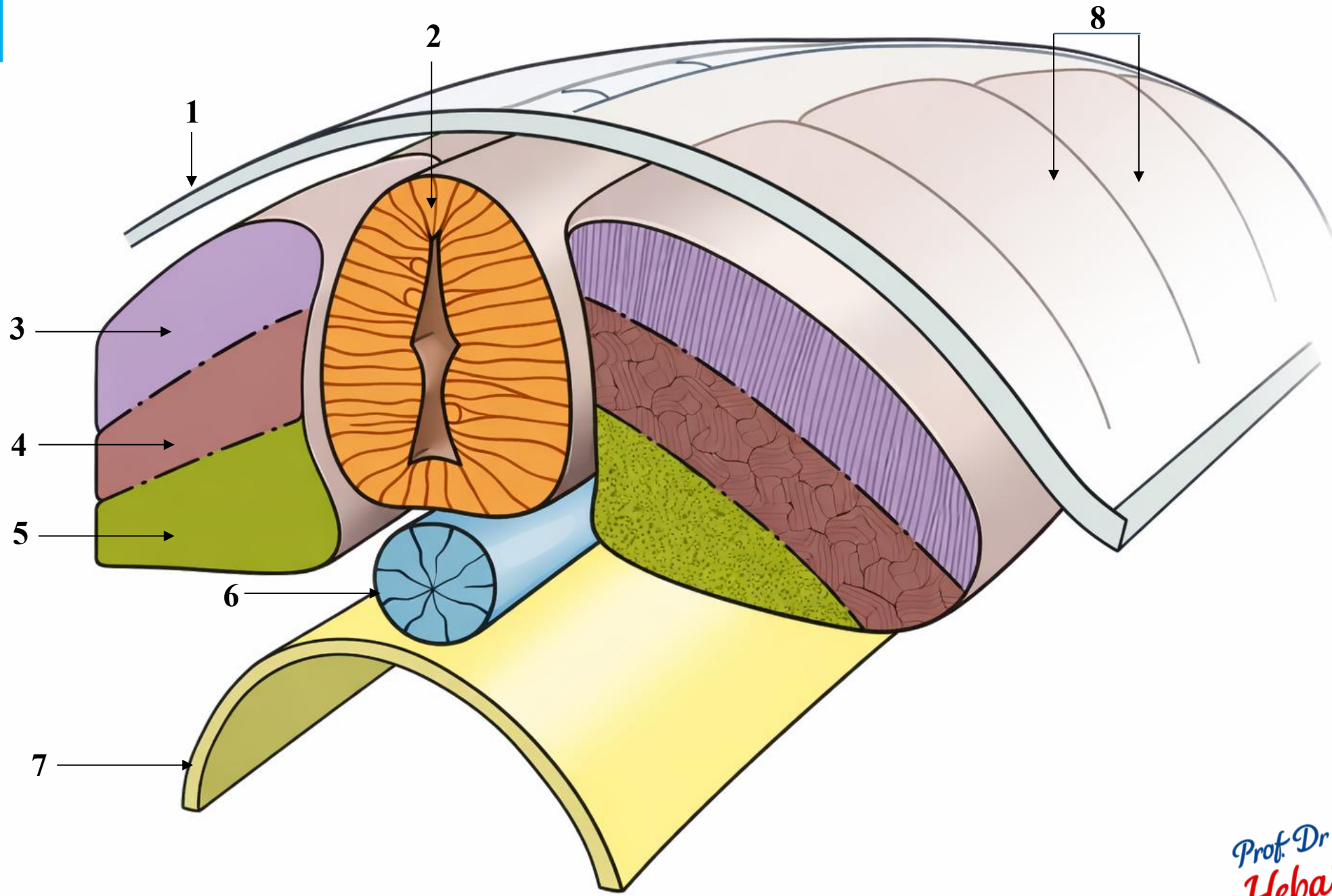


Prof. Dr.  
*Heba Kalbouneh*

# Identify



**Identify**



Prof. Dr.  
*Heba Kalbouneh*

## Clinical Application

1. The third week of development is a critical and sensitive period in embryonic development.
2. Exposure of the mother to harmful factors such as certain drugs, alcohol, or radiation during this time may lead to congenital abnormalities in the embryo.
3. Normally, the primitive streak regresses and disappears by the end of the fourth week. If remnants persist in the sacrococcygeal region, their pluripotent cells may proliferate and form tumors called sacrococcygeal teratomas.

