



# **Introduction to Anatomy**

## **Practical Lab**

**1<sup>st</sup> year Medical Students**

**2025-2026**

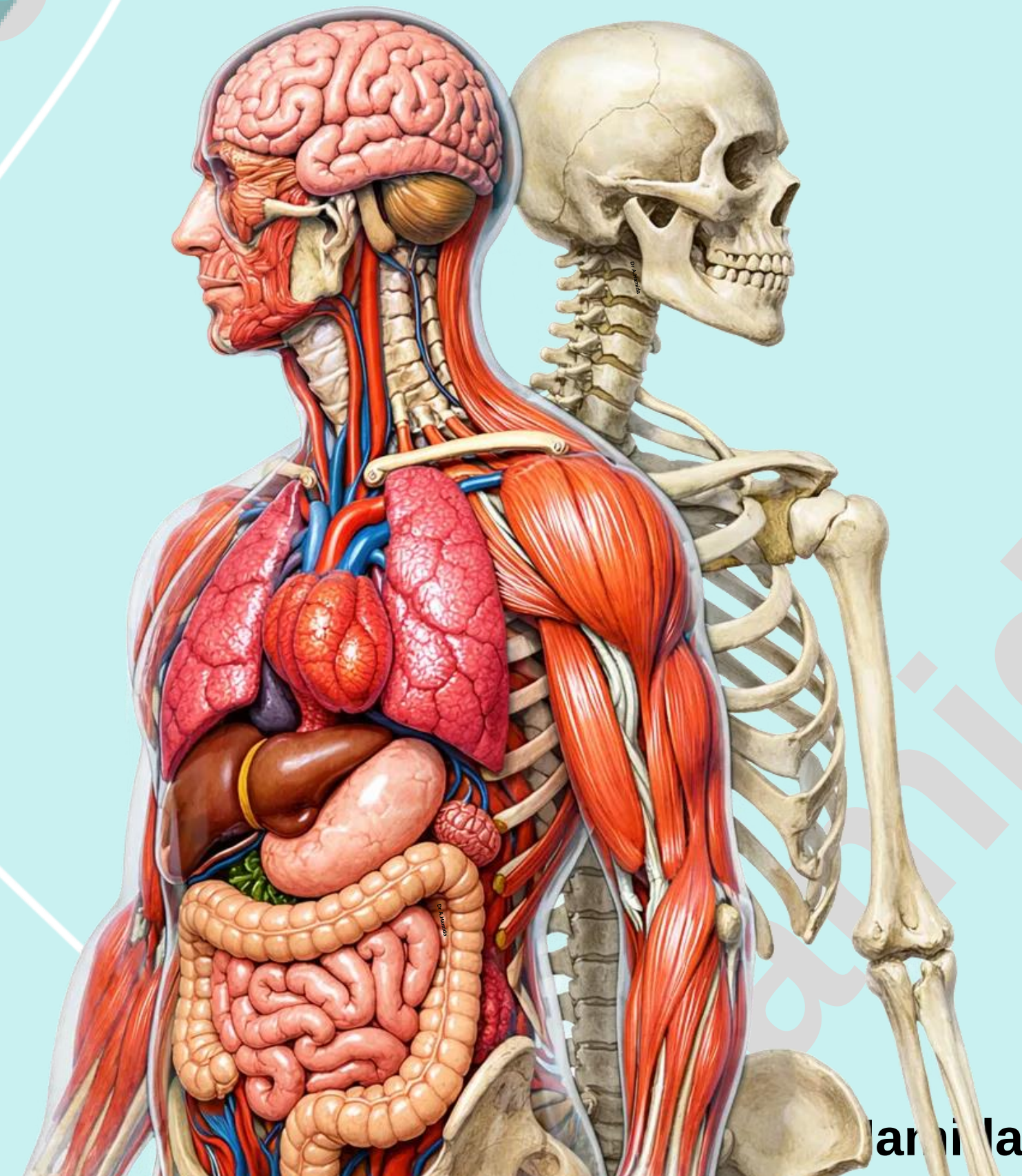
**Second Semester**

**Dr. Abedallah Hamida, MBBS, PhD**

**Department of Anatomy and Histology**

**School of Medicine-The University of Jordan**

**[a\\_hamida@ju.edu.jo](mailto:a_hamida@ju.edu.jo)**



Hamida

# **Practical Lab-9**

## **Skeletal Muscles-1**

- 1. Muscles of the Head**
- 2. Muscles of the Neck**
- 3. Muscles of the Trunk**

# Check List: Skeletal Muscles-1

Practical Lab-9

## 1. Muscles of the Head

- ✓ Identify the location, origin, insertion and action of the following muscles:

### Muscles of the Facial Expression

1. Frontalis muscle
2. Orbicularis Oculi
3. Orbicularis Oris
4. Buccinator

### Muscles of the Mastication

1. Masseter
2. Temporalis
3. Lateral pterygoid
4. Medial pterygoid

## 2. Muscles of the Neck

- ✓ Identify the location, origin, insertion and action of the following muscles:

1. Sternocleidomastoid

# **Check List: Skeletal Muscles-1**

*Practical Lab-9*

## **3. Muscles of the Trunk**

- ✓ Identify the location, origin, insertion and action of the following muscles:

### Muscles of the Thoracic wall

1. Pectoralis major
2. Trapezius
3. Intercostal muscles: External intercostal muscle, Internal intercostal muscle, and Innermost intercostal muscle.
4. Diaphragm

### Muscles of the Anterior Abdominal wall

1. External oblique
2. Internal oblique
3. Transversus Abdominis
4. Rectus Abdominis

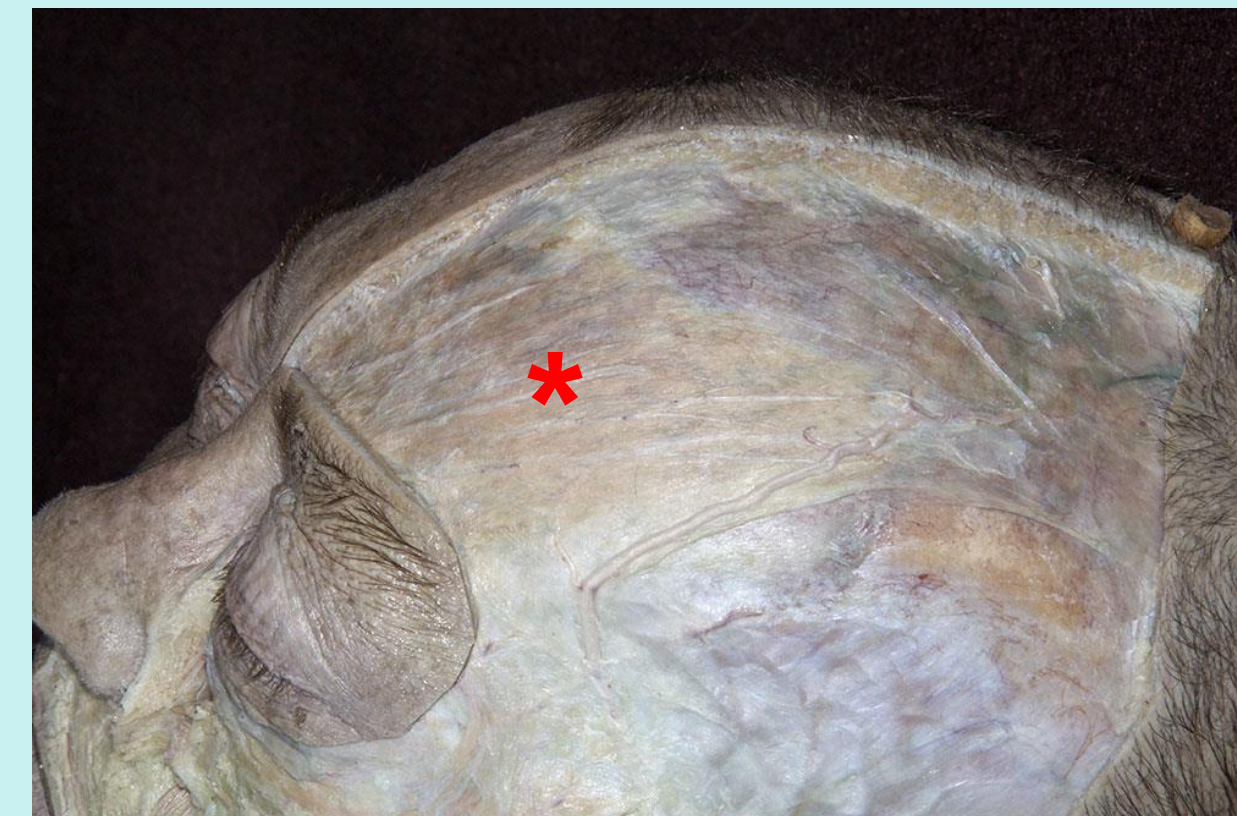
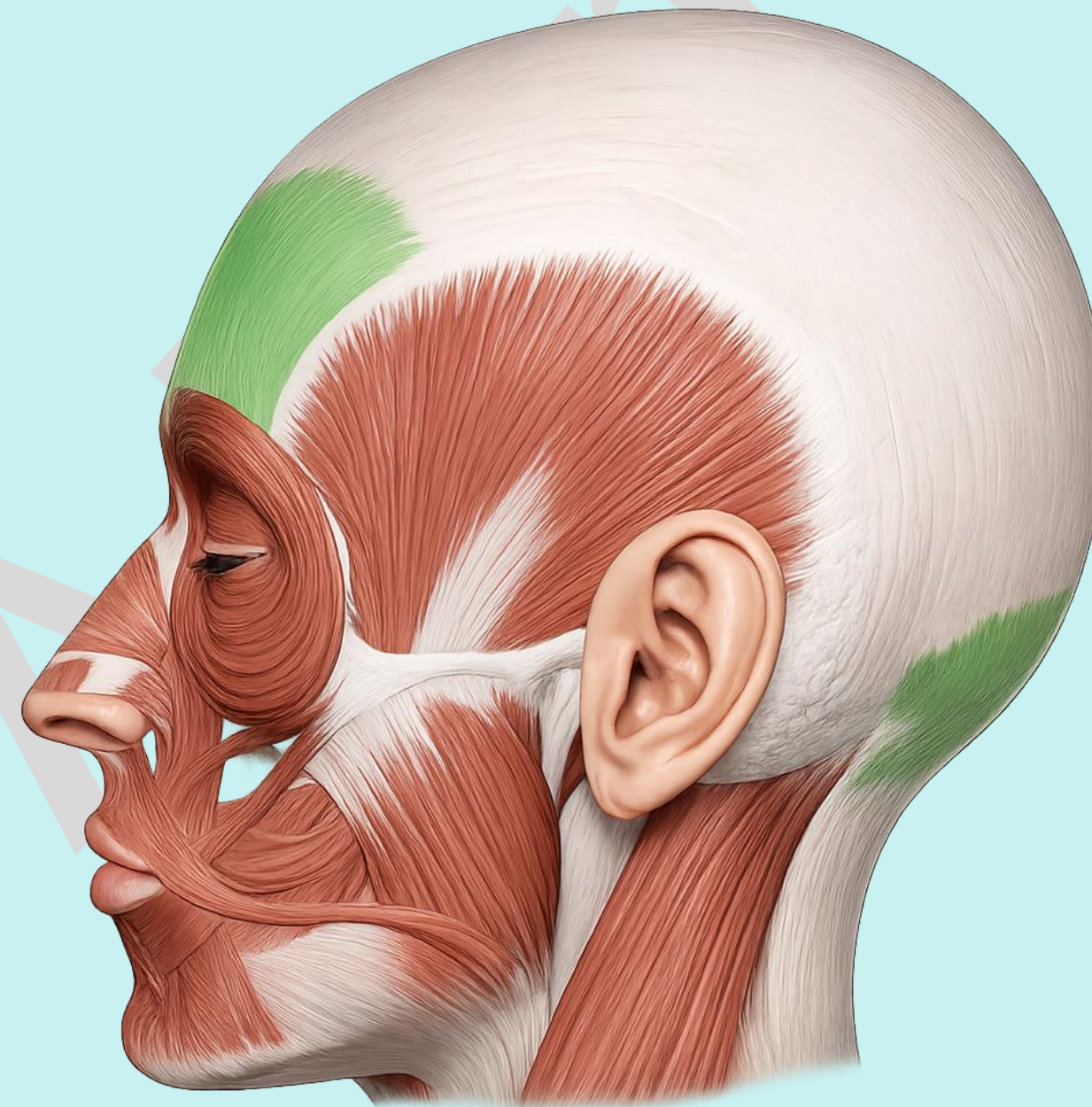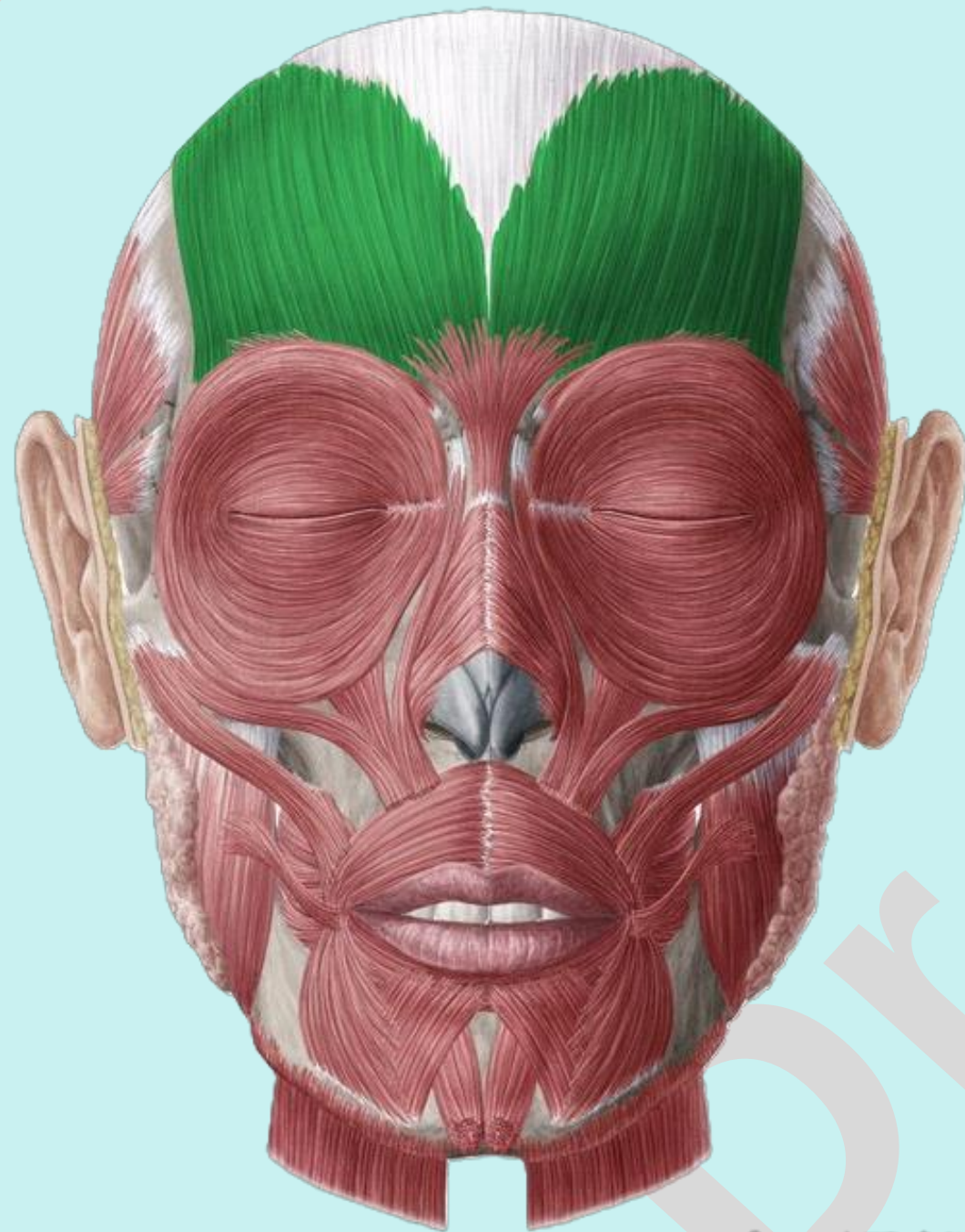### Diaphragm

# Check List:

## Muscles of the Head

### Muscles of the Facial Expression:

1. **Frontalis muscle:** identify the location, origin, insertion and action.

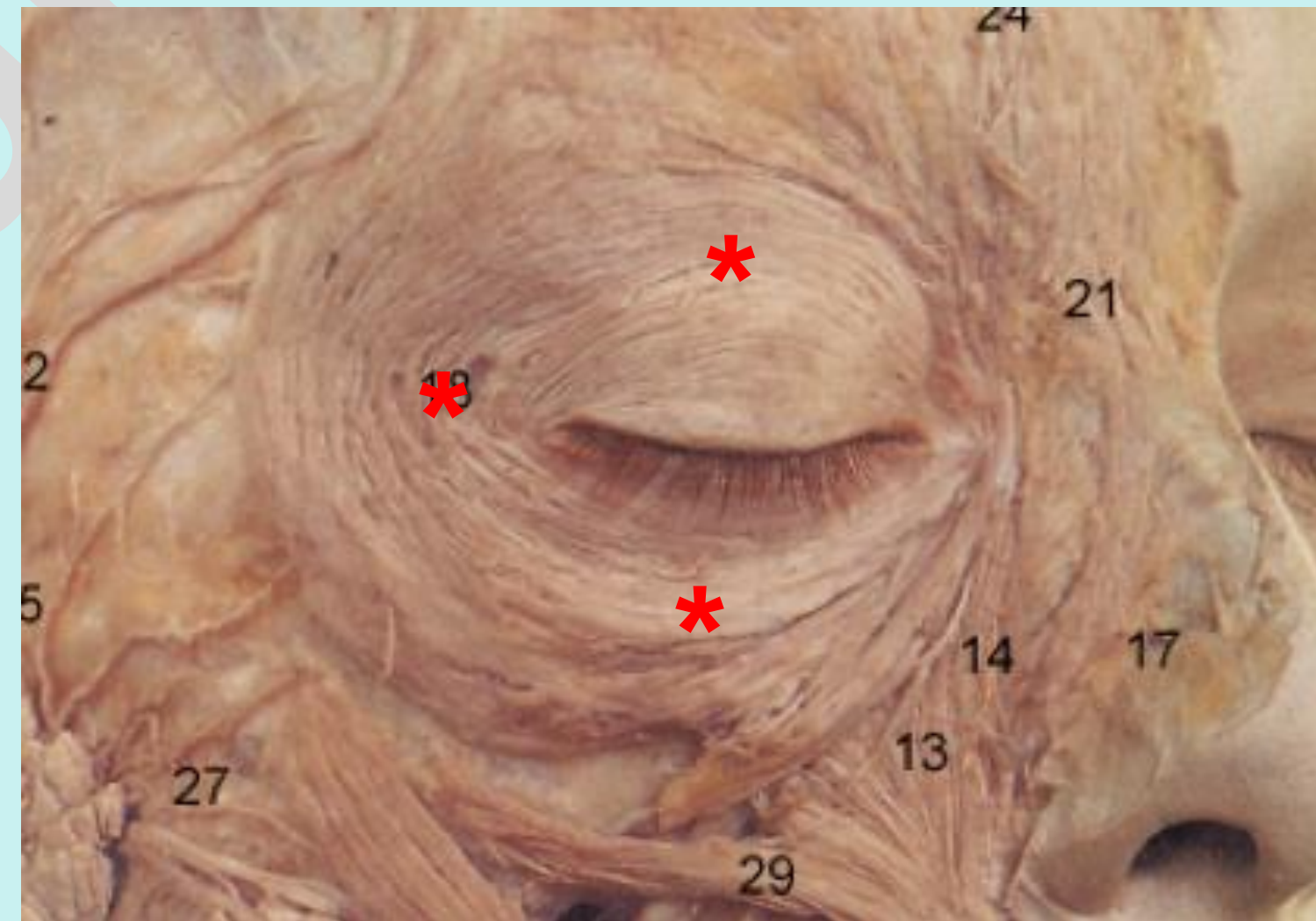
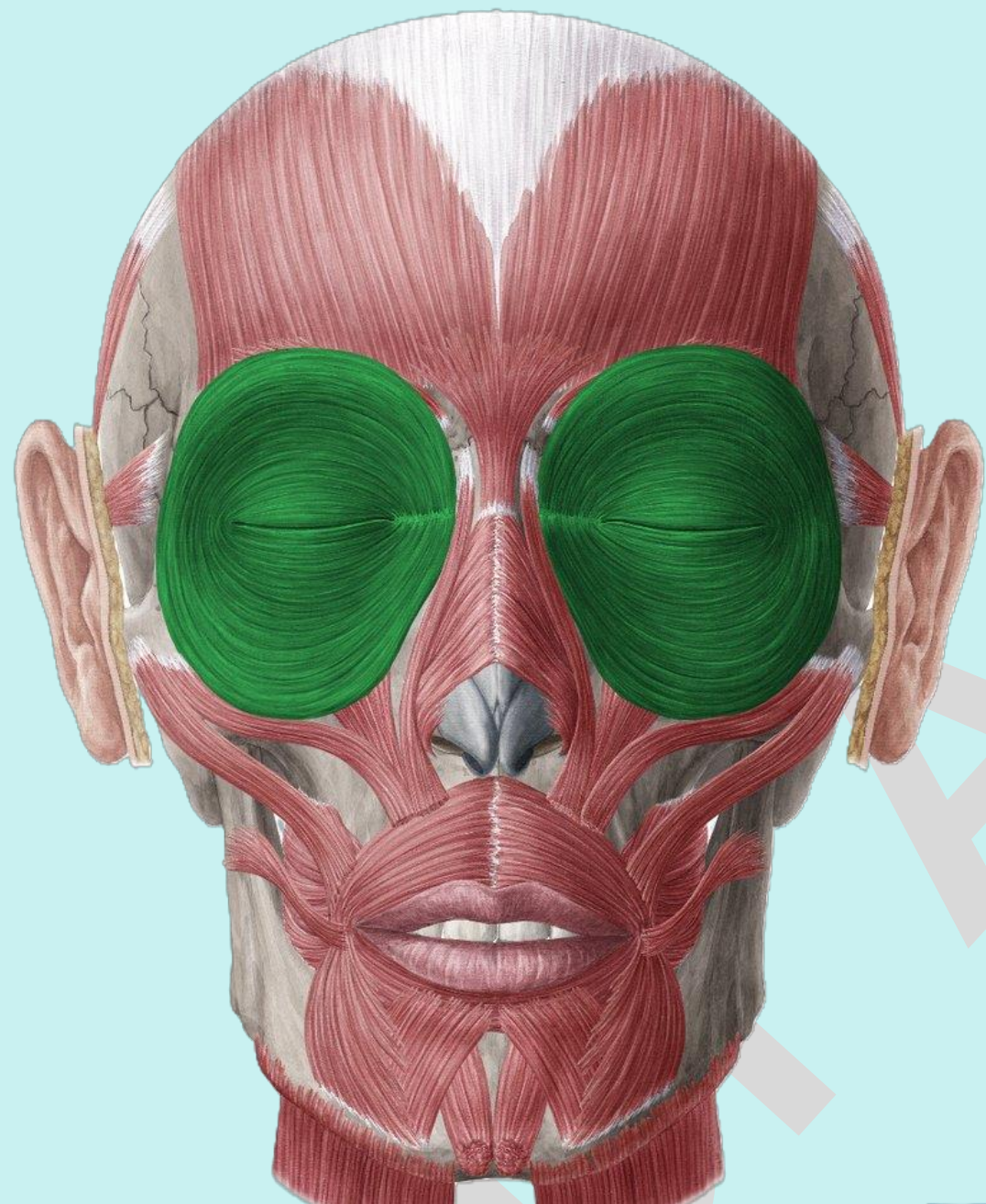


# Check List:

## Muscles of the Head

### Muscles of the Facial Expression:

2. **Orbicularis Oculi:** identify the location, origin, insertion and action.

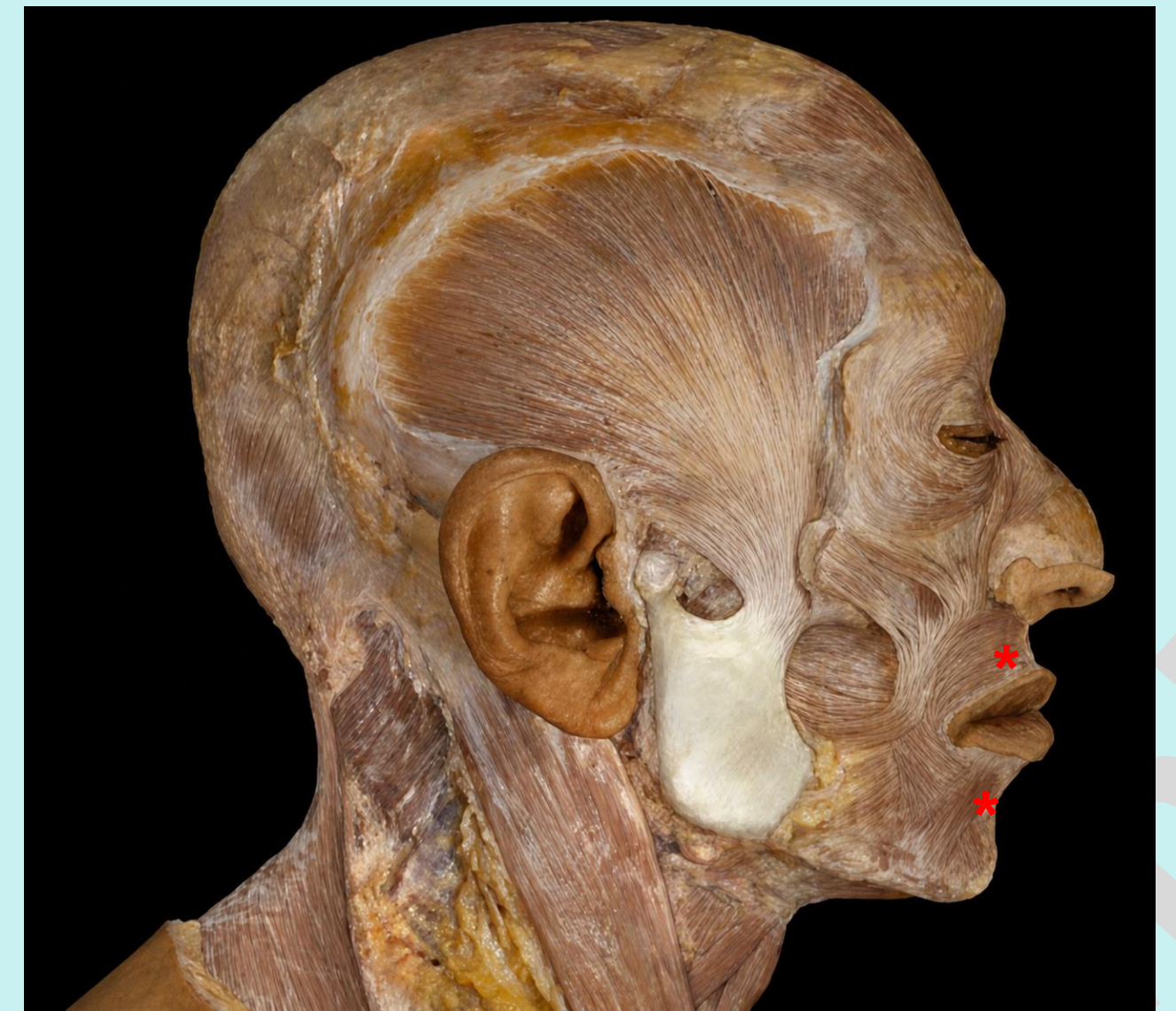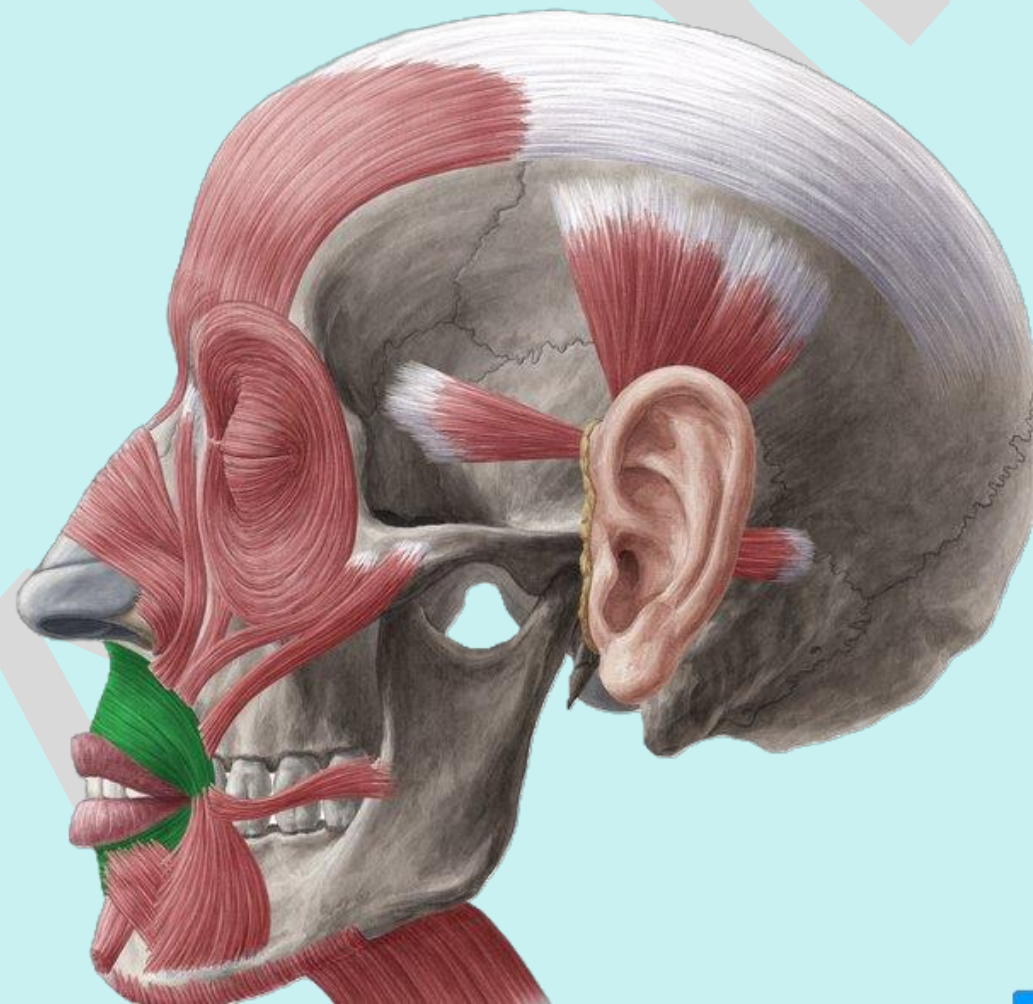
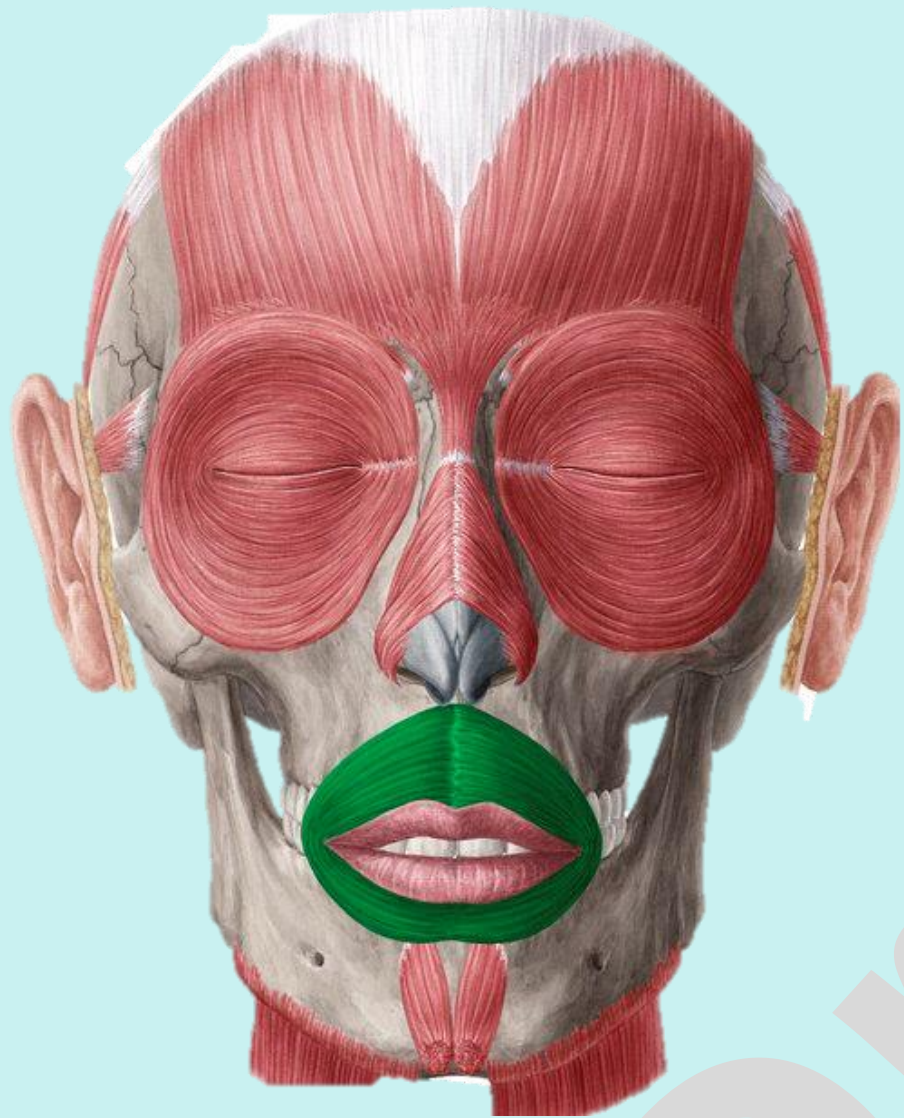


# Check List:

## Muscles of the Head

### Muscles of the Facial Expression:

3. **Orbicularis Oris:** identify the location, origin, insertion and action.



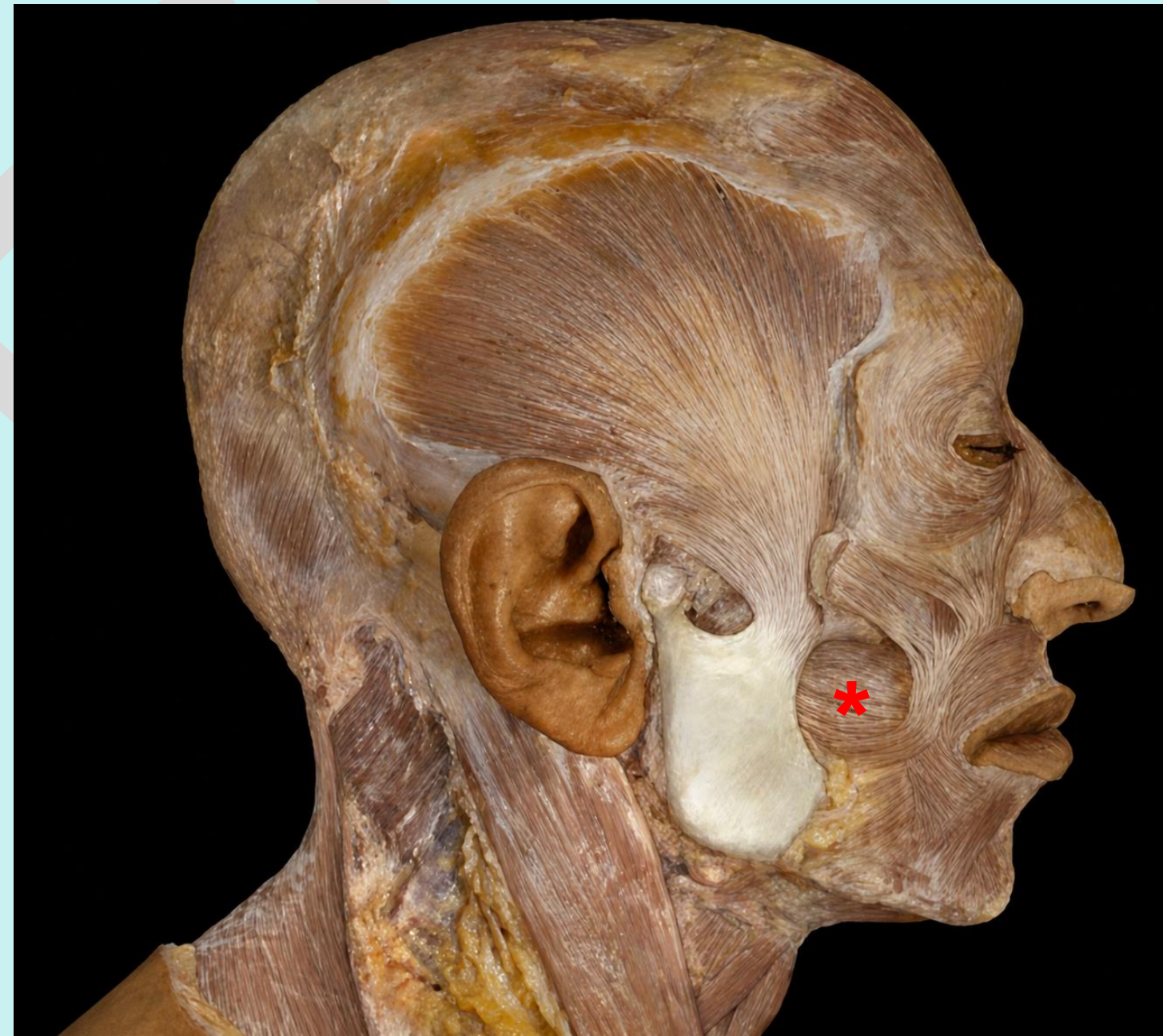
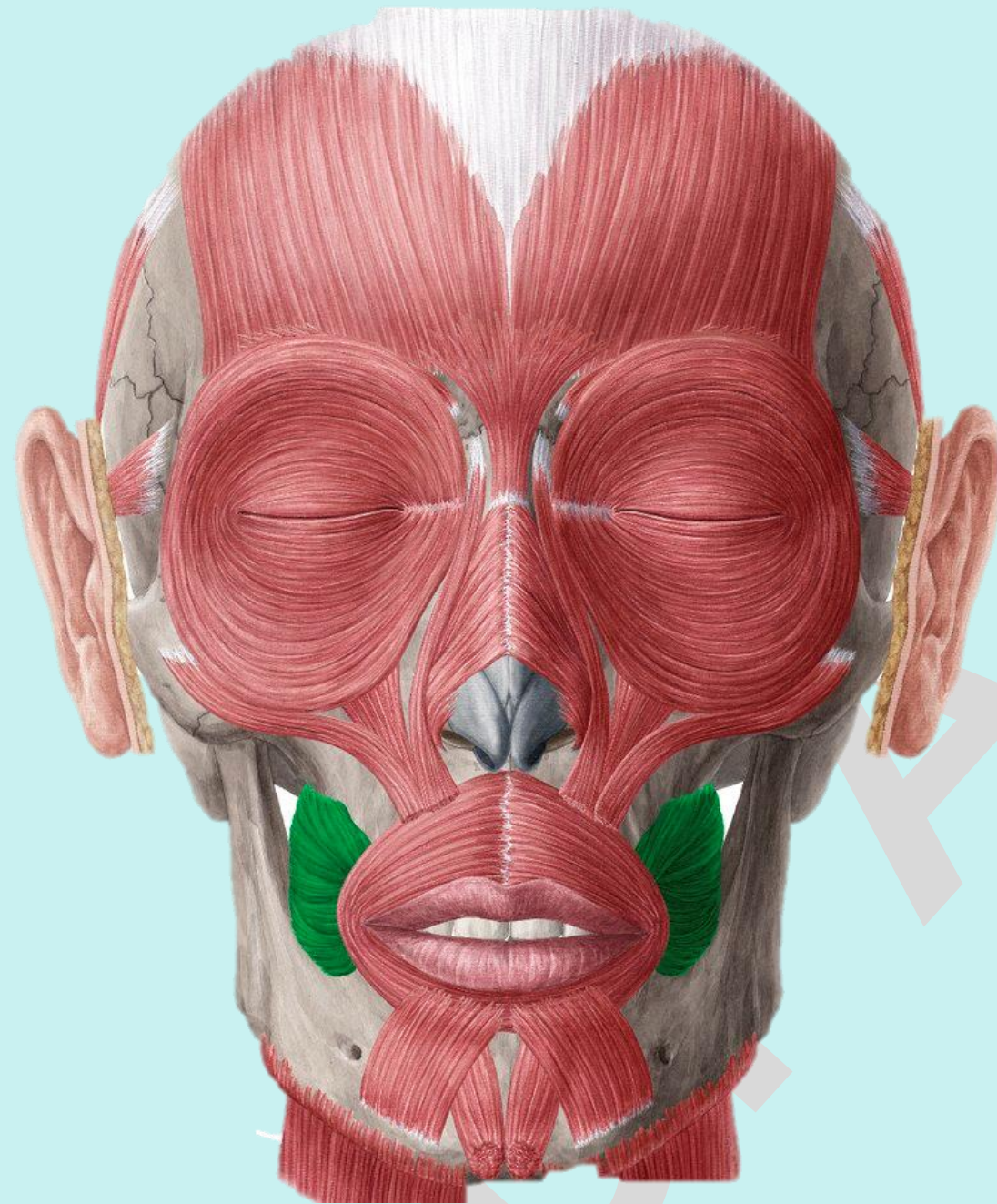
# Check List:

Practical Lab-9

## Muscles of the Head

### Muscles of the Facial Expression:

4. **Buccinator:** identify the location, origin, insertion and action.



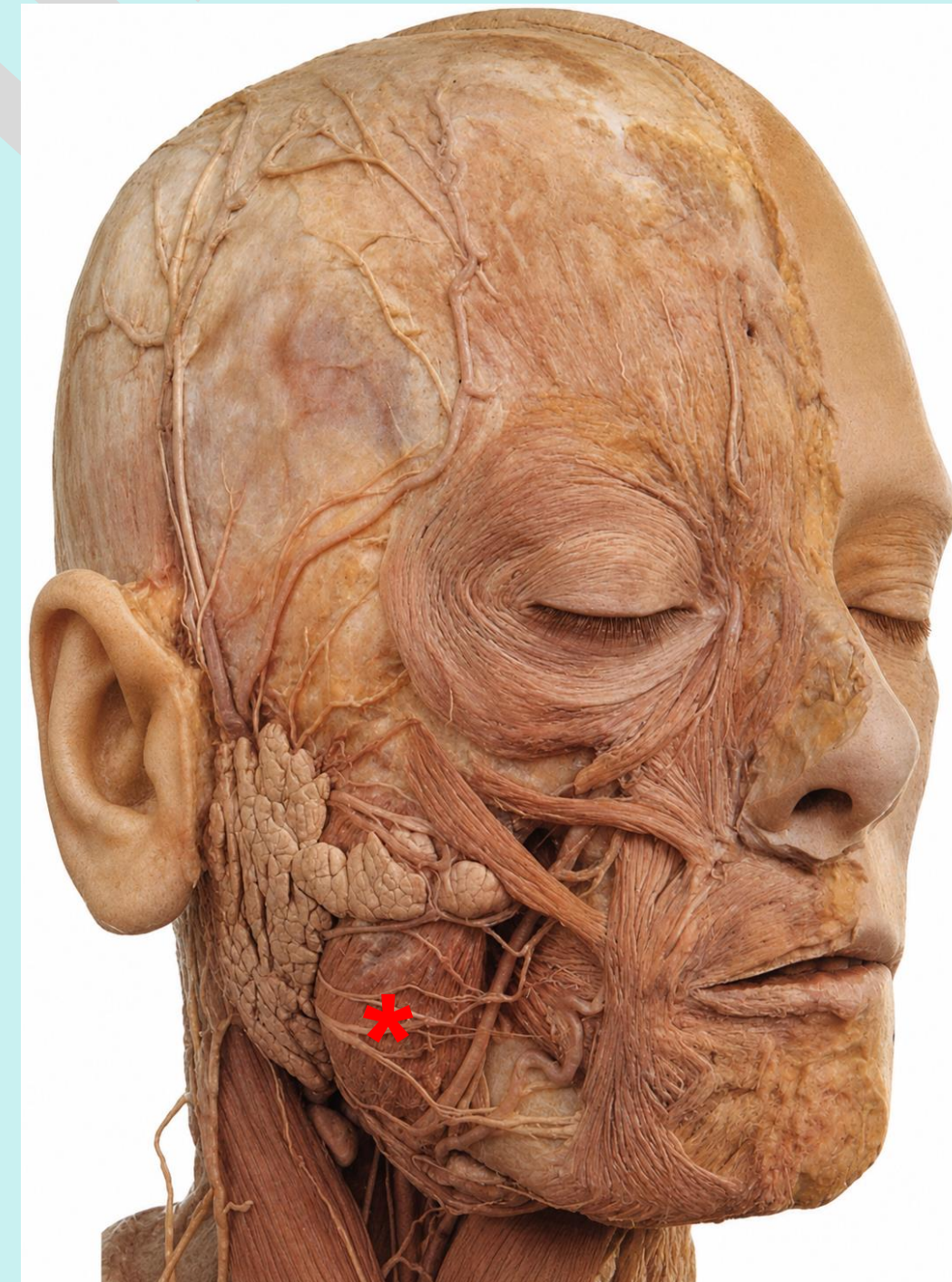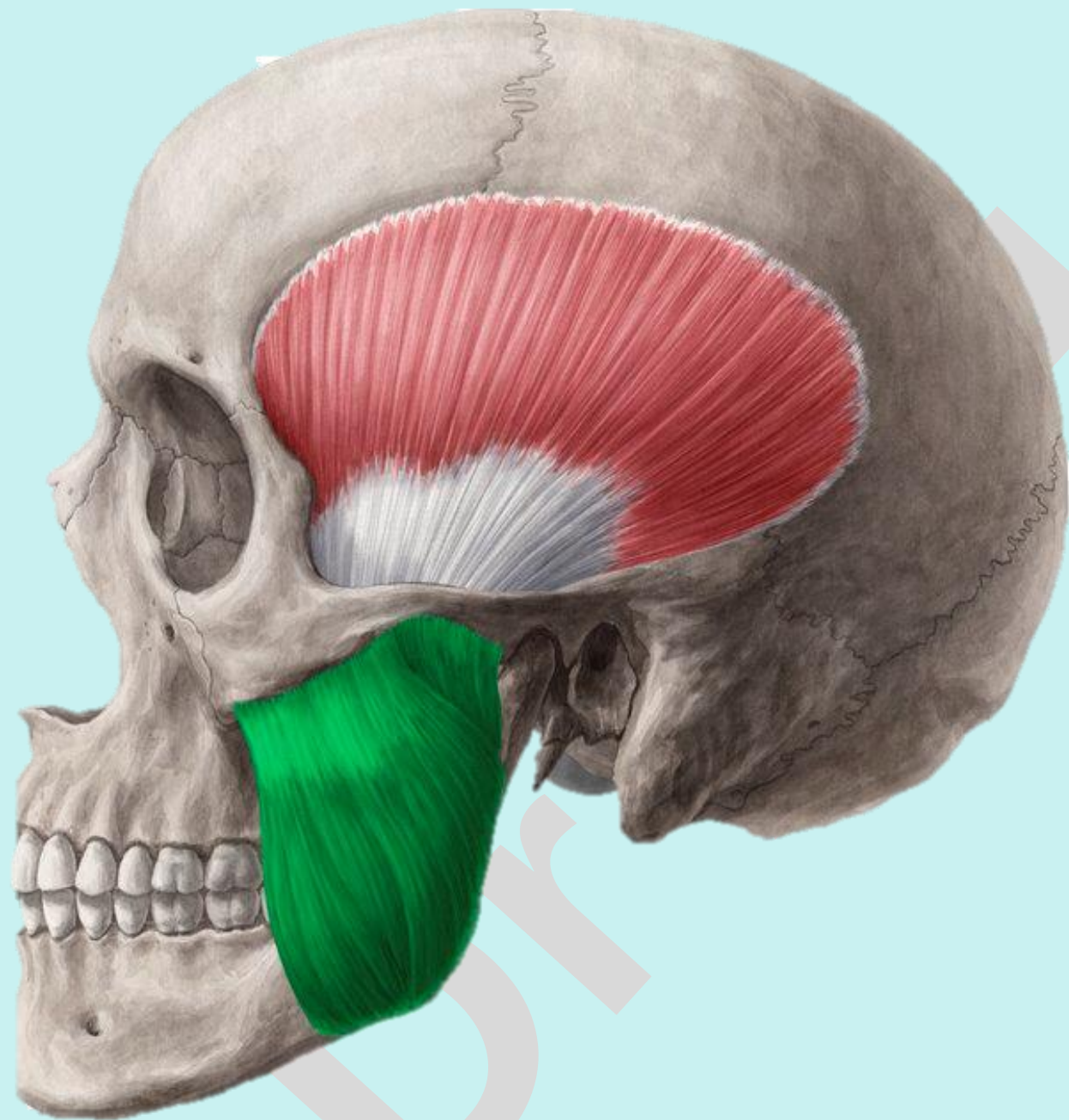
# Check List:

Practical Lab-9

## Muscles of the Head

### Muscles of the Mastication:

**1. Masseter:** identify the location, origin, insertion and action.

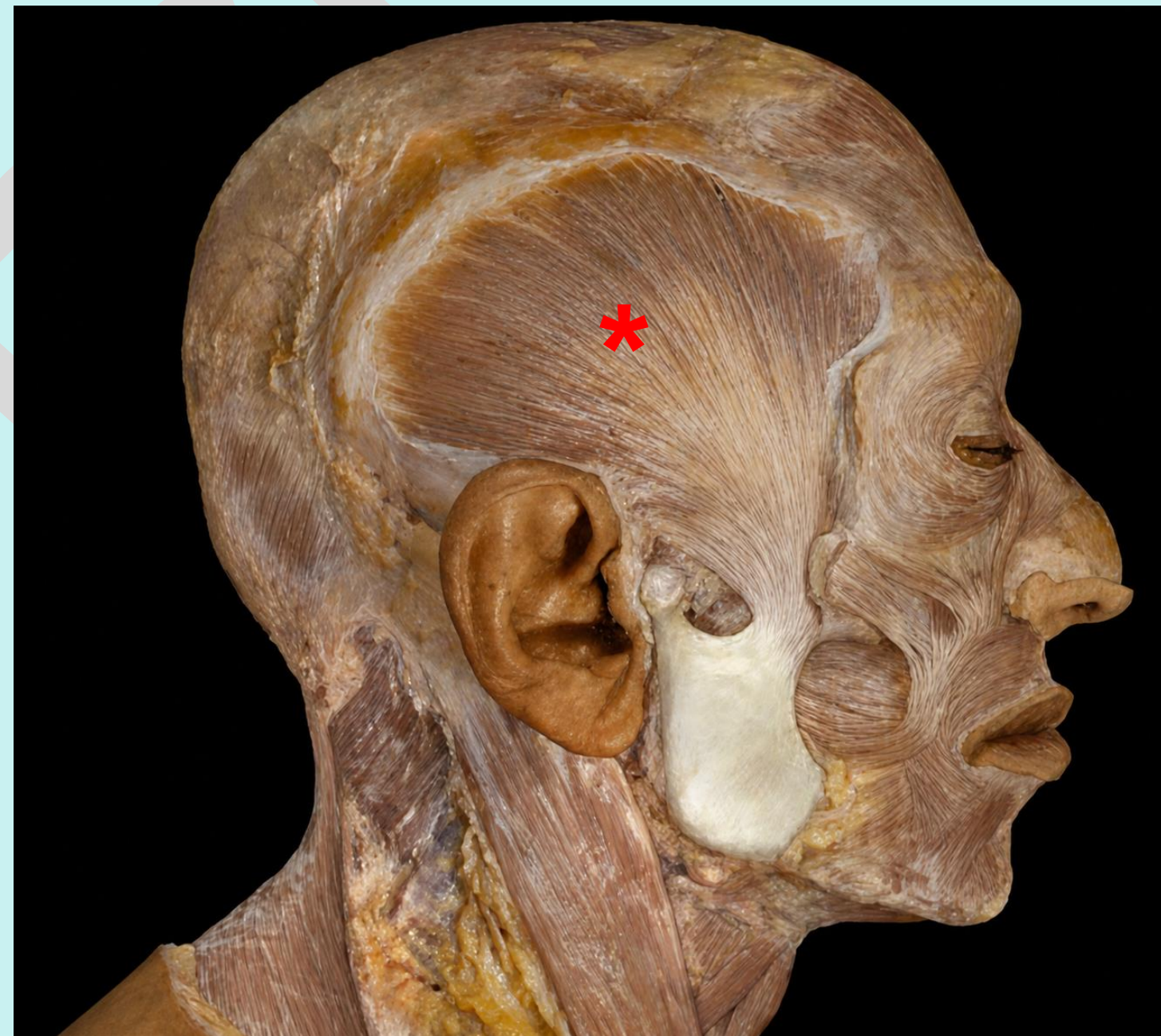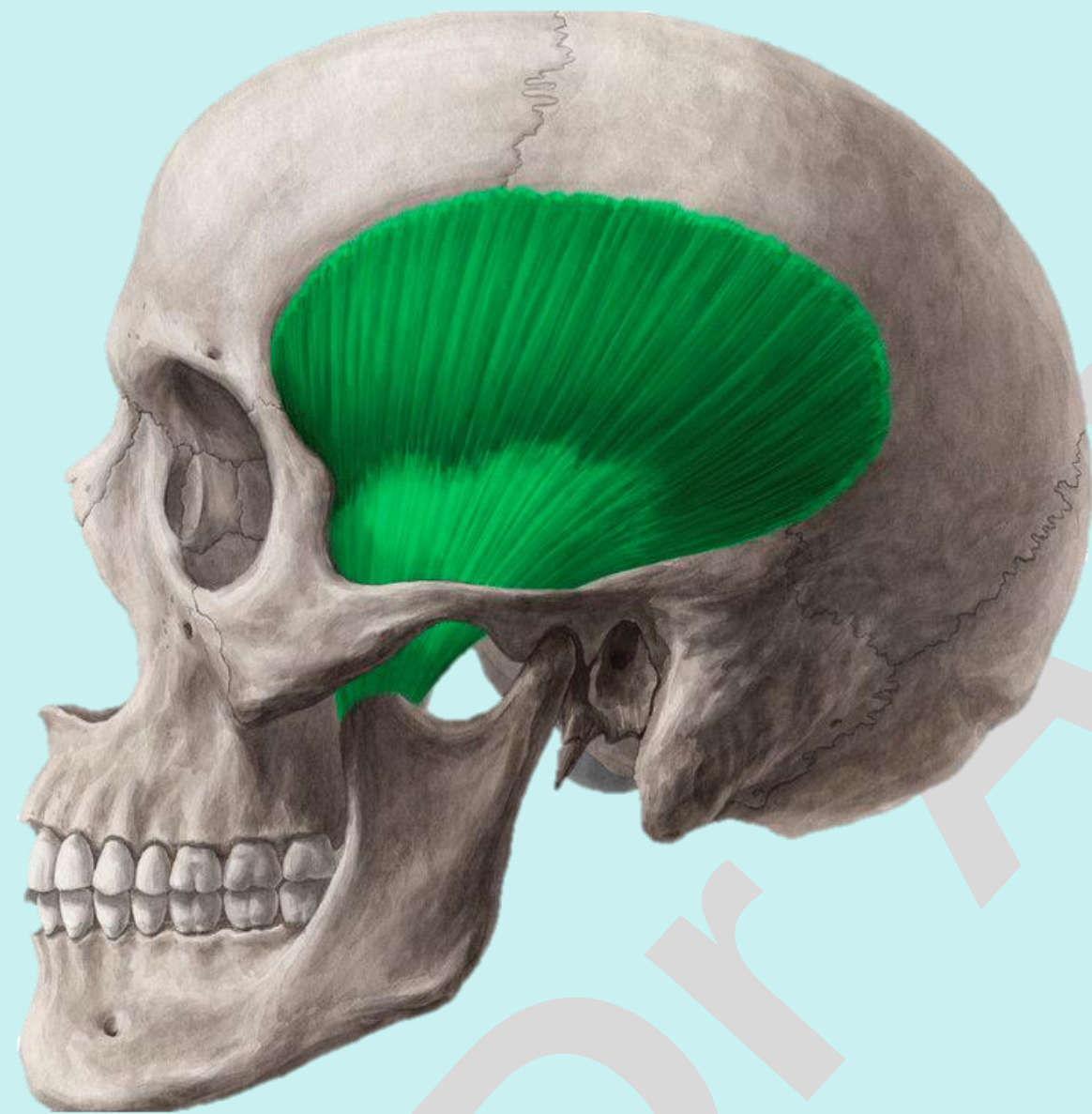


# Check List:

## Muscles of the Head

### Muscles of the Mastication:

**2. Temporalis:** identify the location, origin, insertion and action.

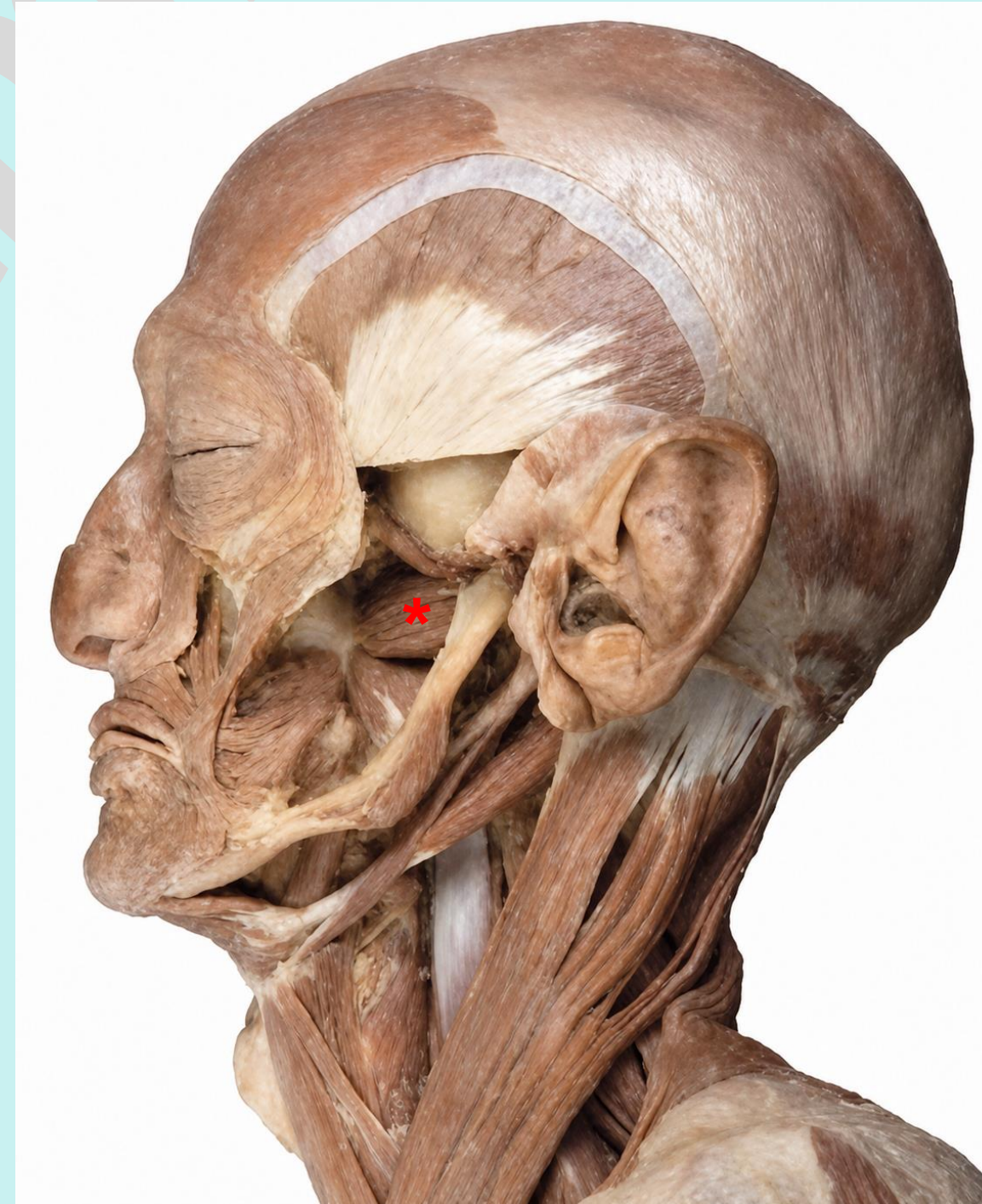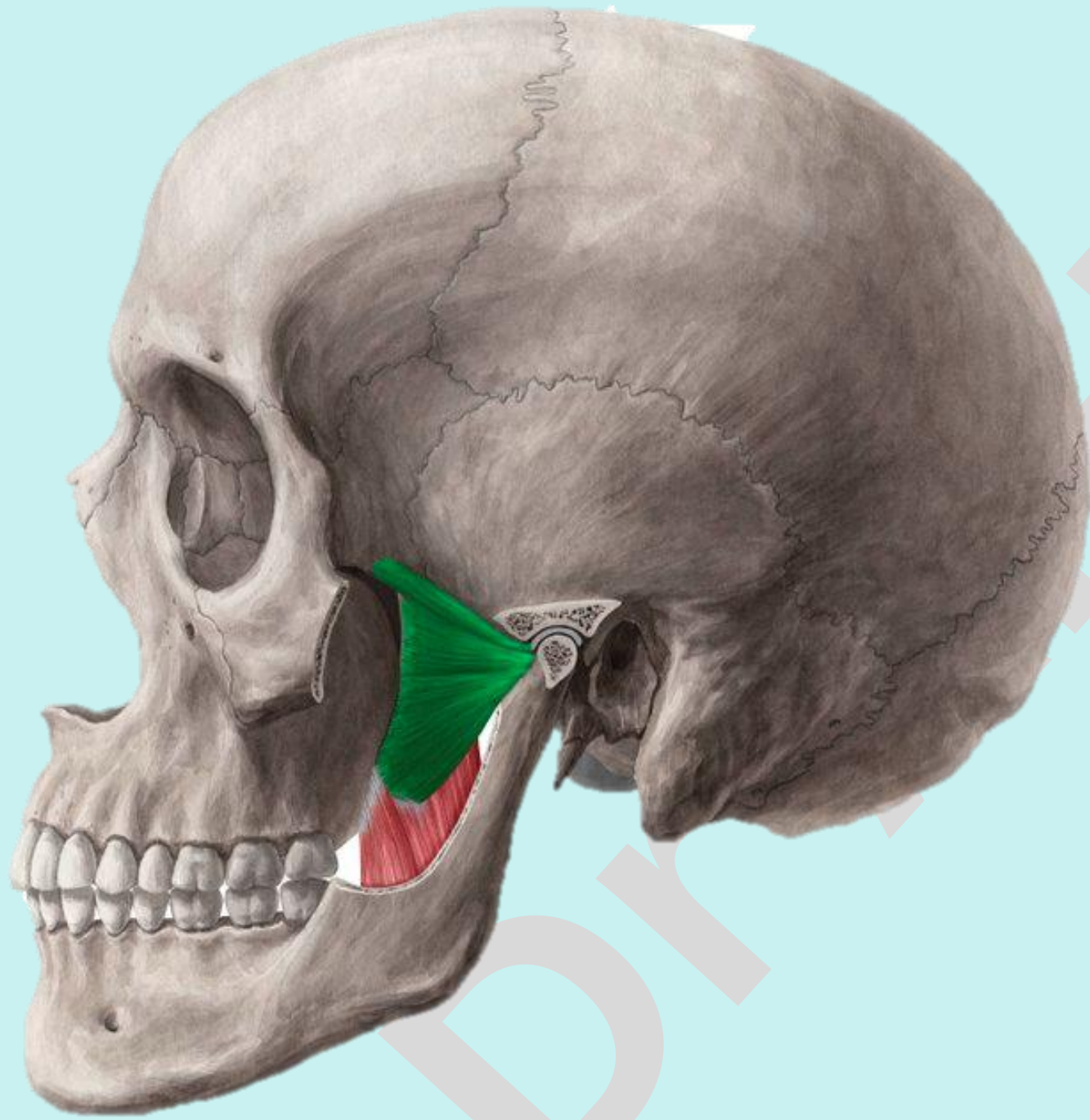


# Check List:

## Muscles of the Head

### Muscles of the Mastication:

3. **Lateral pterygoid:** identify the location, origin, insertion and action.



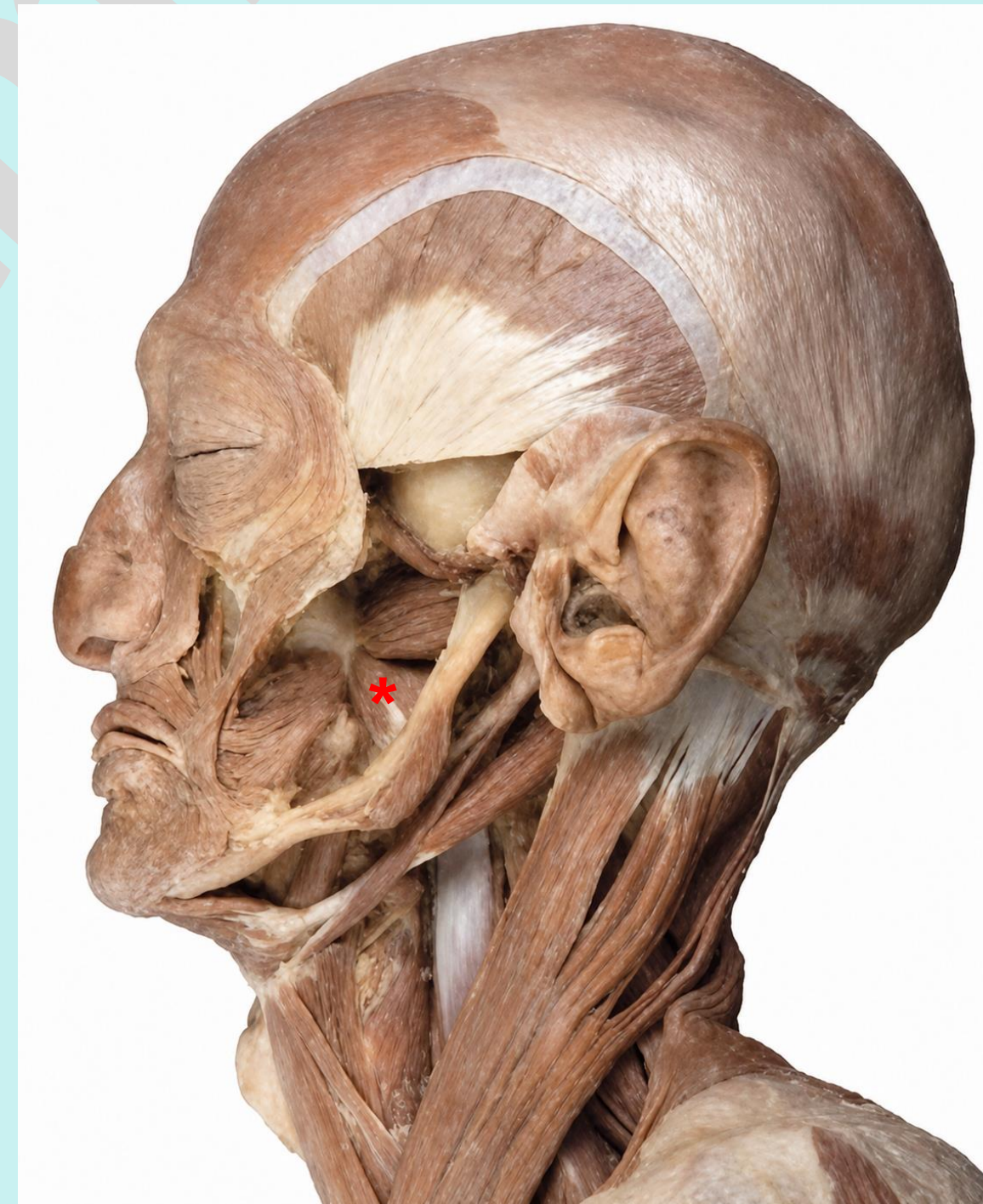
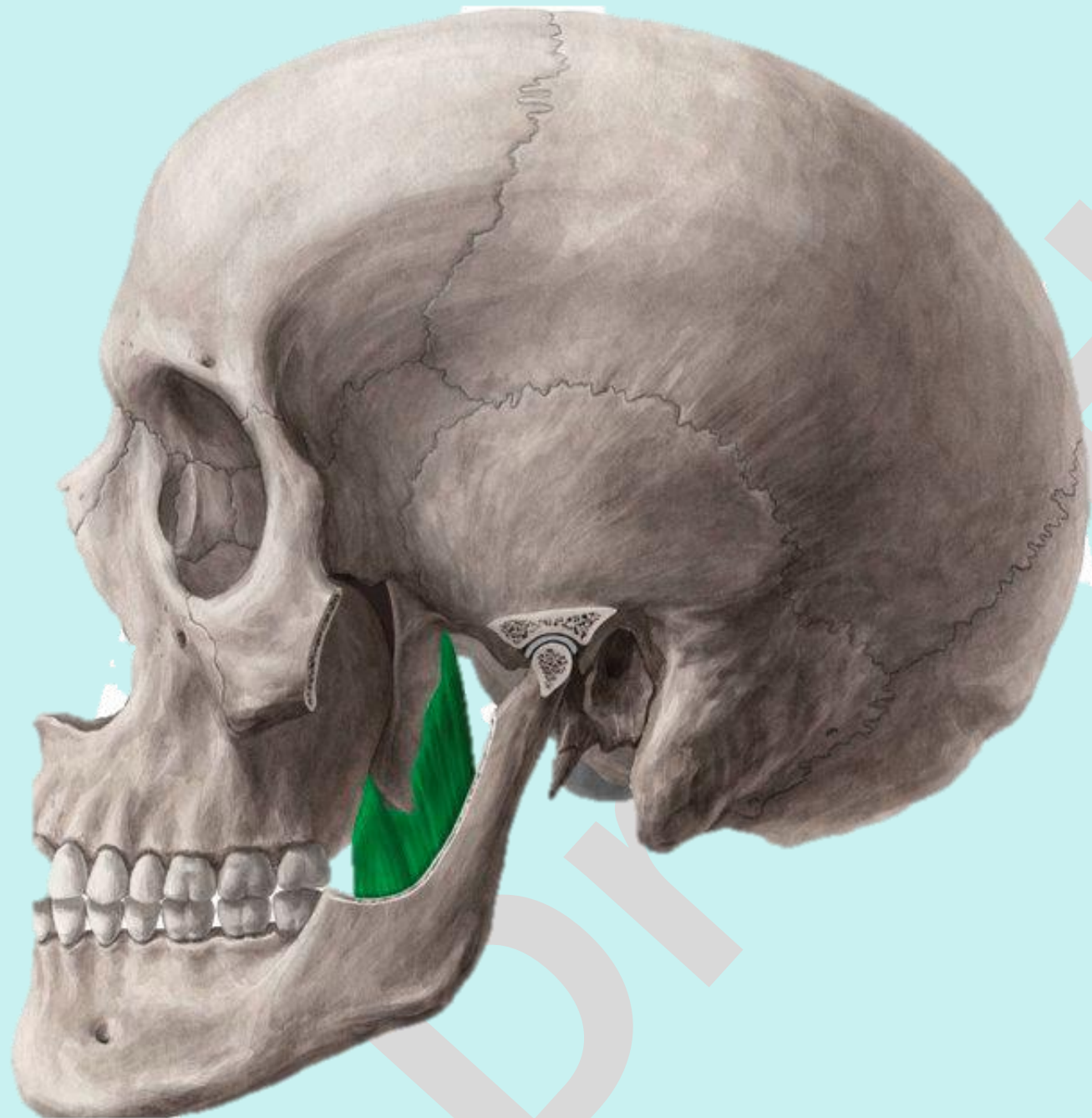
# Check List:

Practical Lab-9

## Muscles of the Head

### Muscles of the Mastication:

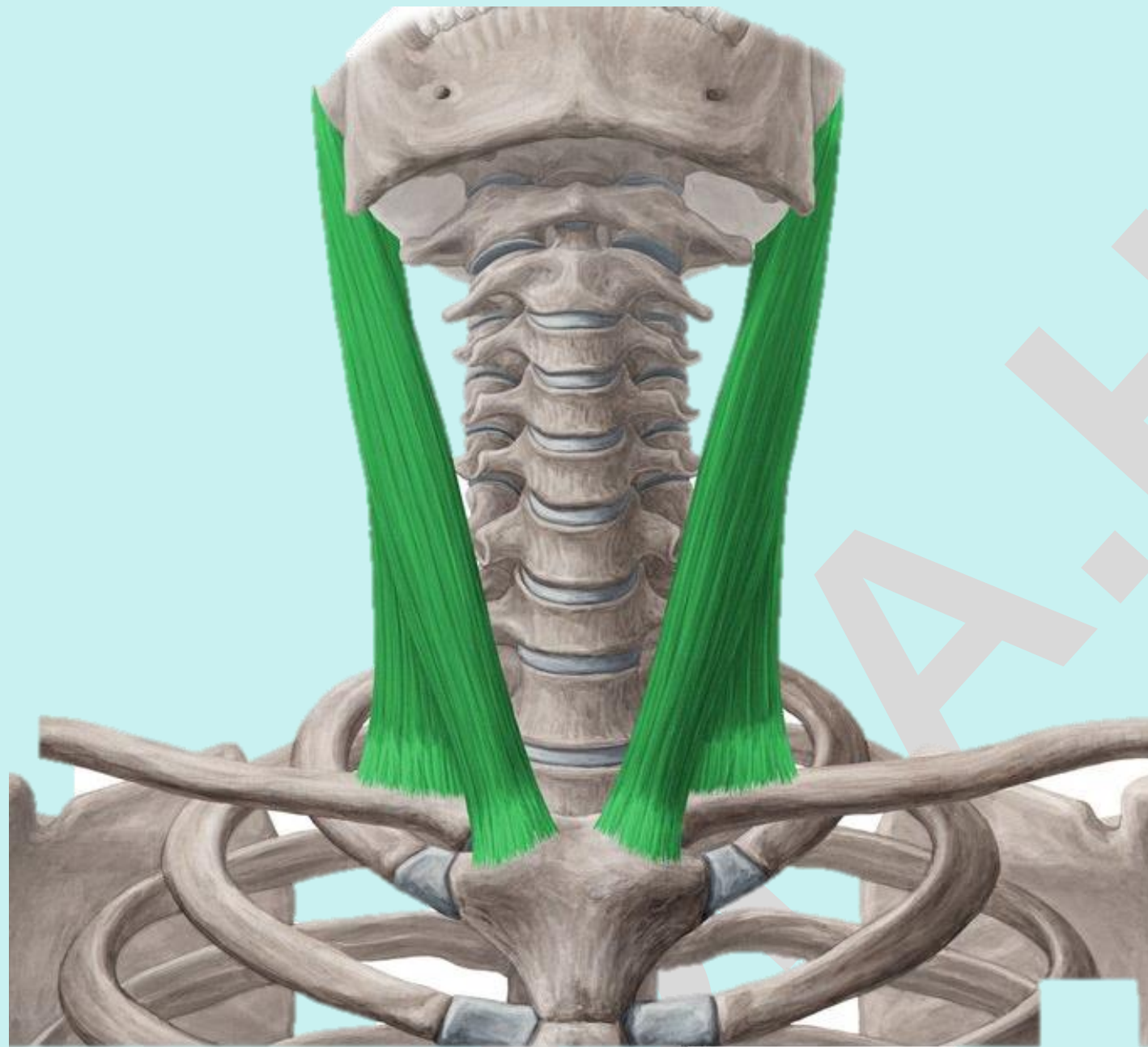
4. **Medial pterygoid:** identify the location, origin, insertion and action.



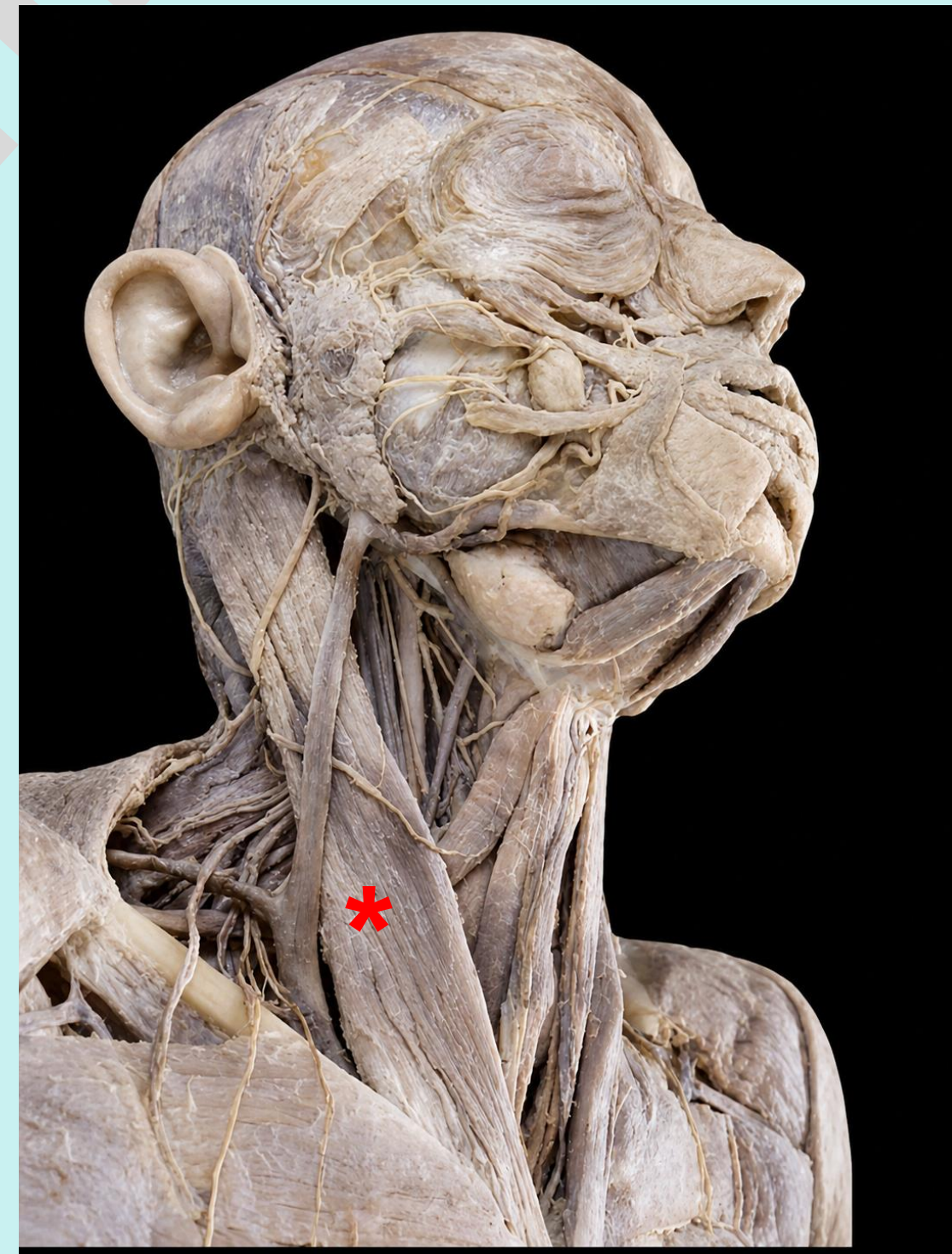# Check List:

## Muscles of the Neck

**Sternocleidomastoid:** identify the location, origin, insertion and action.



© www.kenhub.com



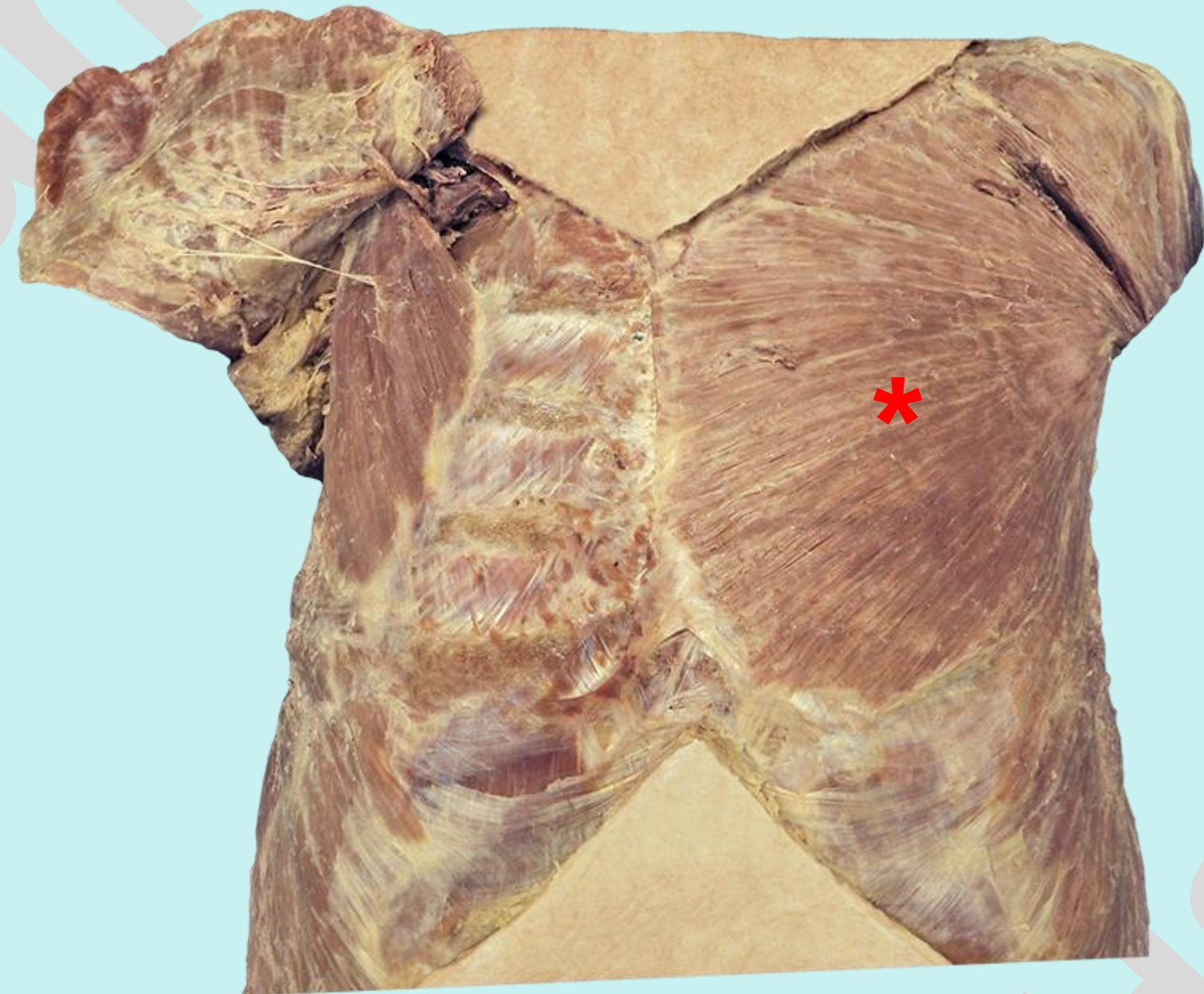
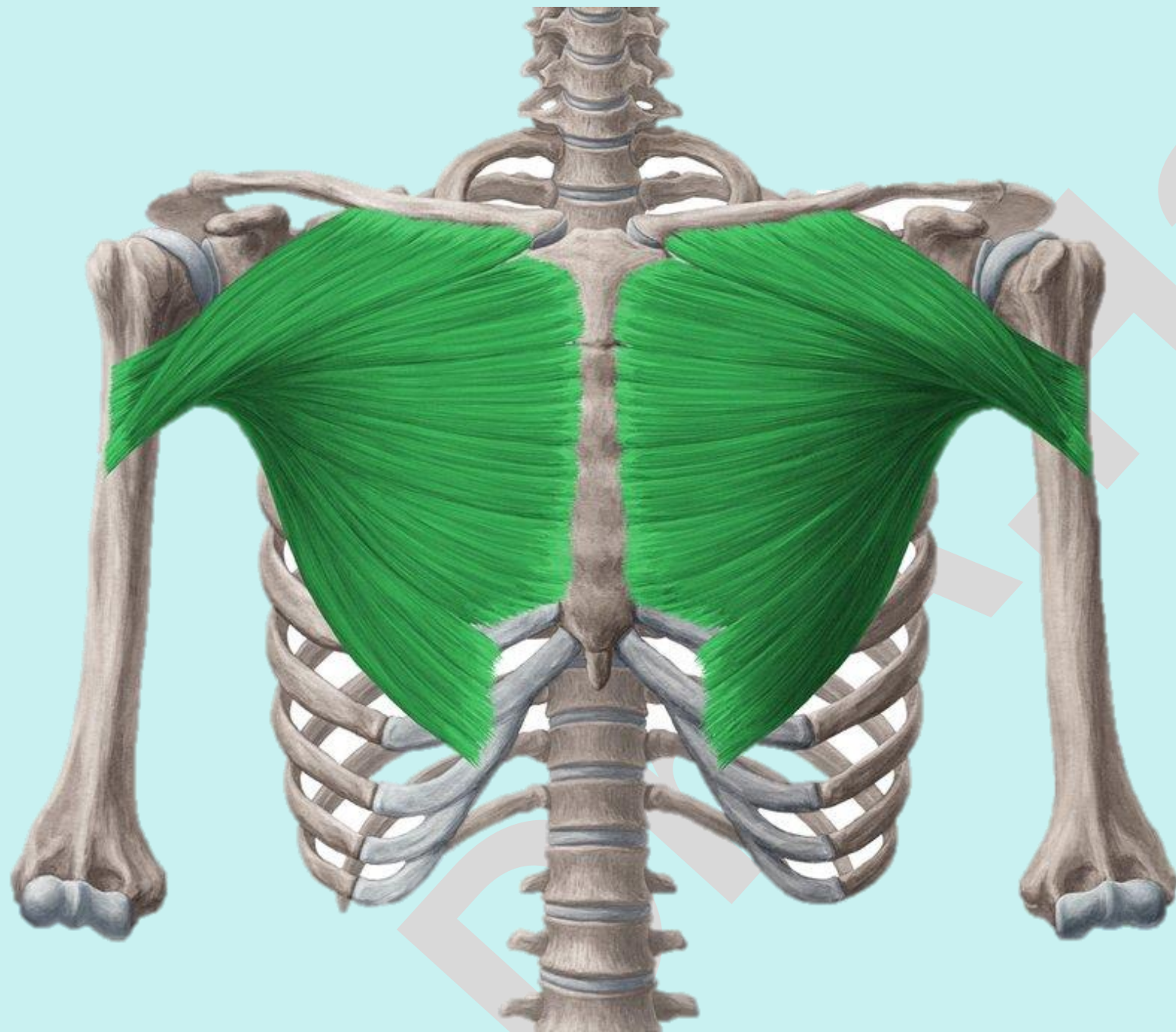
# Check List:

Practical Lab-9

## Muscles of the Trunk

### Muscles of the Thoracic wall:

1. **Pectoralis major:** identify the location, origin, insertion and action.

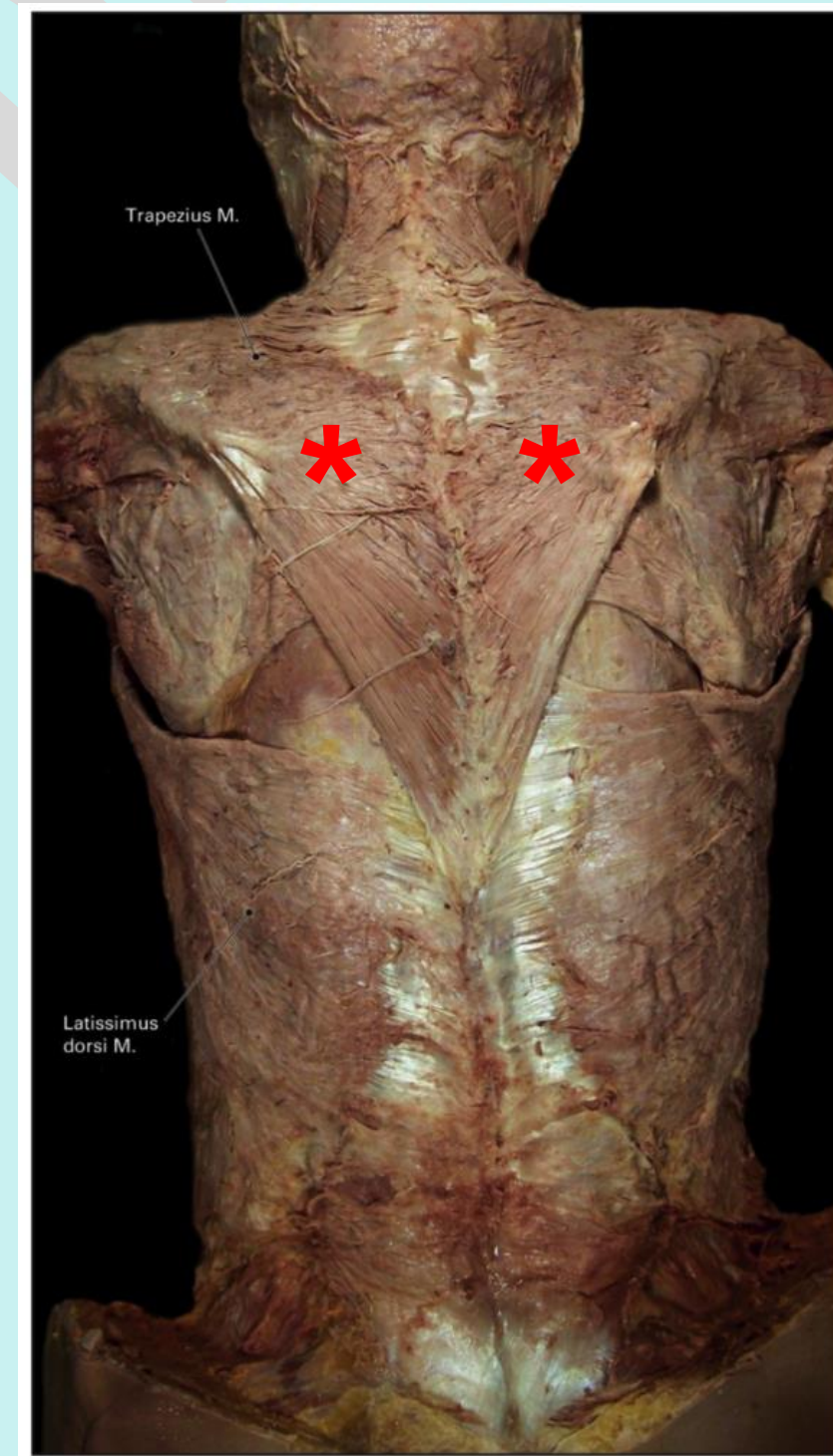
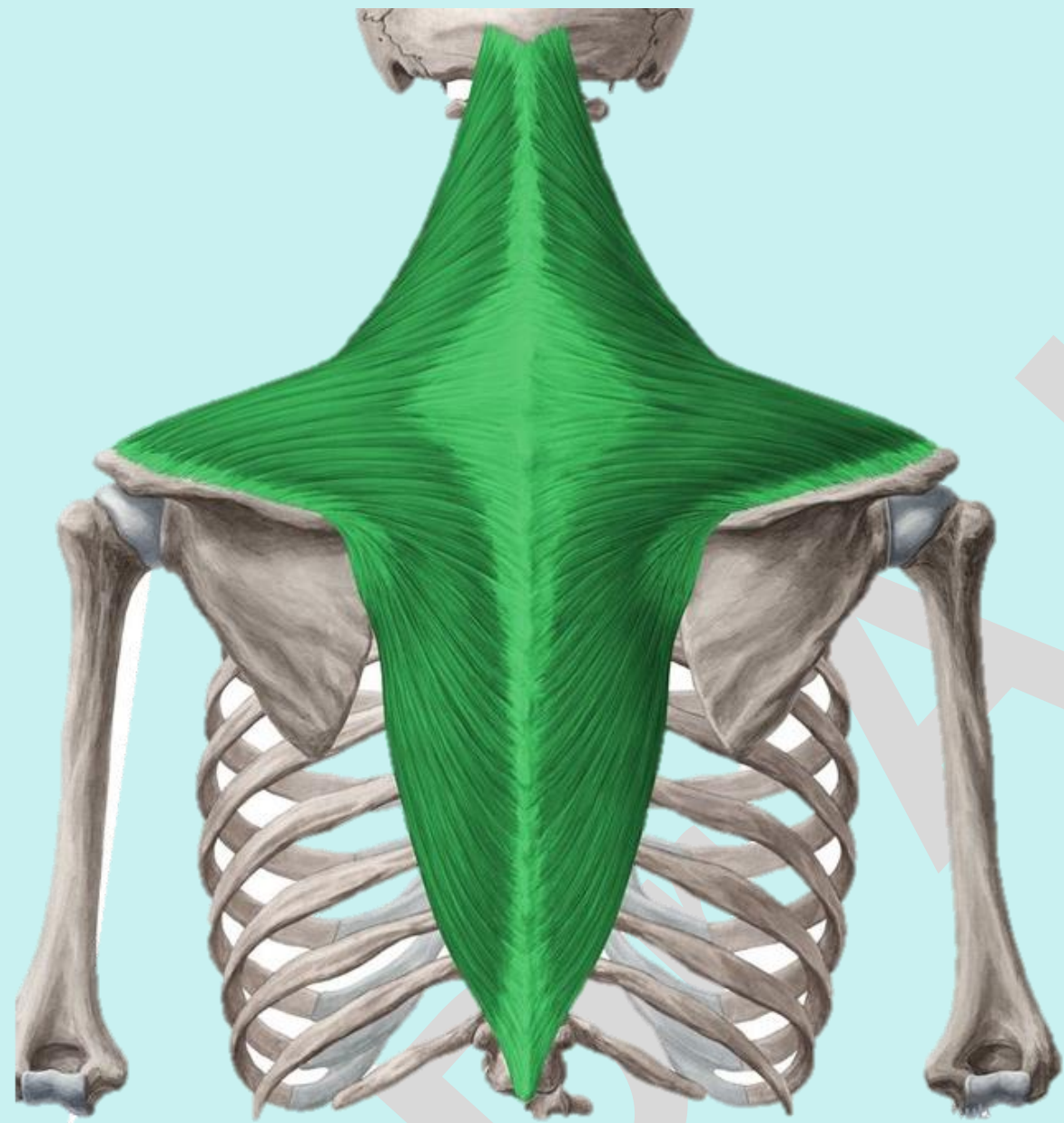


# Check List:

## Muscles of the Trunk

### Muscles of the Thoracic wall:

2. **Trapezius:** identify the location, origin, insertion and action.



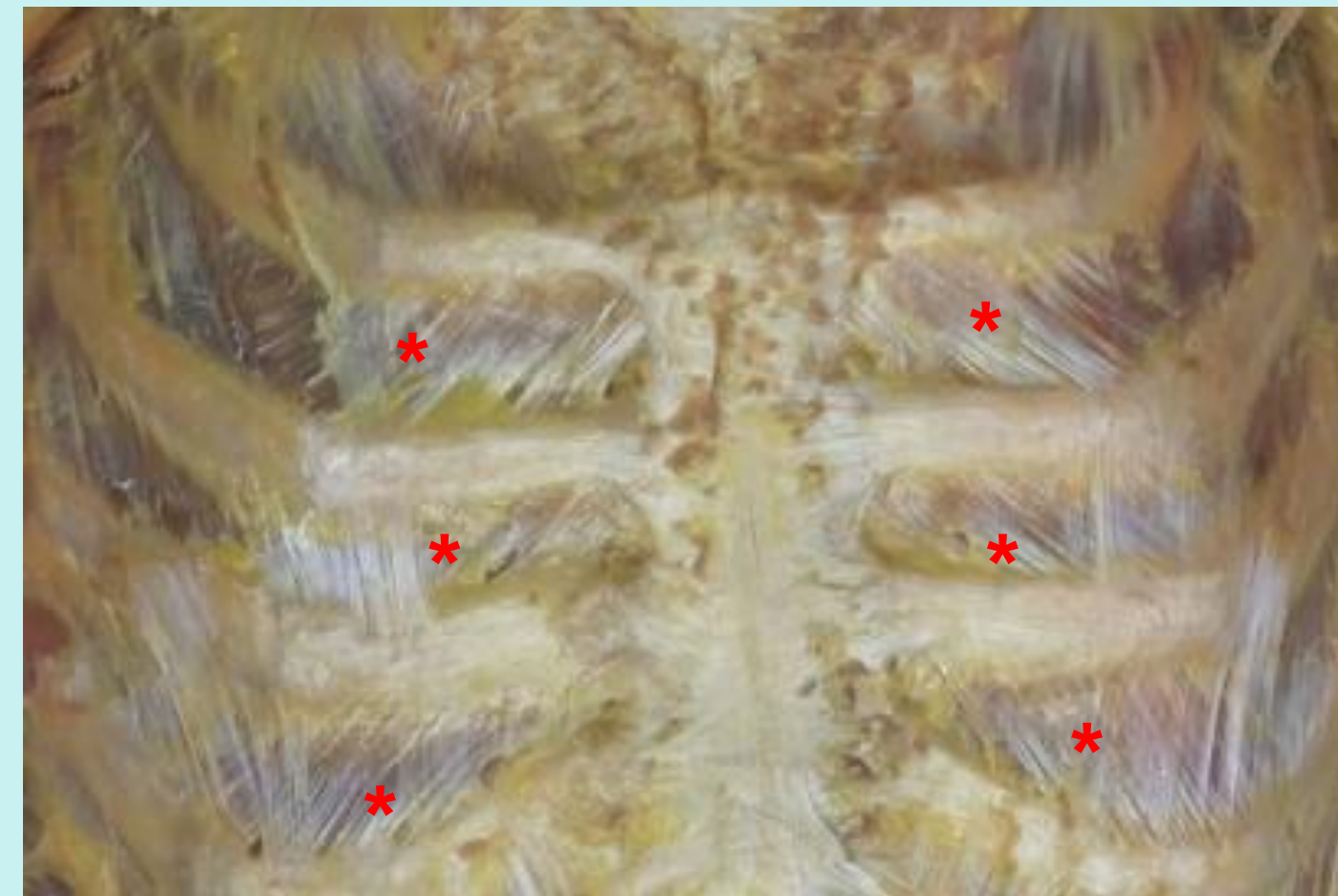
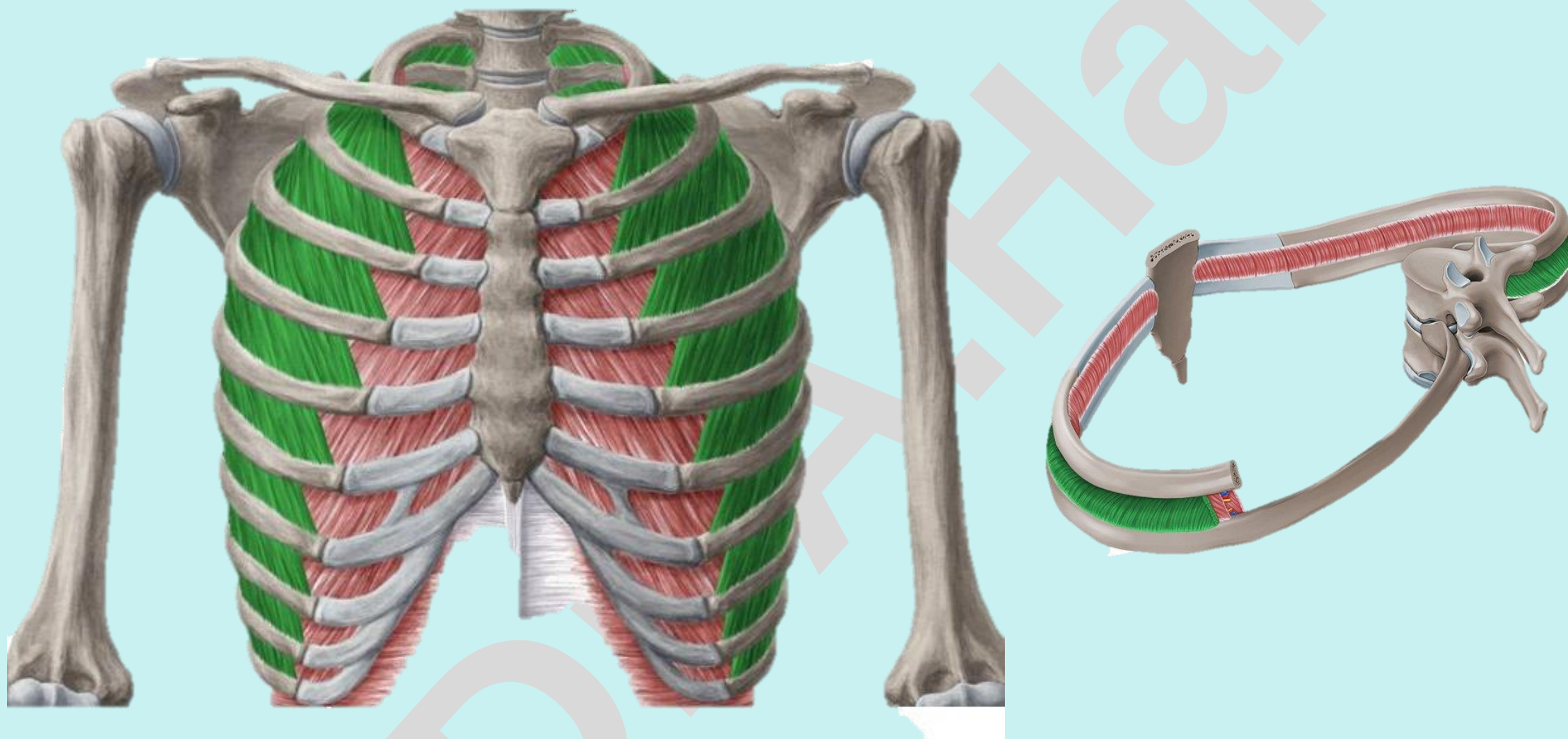
# Check List:

## Muscles of the Trunk

### Muscles of the Thoracic wall:

#### 3. Intercostal muscles:

**External intercostal muscle:** identify the location, origin, insertion and action.



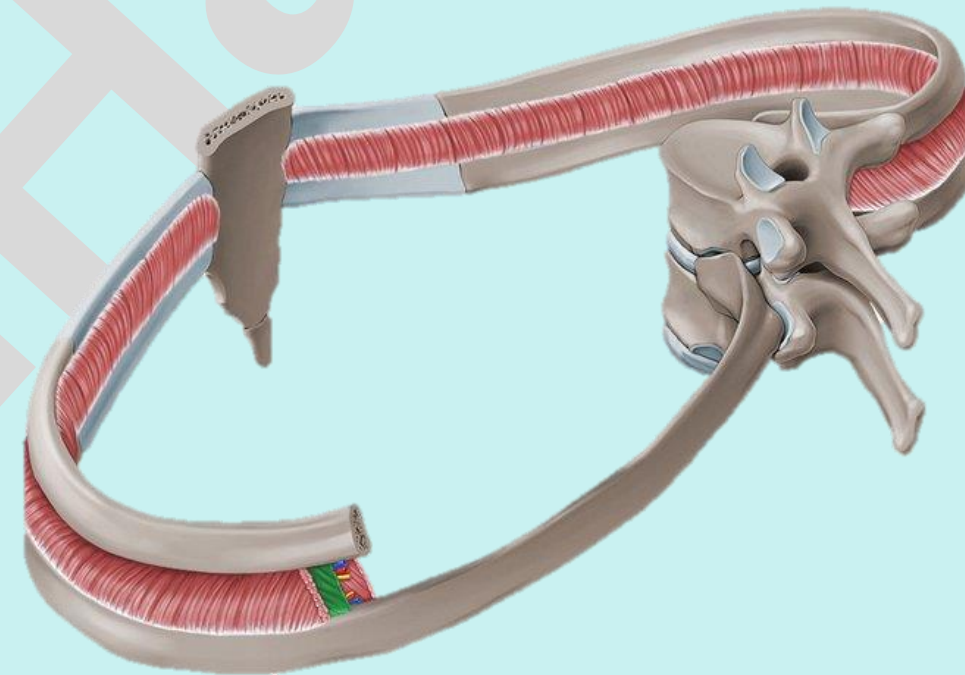
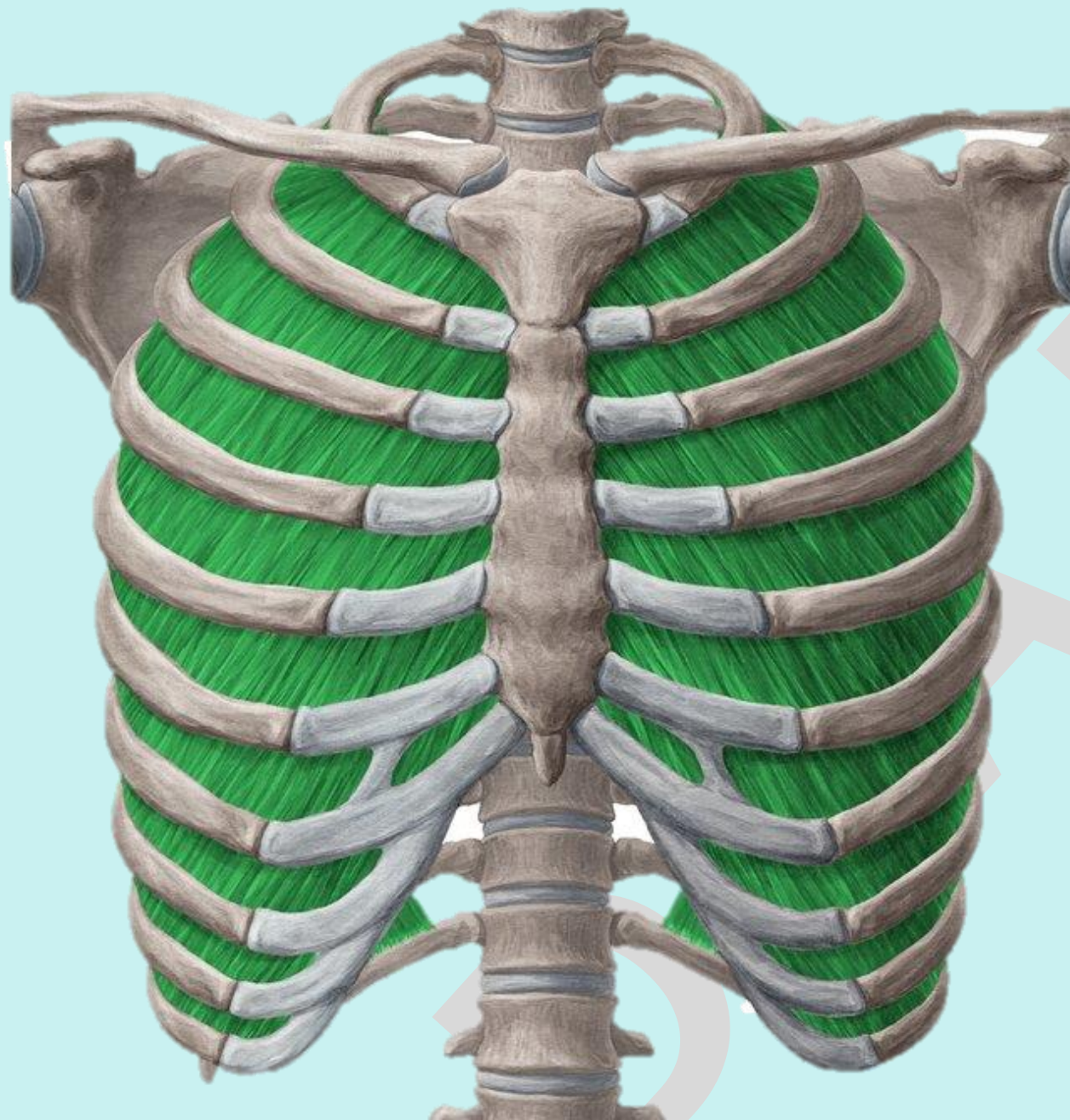
# Check List:

## Muscles of the Trunk

### Muscles of the Thoracic wall:

#### 3. Intercostal muscles:

**Internal intercostal muscle:** identify the location, origin, insertion and action.



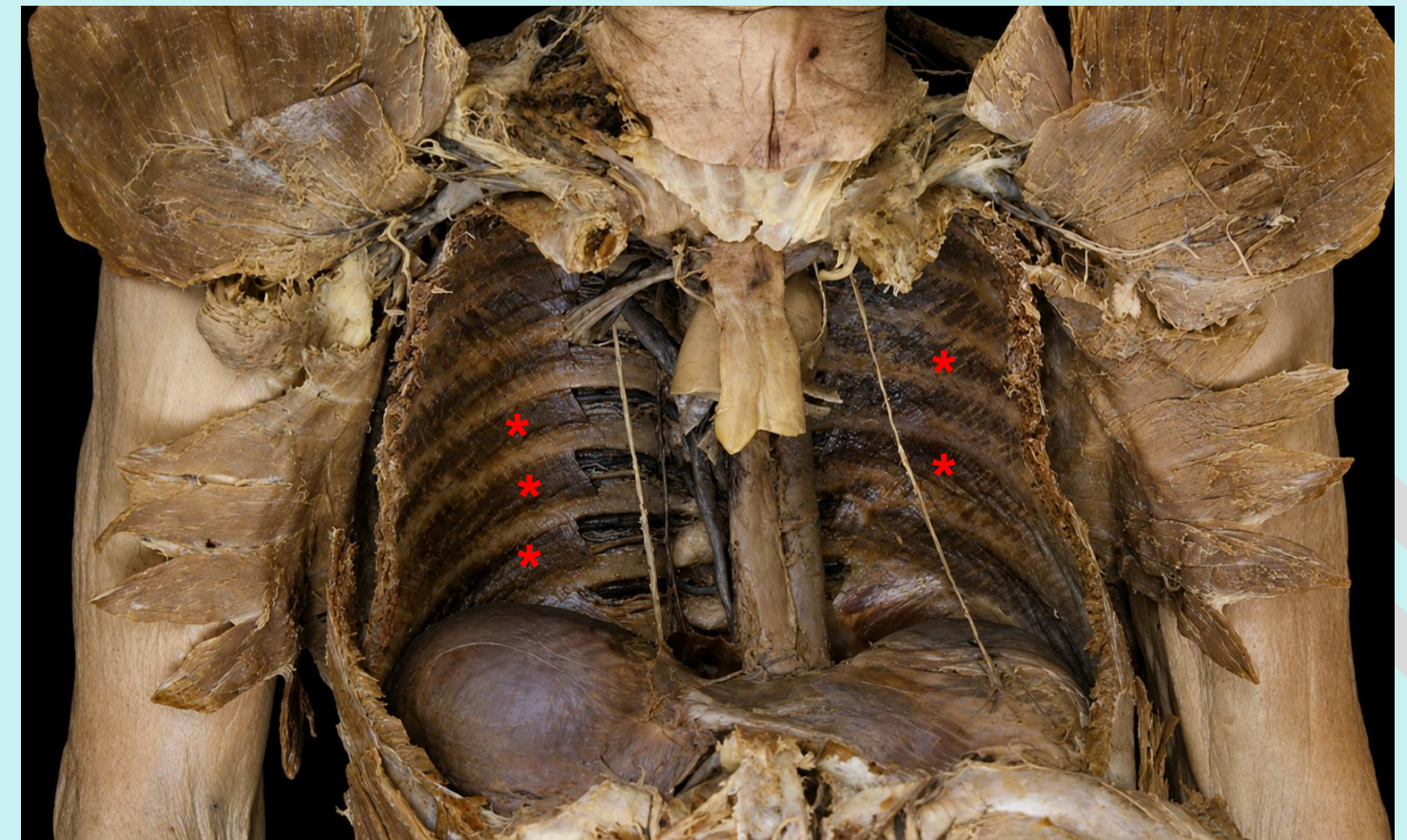
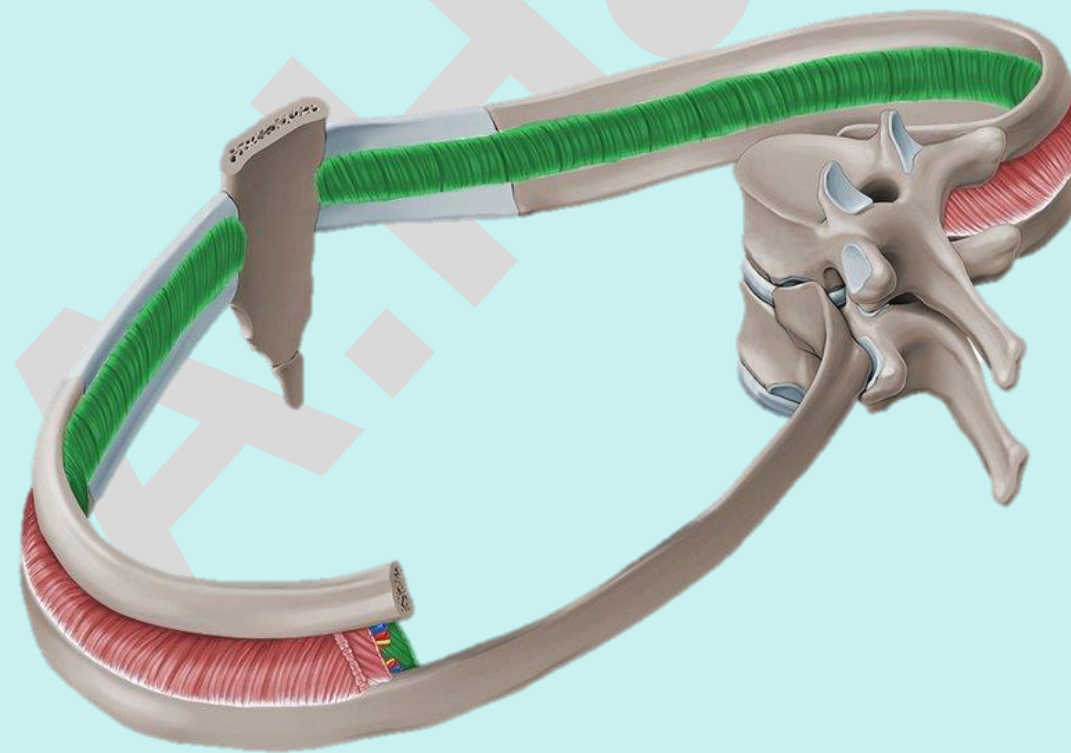
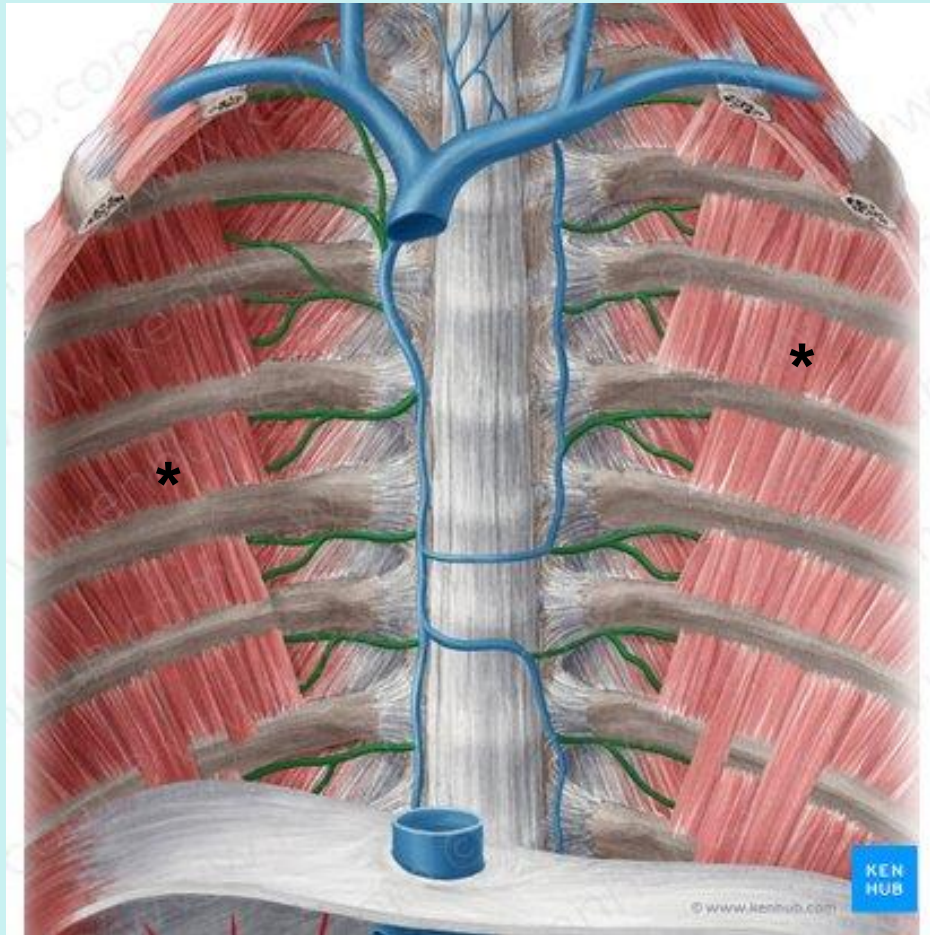
# Check List:

## Muscles of the Trunk

### Muscles of the Thoracic wall:

#### 3. Intercostal muscles:

**Innermost intercostal muscle:** identify the location, origin, insertion and action.

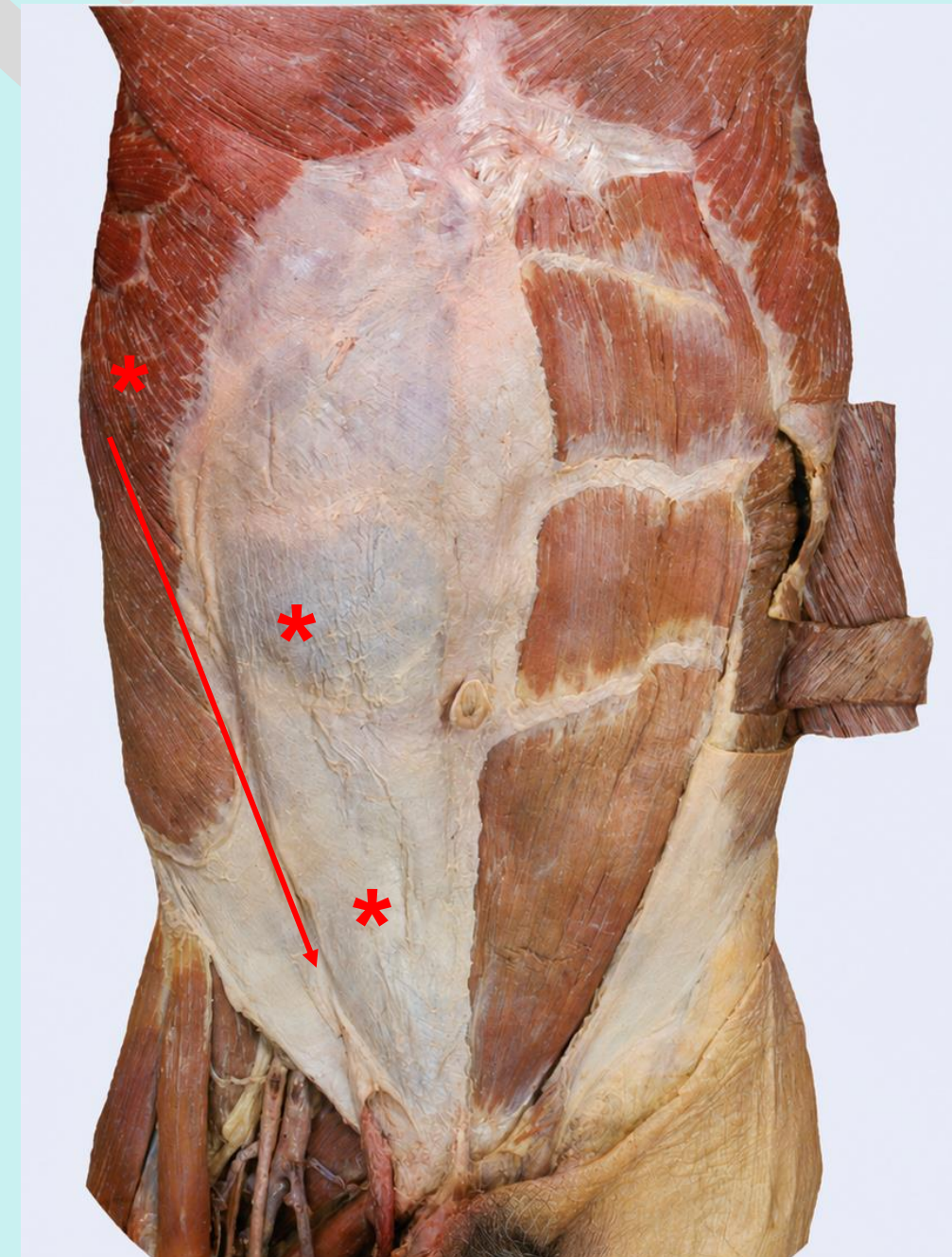
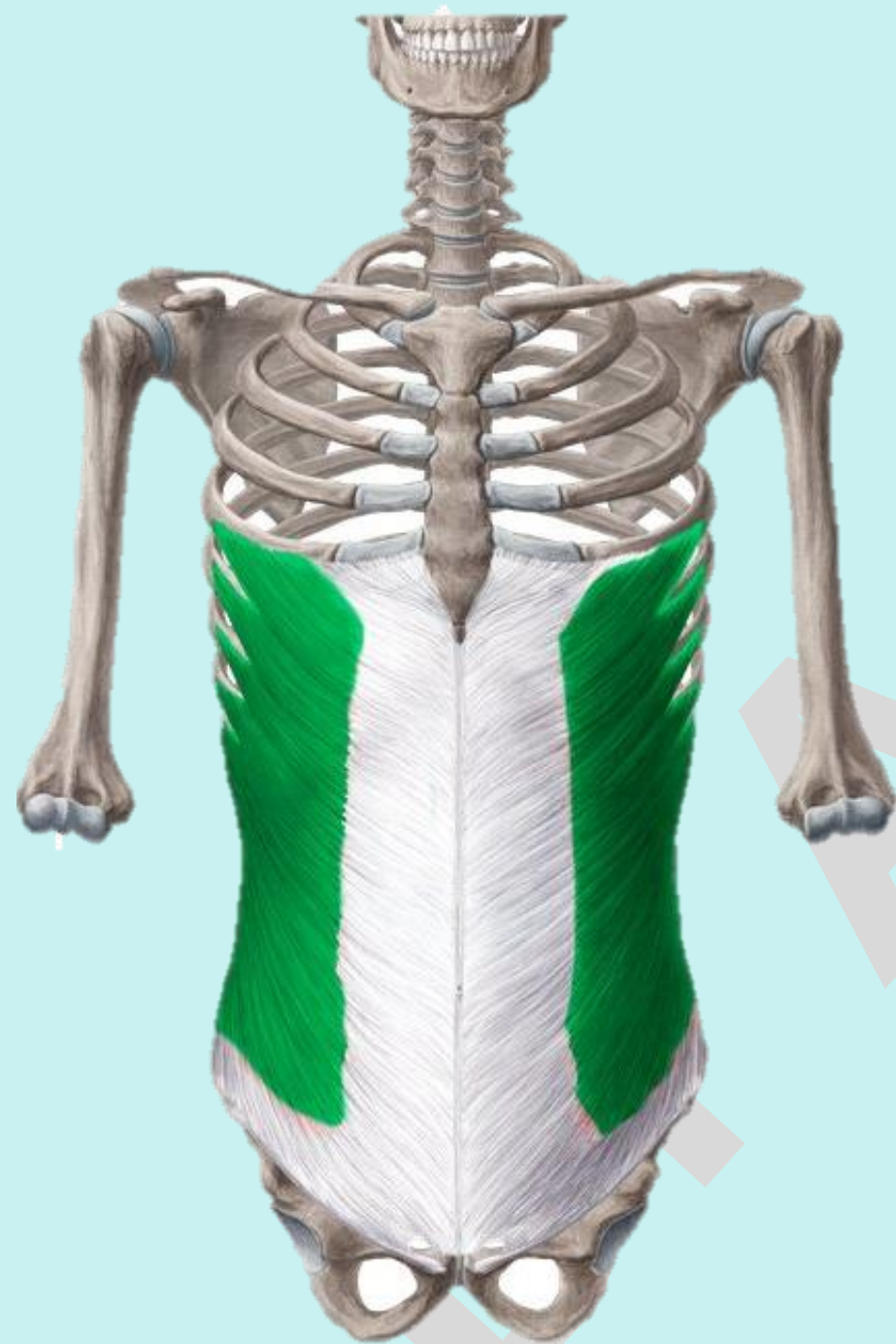
# Check List:

## Muscles of the Trunk

### Muscles of the Anterior Abdominal wall:

**1. External oblique:** identify the location, origin, insertion and action.

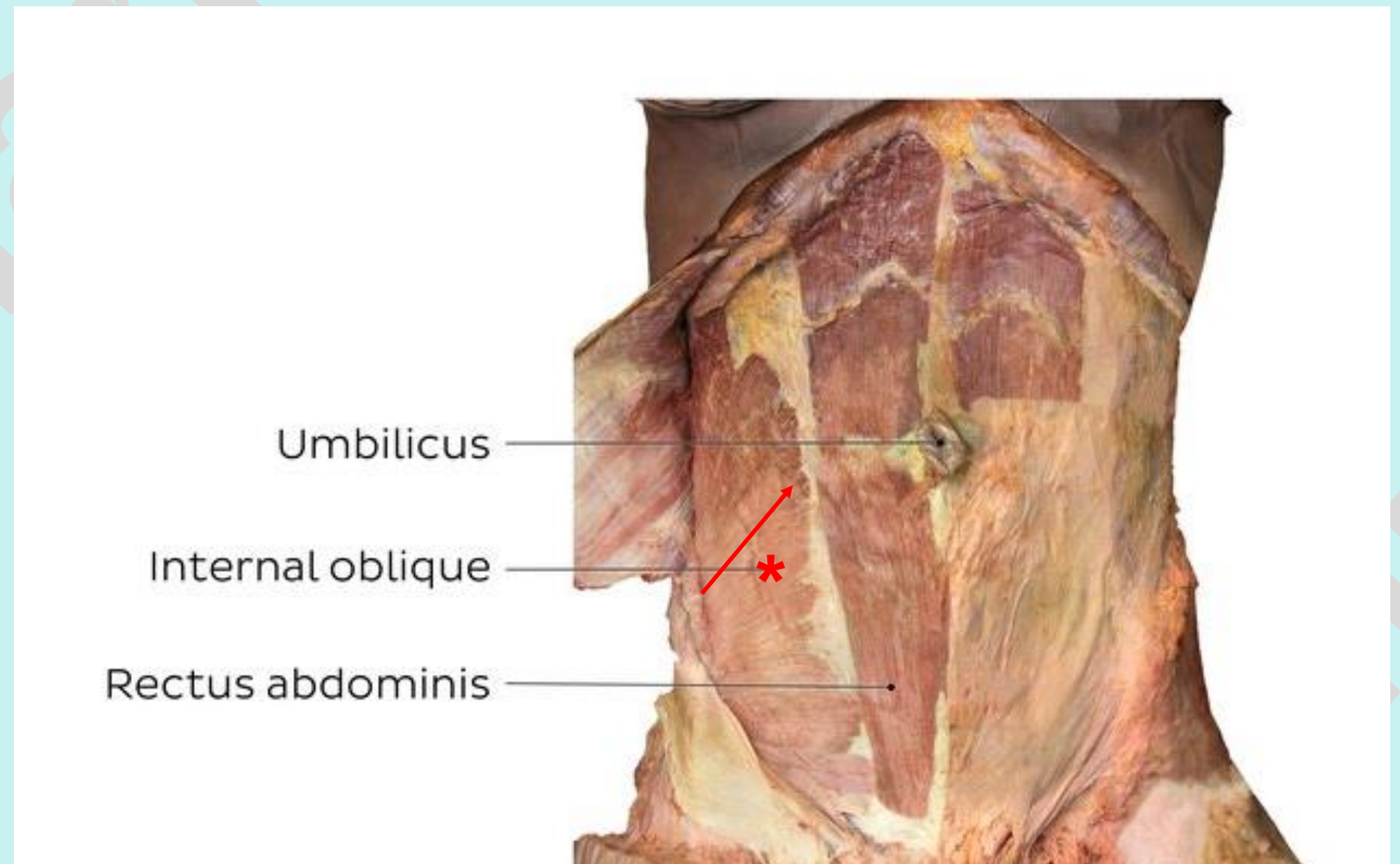
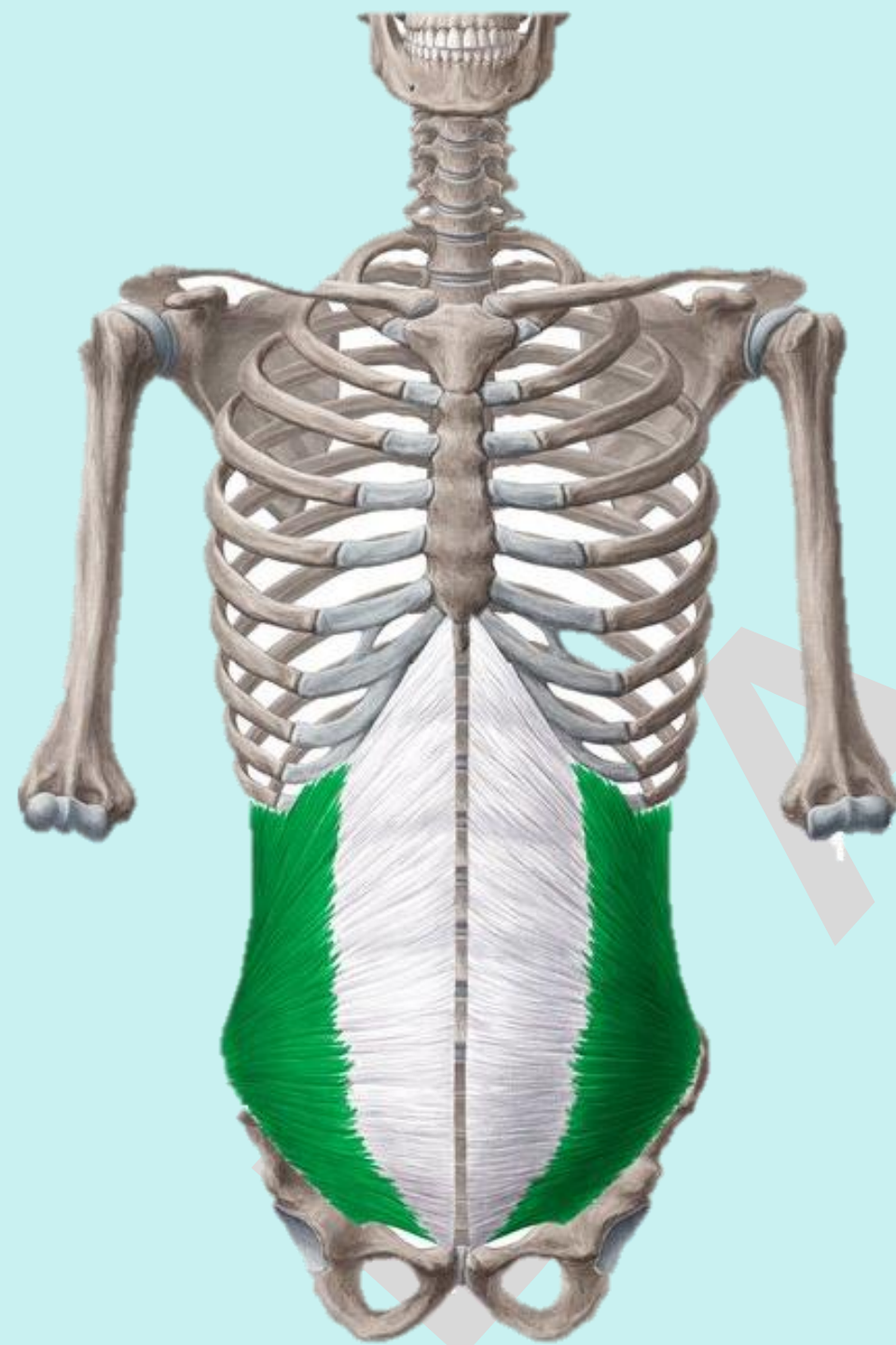


# Check List:

## Muscles of the Trunk

### Muscles of the Anterior Abdominal wall:

**2. Internal oblique:** identify the location, origin, insertion and action.

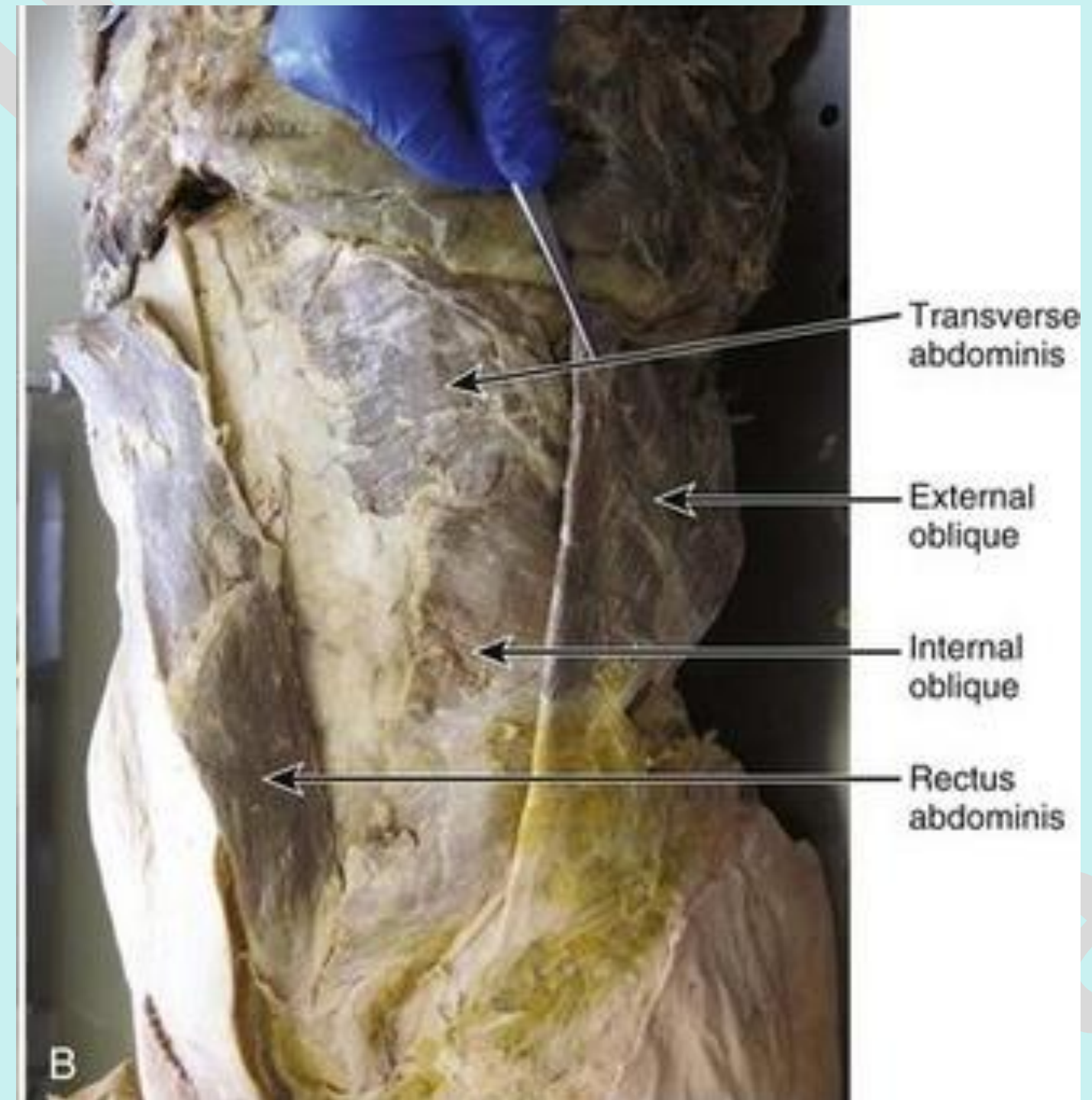
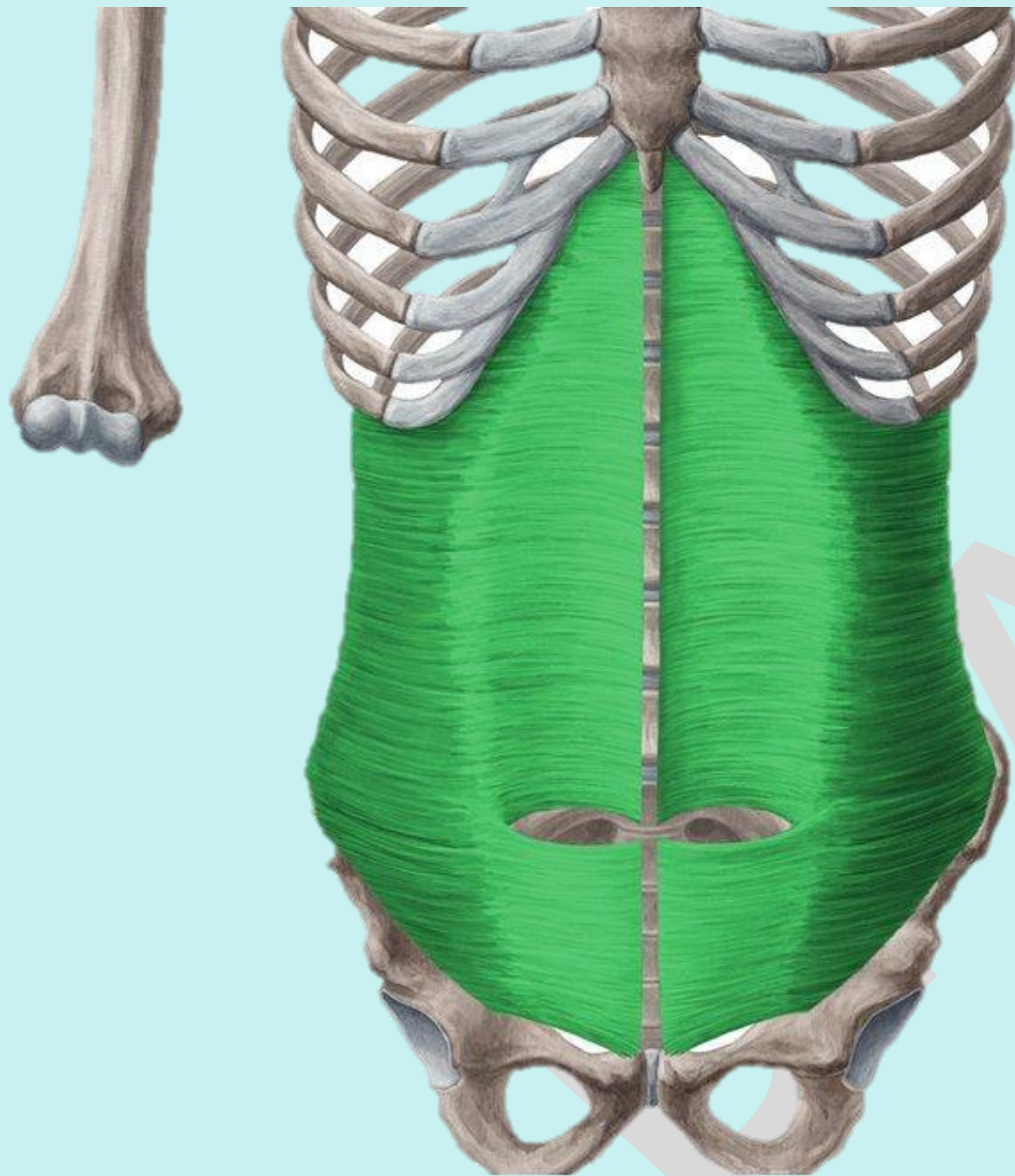


# Check List:

## Muscles of the Trunk

### Muscles of the Anterior Abdominal wall:

**3. Transversus Abdominis:** identify the location, origin, insertion and action.



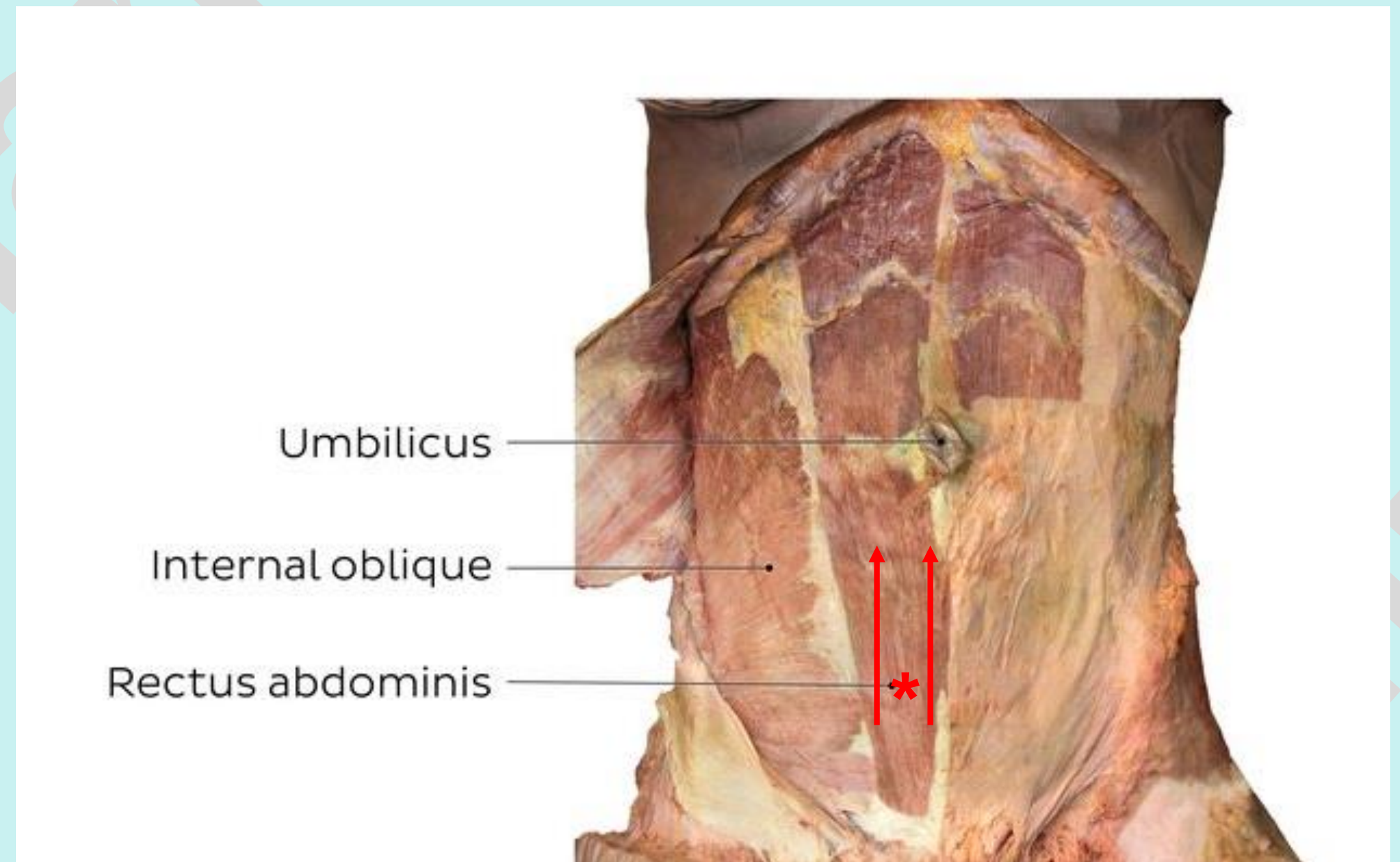
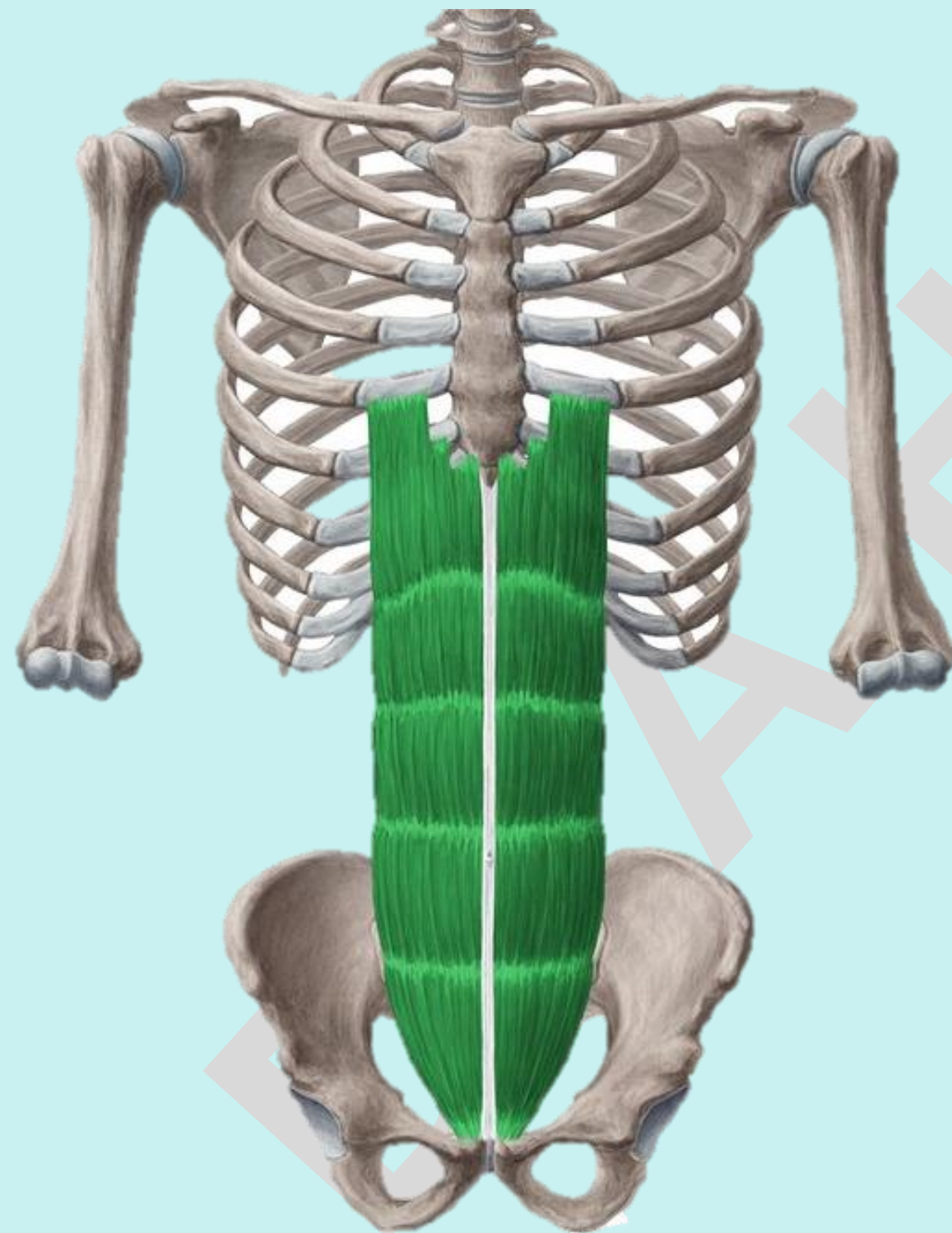
# Check List:

Practical Lab-9

## Muscles of the Trunk

### Muscles of the Anterior Abdominal wall:

4. **Rectus Abdominis** : identify the location, origin, insertion and action.

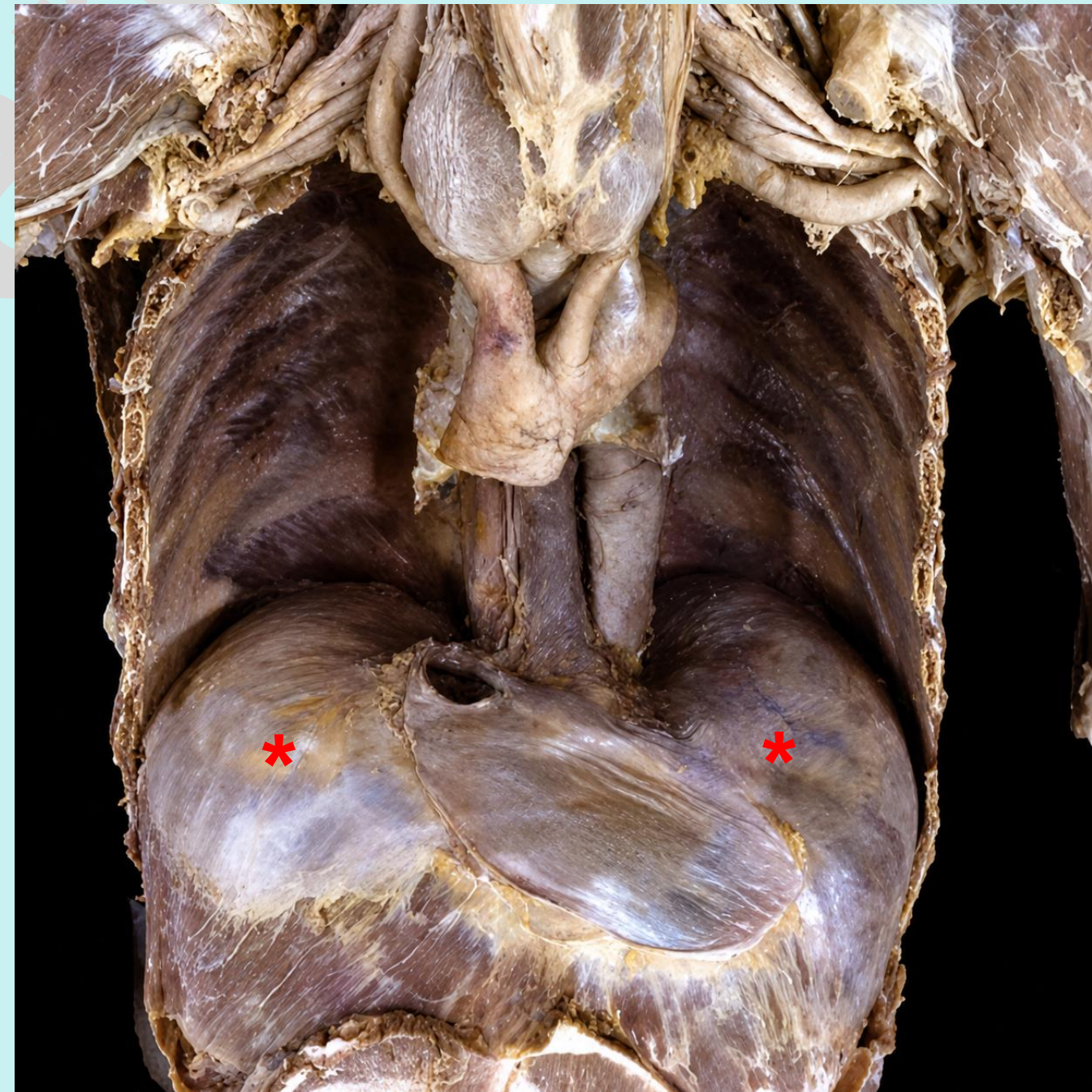
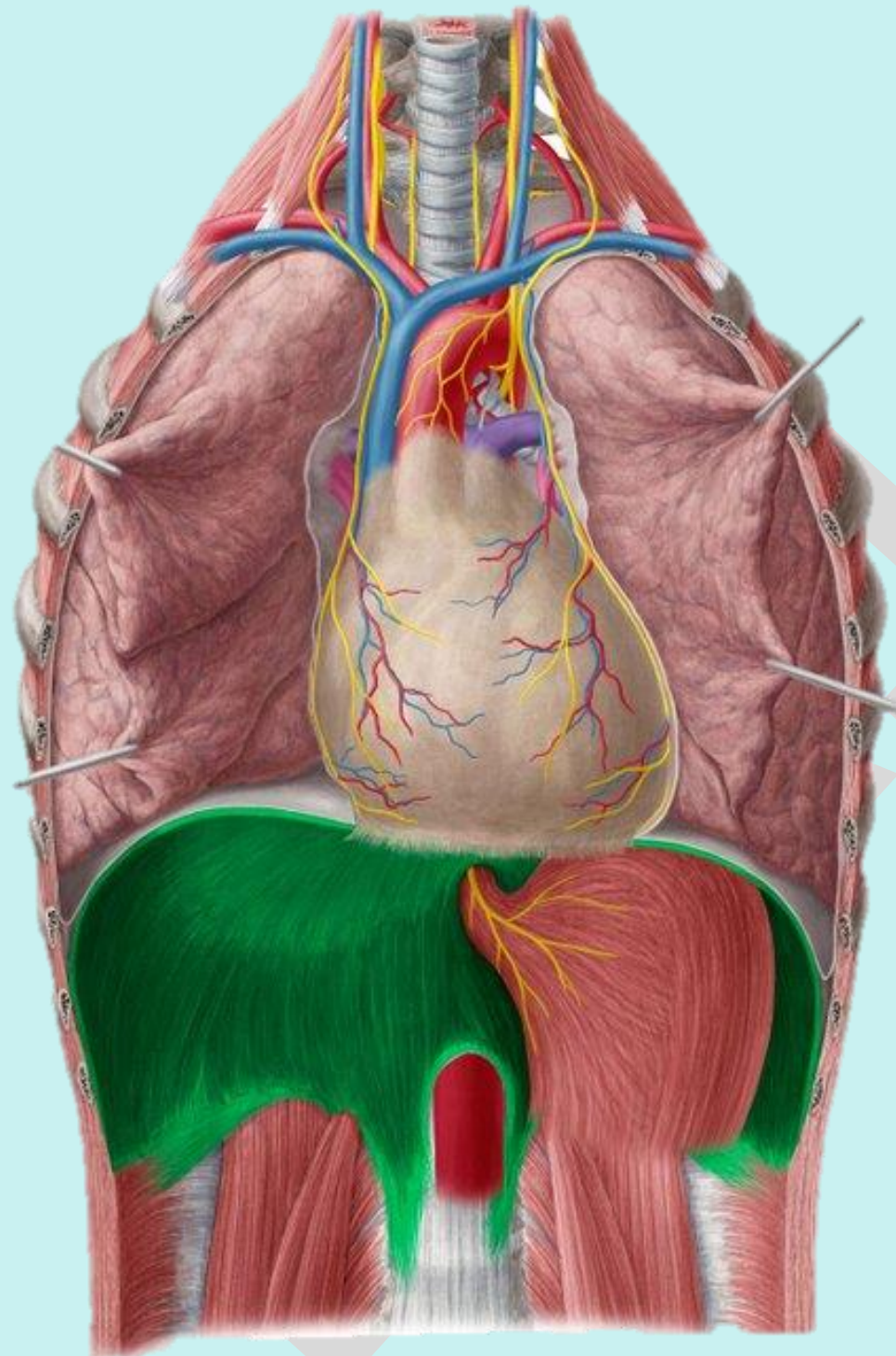


# Check List:

Practical Lab-9

## Muscles of the Trunk

Diaphragm identify the location, origin, insertion and action.



Dr A.Hamida