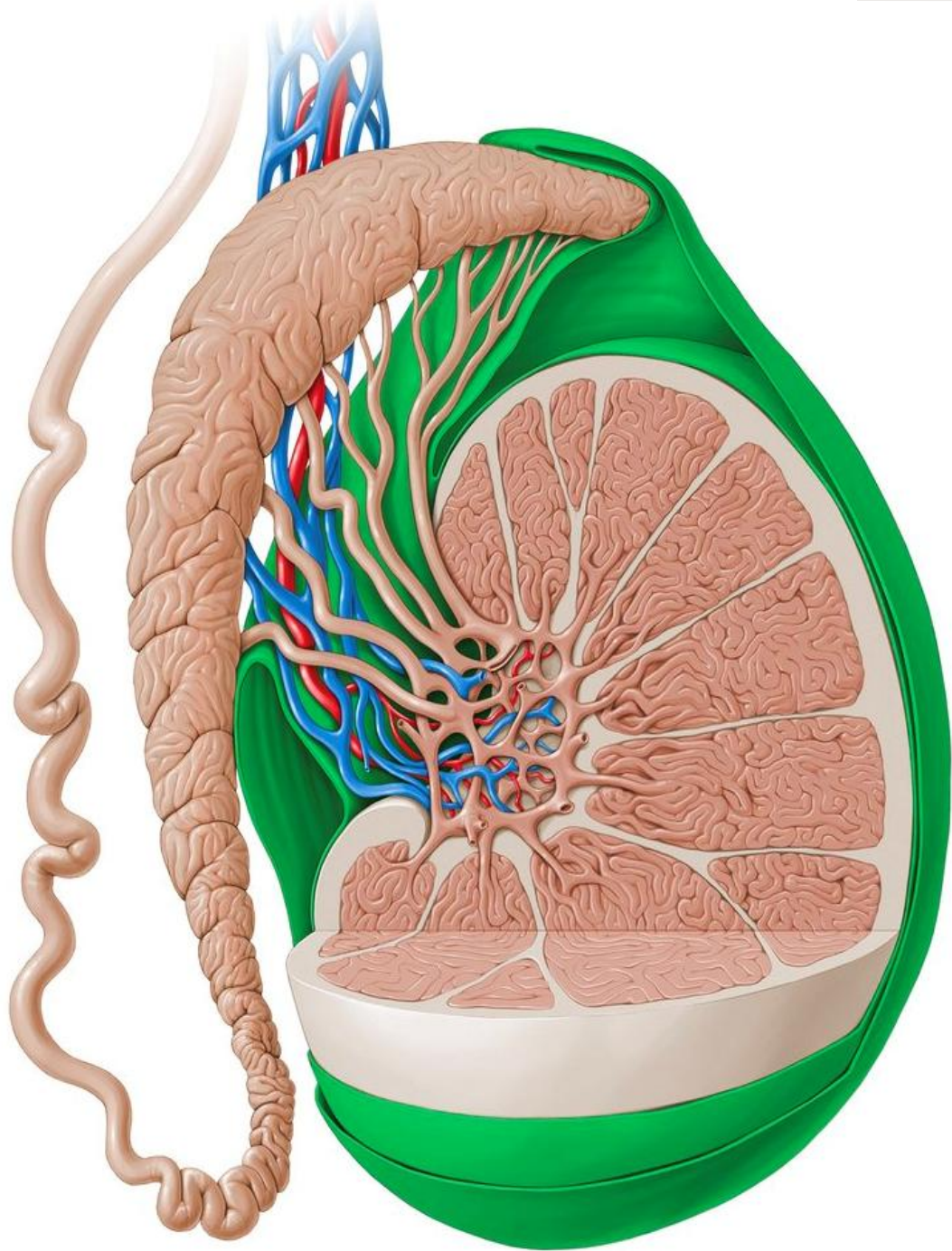




Male Reproductive System

Dr. Heba Kalbouneh
DDS, MSc, DMD/PhD
Professor of Anatomy, Histology and Embryology

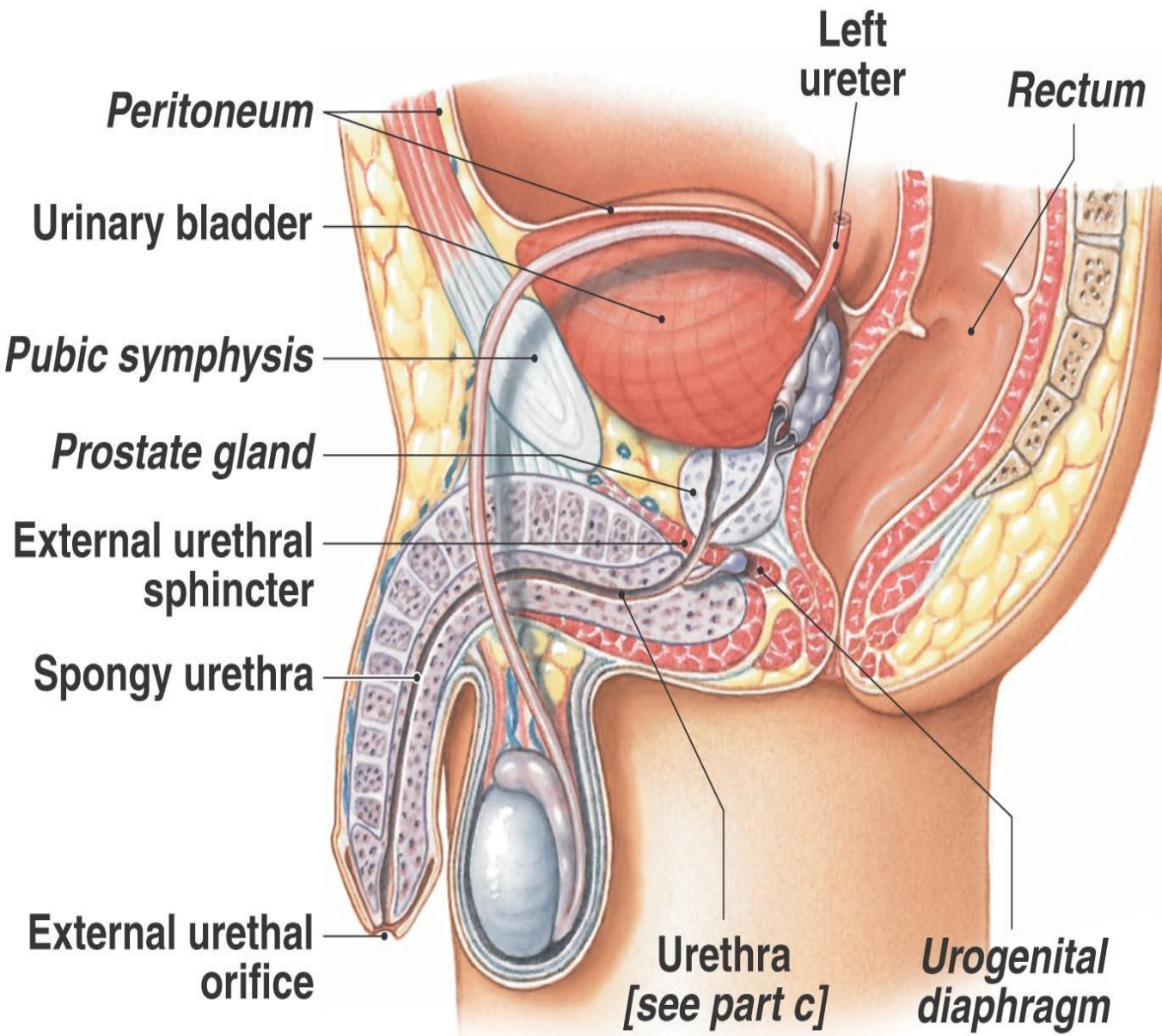
*Prepared and adapted for teaching by Prof. Dr. Heba Kalbouneh.
Illustrations adapted from multiple educational resources for educational purposes.
These slides are intended for students enrolled in this course and should not be
distributed without permission.*



Learning Objectives

By the end of this lecture, students should be able to:

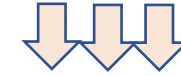
- Identify the main organs of the male reproductive system and describe their functions.
- Describe the microscopic structure of the testis and outline spermatogenesis.
- Explain the hormonal regulation of male reproduction (GnRH, FSH, LH, testosterone).
- Describe sperm maturation, transport, and semen composition.



(a) Male pelvis, sagittal section

The male reproductive system consists of the **testes**, **genital ducts**, **accessory glands**, and **penis**

Testis is a Mixed gland (Exocrine and Endocrine)



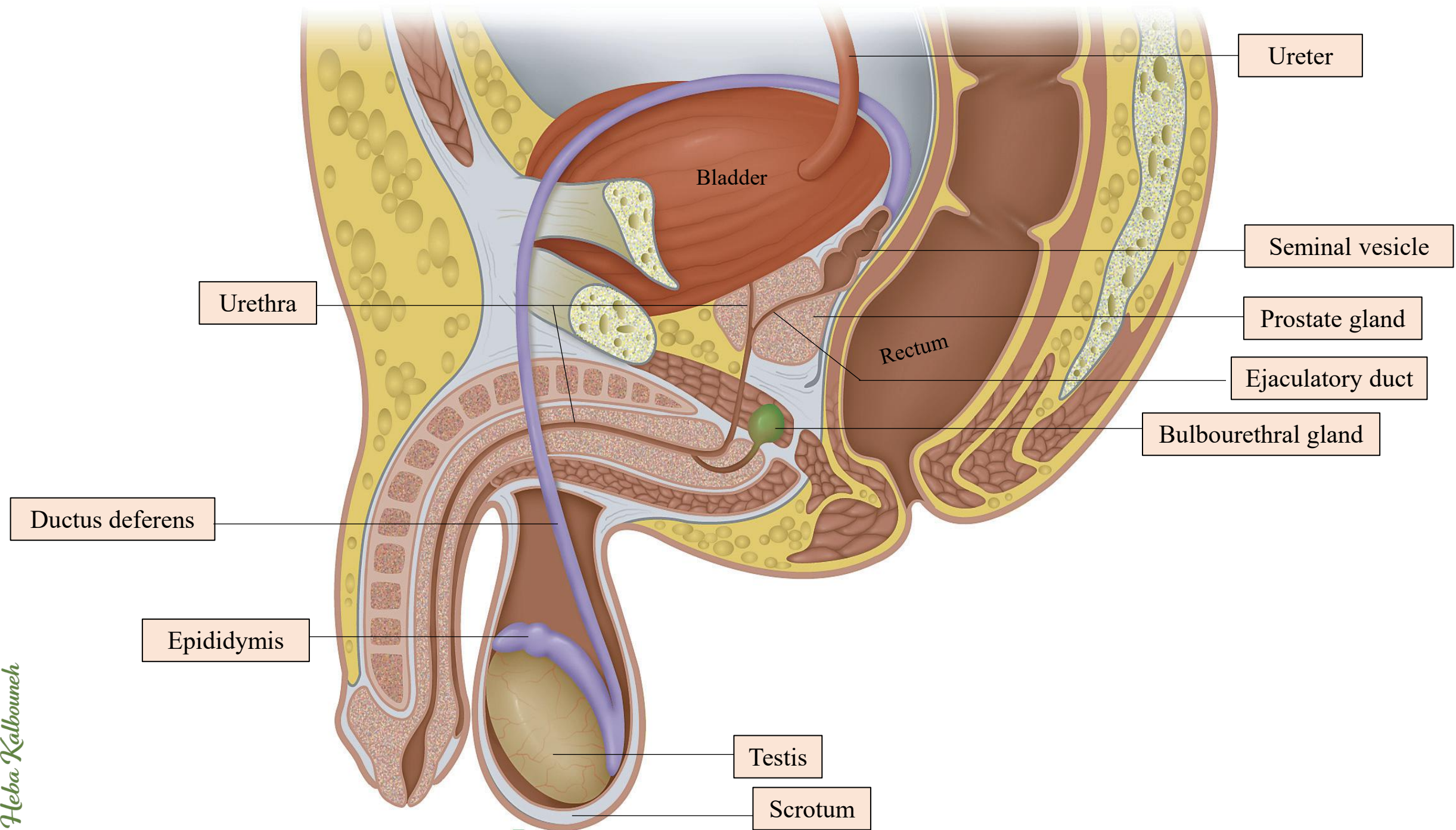
Testes produce sperm (*Exocrine*) but also contain endocrine cells secreting hormones such as testosterone (*Endocrine*)

The genital ducts and accessory glands produce secretions required for sperm activity

These secretions provide nutrients for spermatozoa while they are confined to the male reproductive tract.

Spermatozoa and the secretions of the accessory glands make up the **semen** (L. seed)

Testosterone promotes production of spermatozoa, secretion from the accessory sex glands, and acquisition of male secondary characteristics.



Parts of male reproductive system:

1. Testes

Produce sperm (spermatogenesis) and testosterone.

2. Epididymis

Site of sperm maturation, storage, and acquisition of motility.

3. Vas (ductus) deferens

Muscular tube that transports sperm from epididymis to ejaculatory duct.

4. Ejaculatory ducts

Formed by vas deferens + seminal vesicle duct; deliver semen into urethra.

5. Urethra

Common passage for semen and urine (in males).

6. Seminal vesicles

Secrete fructose-rich fluid → energy source; major volume of semen.

7. Prostate gland

Secretes alkaline fluid → enhances sperm motility and viability.

8. Bulbourethral (Cowper's) glands

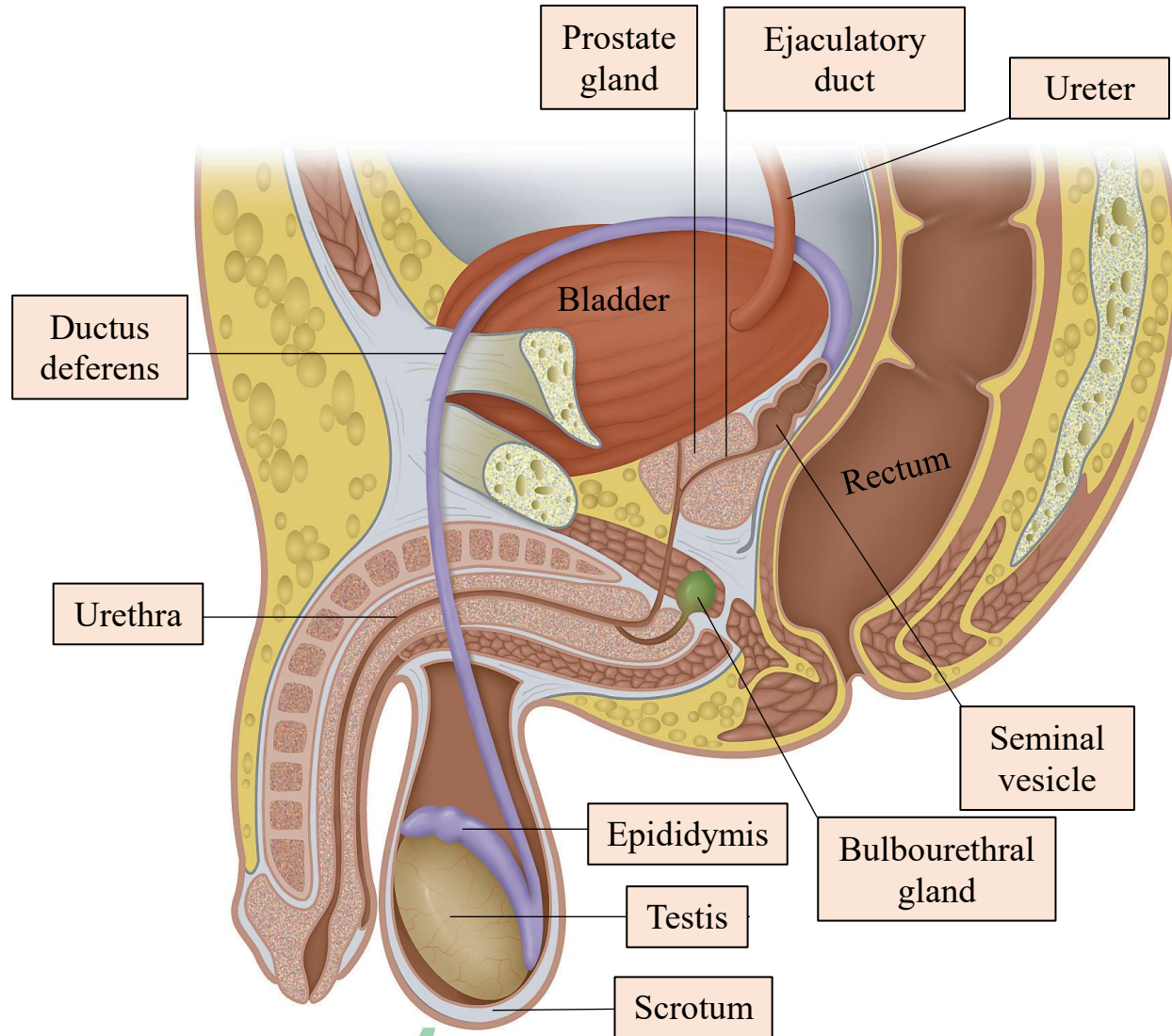
Secrete mucus → lubrication and neutralization of urethra.

9. Penis

Organ of copulation; delivers semen into female reproductive tract.

10. Scrotum

Skin sac that houses testes; regulates temperature for spermatogenesis.



Scrotum

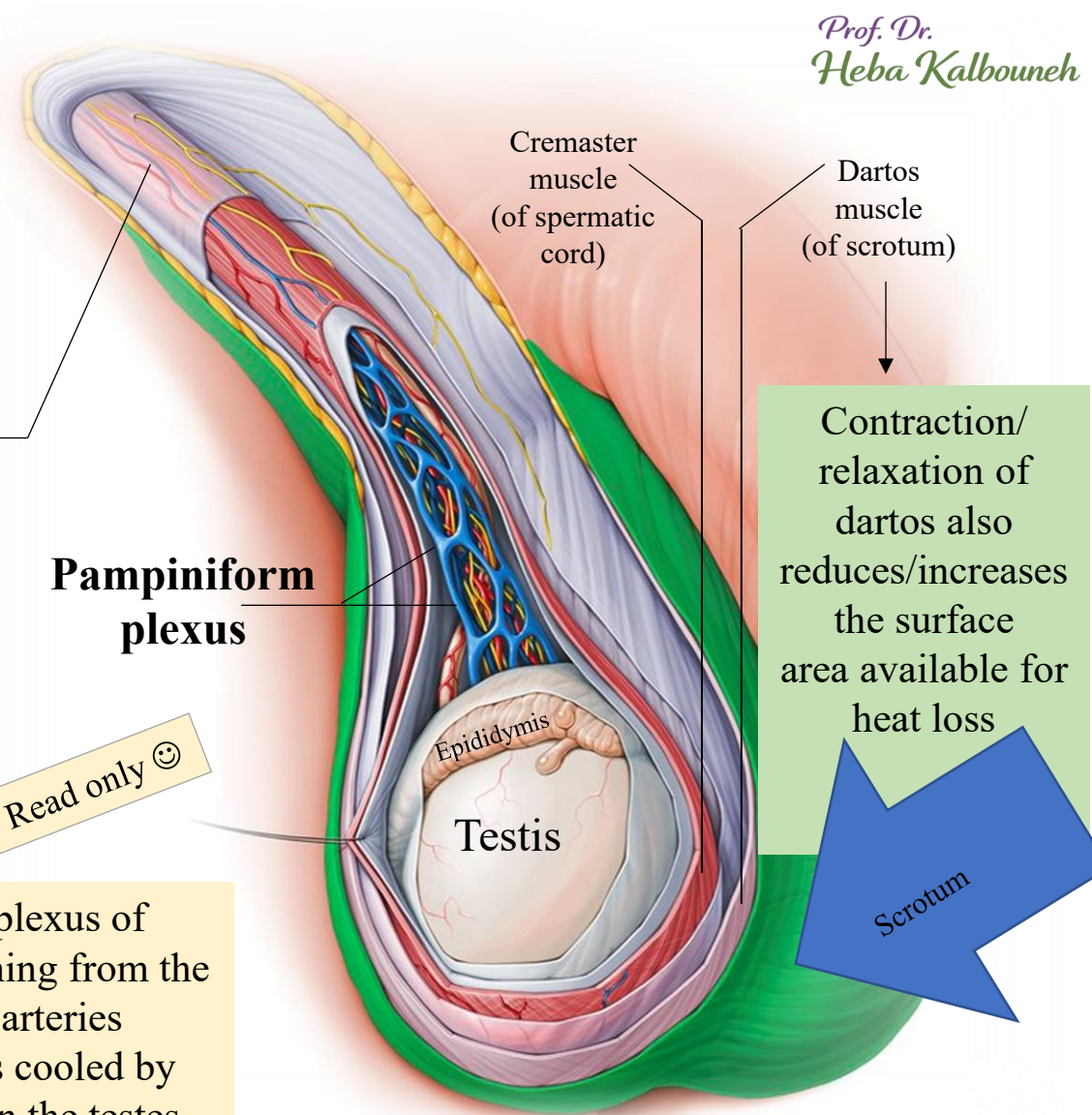
- ✓ The scrotum is a cutaneous fibromuscular sac composed of thin, pigmented skin and multiple layers of fascia and smooth muscle.
- ✓ The structures contained in the scrotal sac are the testes, epididymis, and lower parts of the spermatic cord.
- ✓ The testis is suspended in the scrotum by the **spermatic cord**.
- ✓ The function of the scrotum is to allow the testis to be positioned outside of the body.
- ✓ This is fundamental for maintaining the optimal temperature for spermatogenesis, which is several degrees below the normal body temperature.

A temperature of about 34°C is maintained in the scrotal sac by various mechanisms:

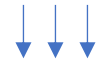

- 1- Testicular arteries that descend into the scrotum are surrounded by a complex plexus of veins that ascend from the testes and form the **pampiniform plexus**. Blood returning from the testes in the pampiniform plexus is cooler than the blood flowing in the testicular arteries toward the testes. By a countercurrent heat-exchange mechanism, arterial blood is cooled by venous blood before it enters the testes, helping to maintain a lower temperature in the testes.
- 2- Evaporation of sweat from the skin of scrotum contributes to heat loss.
- 3- Relaxation or contraction of the thin dartos muscle and the cremaster muscle move the testes away from or closer to the body, respectively, allowing further control on testicular temperature.

Read only 😊



A **varicocele** is an abnormal enlargement of the pampiniform venous plexus in the scrotum



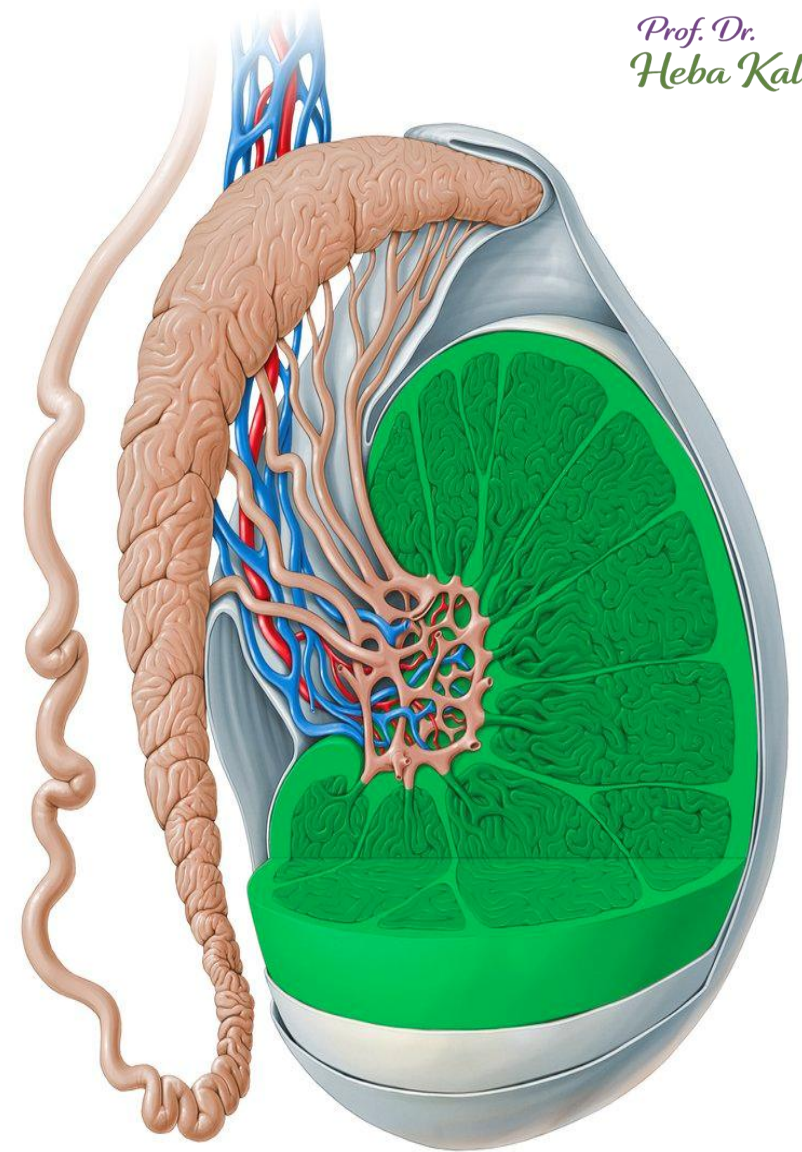
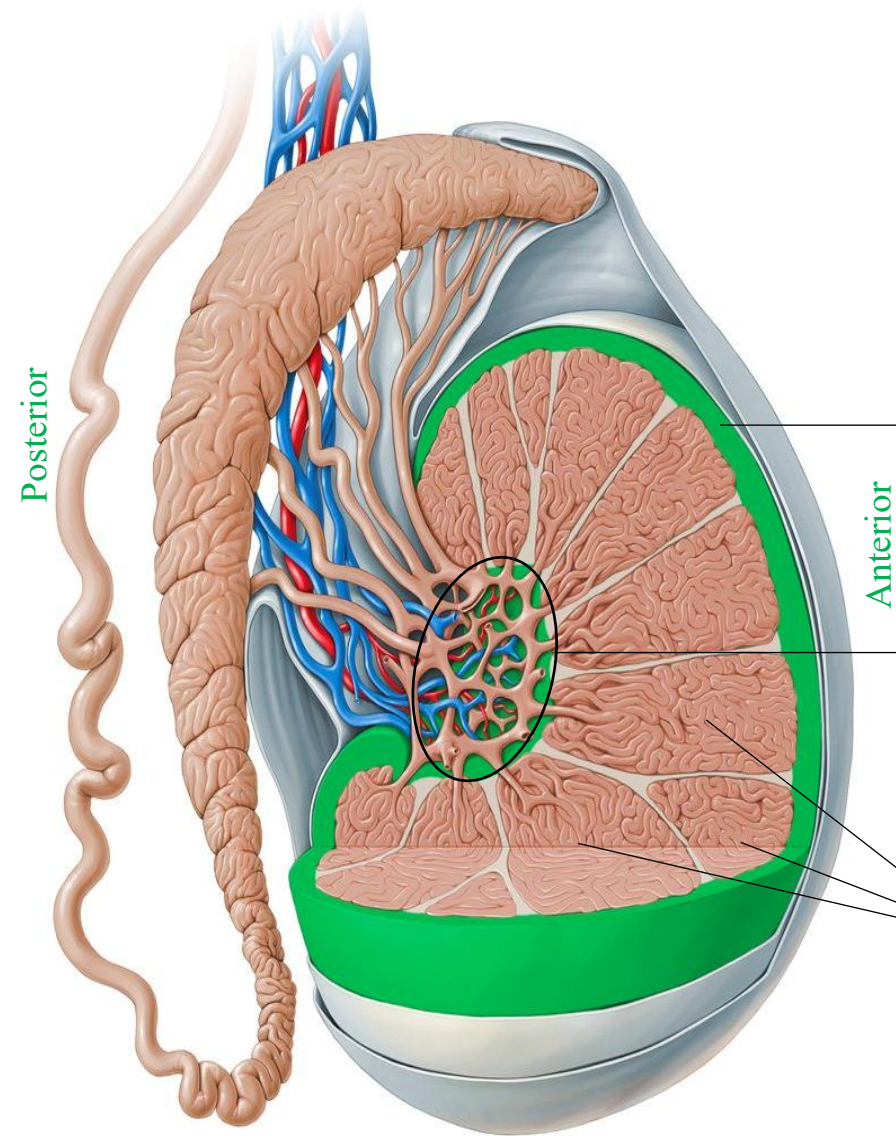
This condition can have an effect on fertility

Testes

Each testis (or testicle) is surrounded by a dense connective tissue capsule, the **tunica albuginea** (*White*)

The tunica albuginea thickens on the posterior side to form the **mediastinum testis**.

A thin connective tissue septum extends from the mediastinum testis and subdivides each testis into about 250 incomplete lobules (**testicular lobules**)



Each lobule contains:

- 1- **One to four** highly convoluted **seminiferous tubules**: in which sperm production occurs.
- 2- **Leydig cells** (Endocrine interstitial cells): secreting testosterone.

The testes develop retroperitoneally in the dorsal wall of the embryonic abdominal cavity and are moved during fetal development to become suspended in the two halves of the scrotal sac (scrotum), at the ends of the spermatic cords.

!!!Sperm formation cannot occur at the core body temperature of 37°C

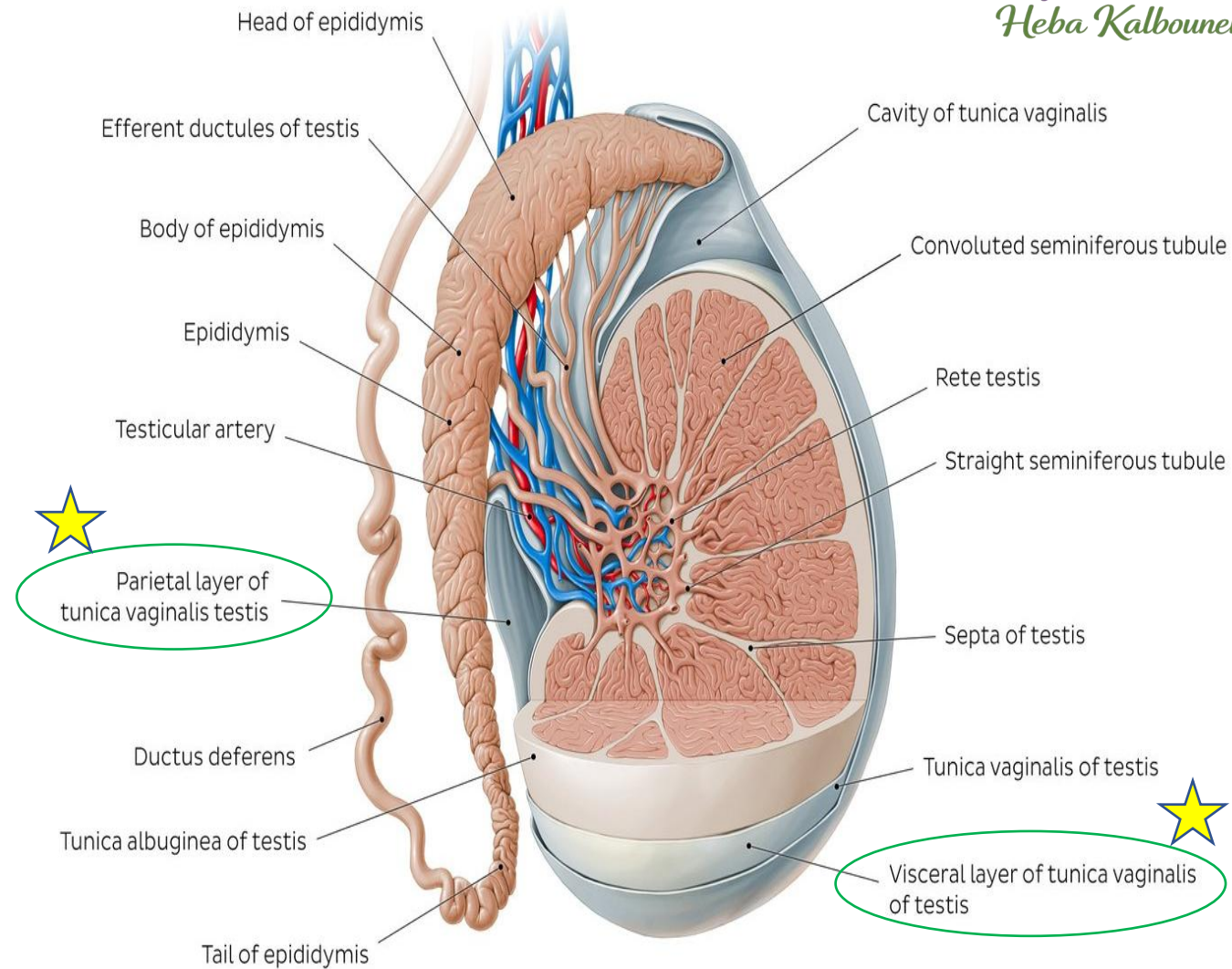
During migration from the abdominal cavity, each testis carries with it a serous sac, **the tunica vaginalis**, derived from the peritoneum.

The **tunica vaginalis** consists of: ★

- 1- an **outer parietal layer**: lining the scrotum
- 2- an **inner visceral layer**: covering the tunica albuginea on the anterior and lateral sides of the testis



A hydrocele: An excessive accumulation of serous fluid in one or both sides of the scrotal sac



Cryptorchidism (Gr. kryptos, hidden + orchis, testis): the failure of one or both testes to descend from the abdomen, occurs in about 4% of male neonates, but in most of these individuals the testes move to the scrotum during the first year.

Seminiferous tubules

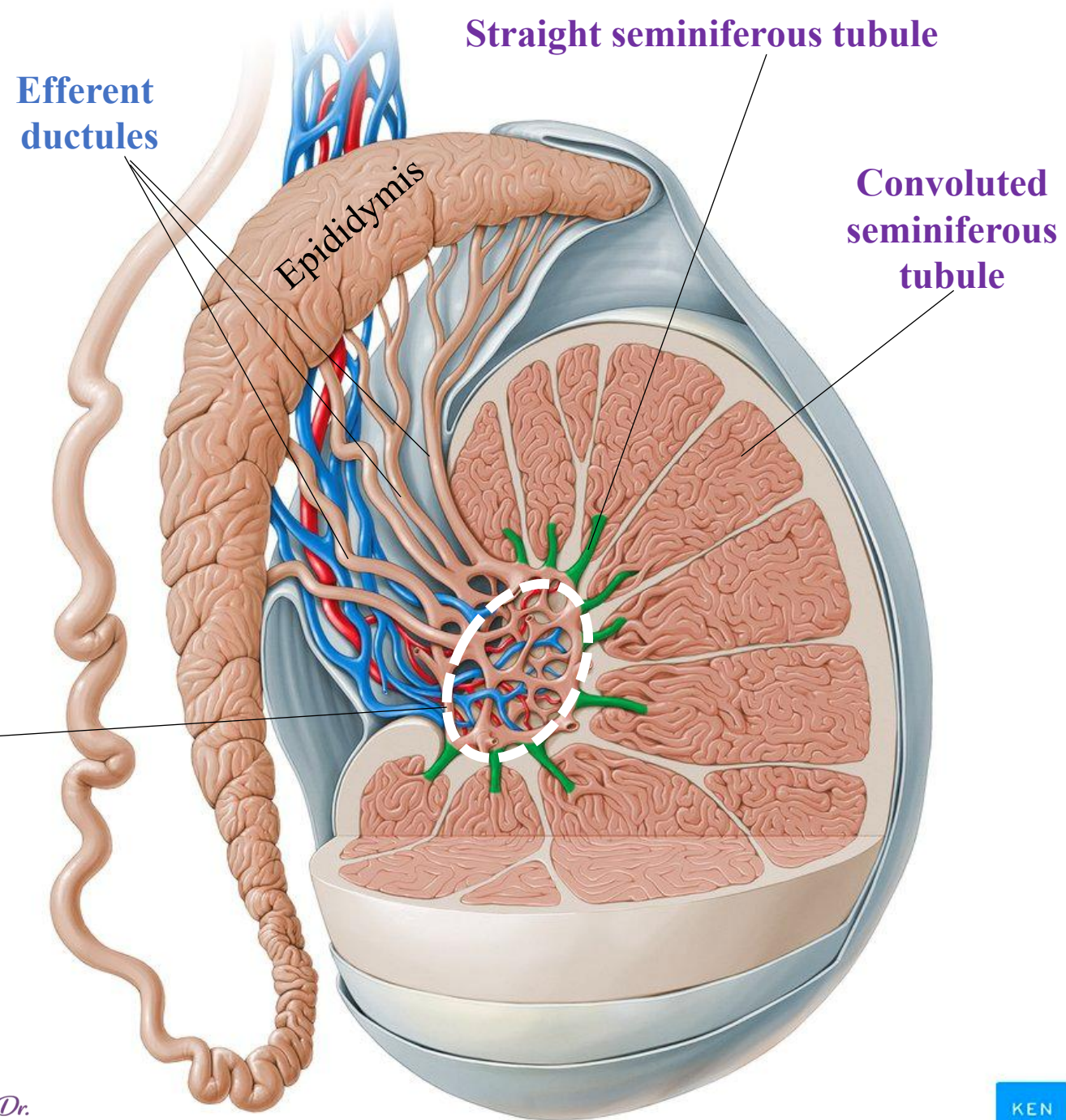
- ✓ Sperms are produced in the seminiferous tubules at a rate of about 2×10^8 per day in the young adult.
- ✓ Each testis has from 250 to 1000 tubules in its lobules
- ✓ Each tubule measures about $200 \mu\text{m}$ in diameter and about 50 cm in length.
- ✓ The combined length of the tubules of one testis totals about 250 m. !!

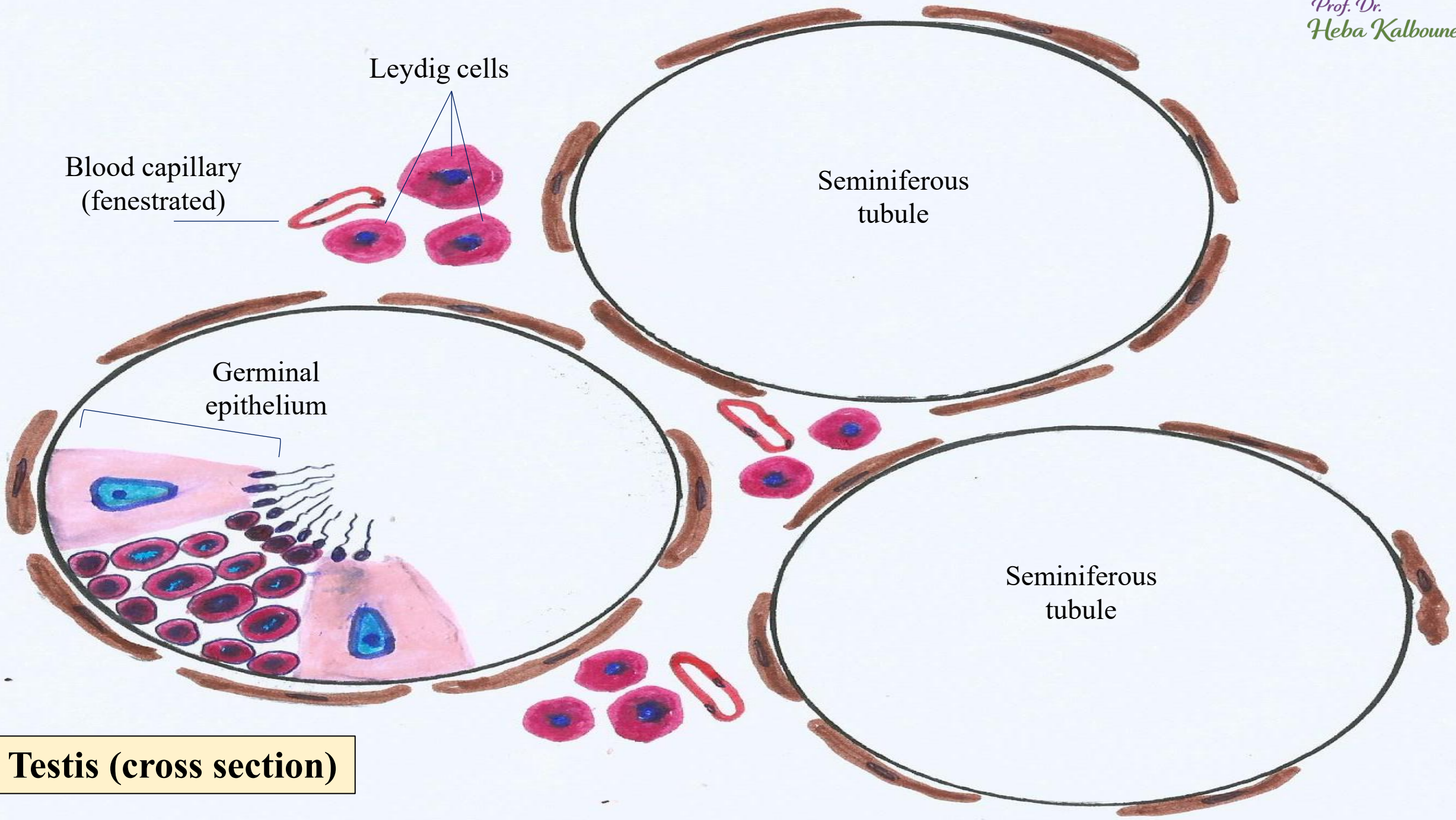
Convolut ed seminiferous tubules: are twisted curved tubules where spermatogenesis occurs

Straight seminiferous tubules: are the short straight tubules between the convoluted seminiferous tubules and rete testis

The **rete testis:** anastomosing delicate tubules embedded in the mediastinum testis that carries sperm from the seminiferous tubules to the **efferent ductules**

About 10-20 efferent ductules connect the rete testis to the head of the epididymis





Blood capillary
(fenestrated)

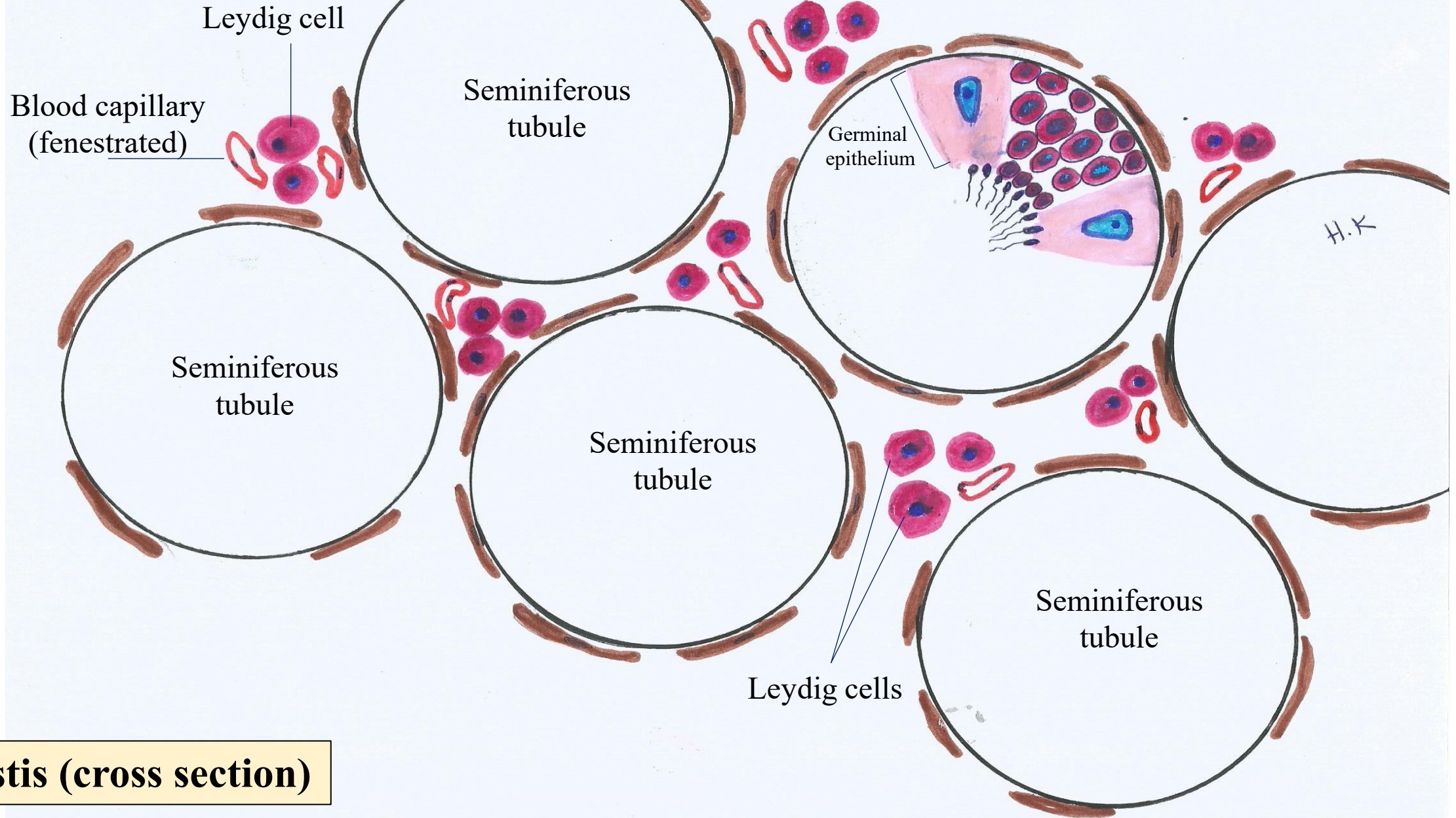
Leydig cells

Seminiferous
tubule

Germinal
epithelium

Seminiferous
tubule

Testis (cross section)



Testis (cross section)

Spermatogonium



Primary
spermatocyte



Secondary
spermatocyte



Spermatid



Mature spermatozoa



Spermiogenesis

The *final phase* of spermatogenesis in which haploid spermatids differentiate into mature spermatozoa.



Spermatogenesis

The *entire process* by which diploid spermatogonia develop into haploid spermatozoa.

Spermatogonium

Sertoli cell



Before Puberty (Pre-pubertal Testis)

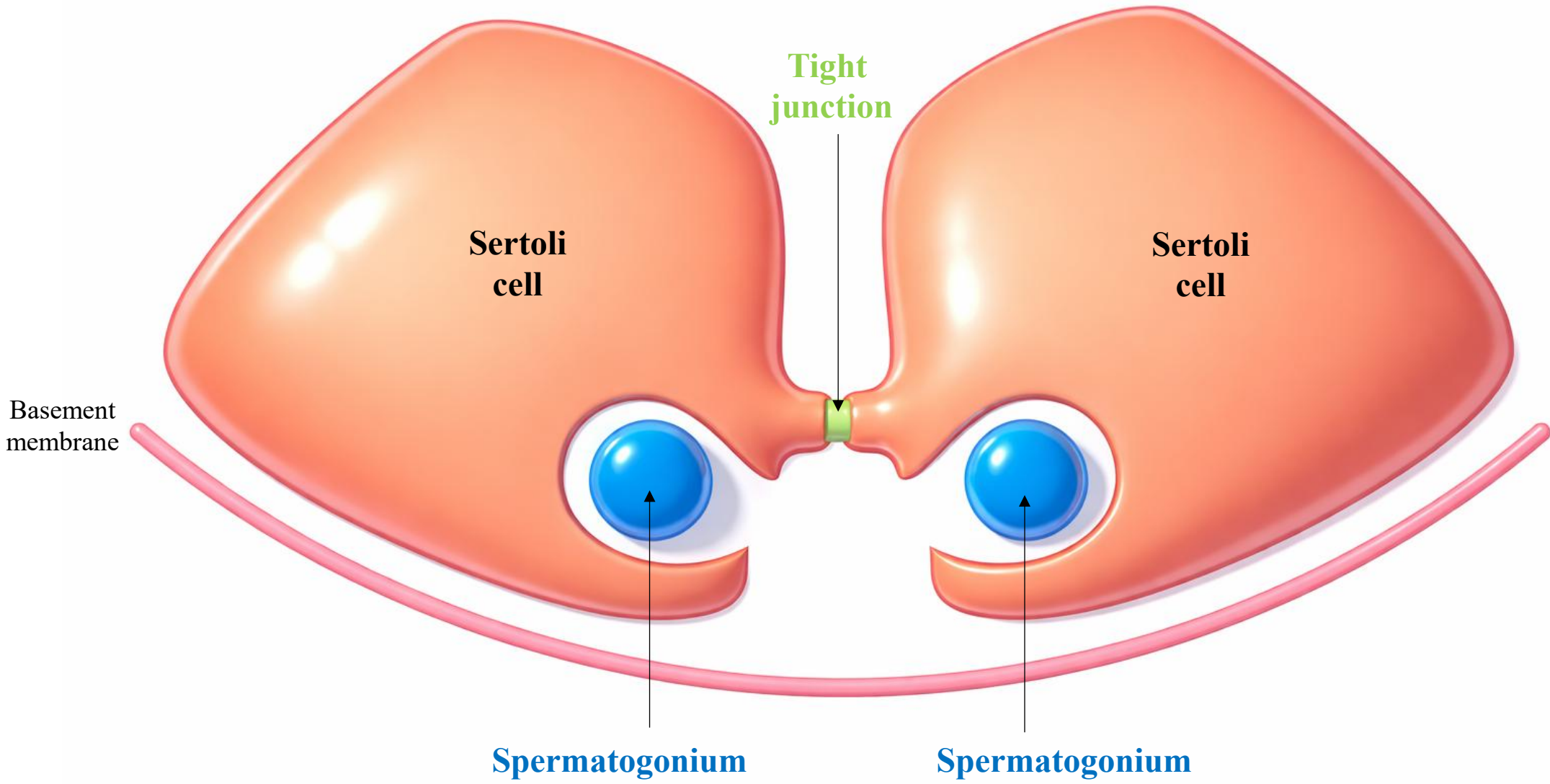
- Tubules appear as solid seminiferous cords
 - No lumen
 - Lined mainly by:
 - Primitive Sertoli cells
 - Spermatogonia
 - No active spermatogenesis
 - Small diameter
 - Interstitial Leydig cells present but hormonally inactive
- These are technically "seminiferous cords" because lumen formation has not yet occurred.*

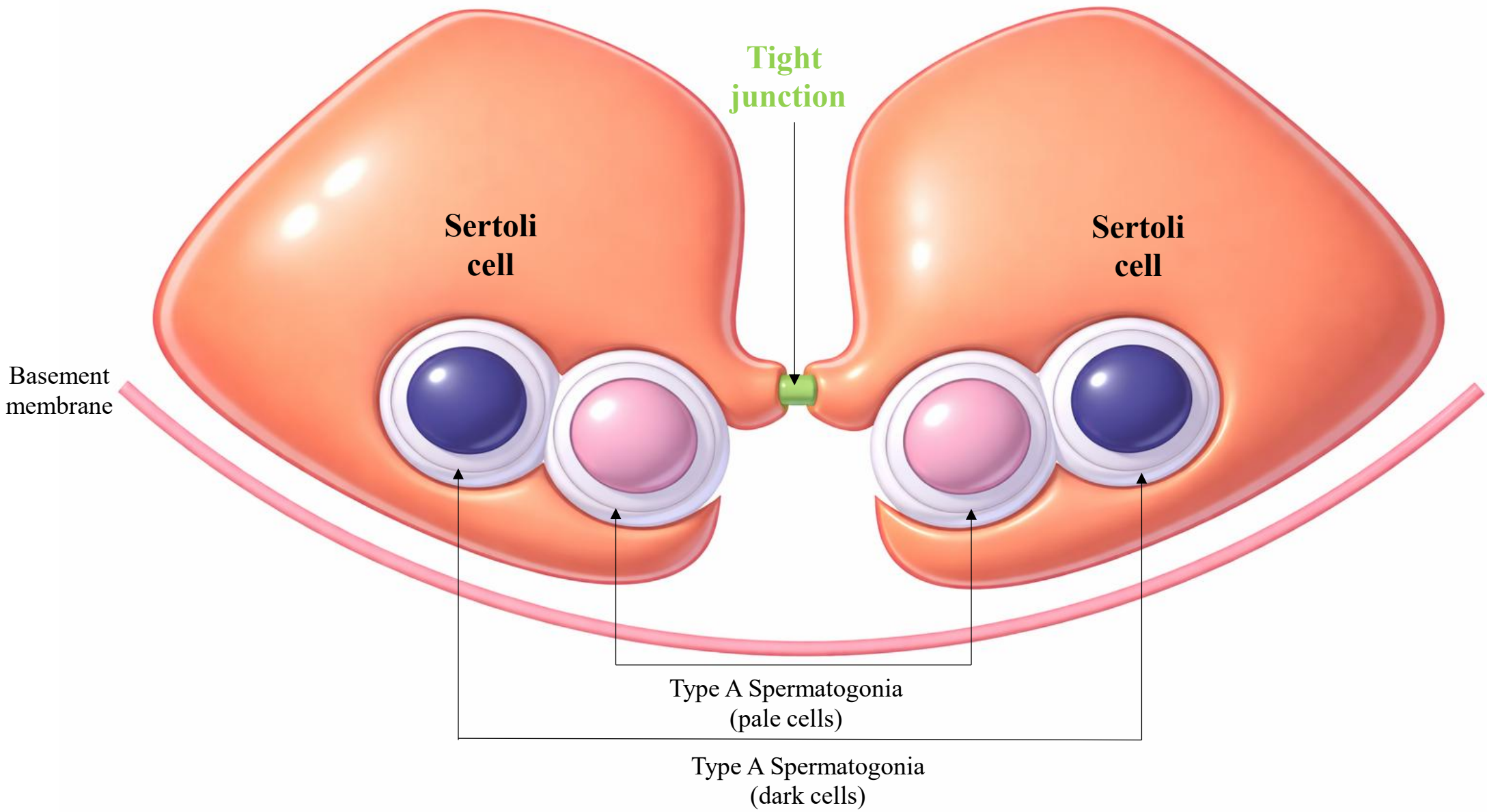
Tight junction



After Puberty (Adult Testis)

- True seminiferous tubules with a clear central lumen
 - Markedly increased diameter
 - Stratified germinal epithelium containing:
 - Spermatogonia
 - Primary & secondary spermatocytes
 - Spermatids
 - Spermatozoa
 - Active spermatogenesis
 - Prominent Sertoli cells
 - Interstitial Leydig cells enlarged and hormonally active
- Lumen formation → initiation of spermatogenesis and rising testosterone levels.*





Basement membrane

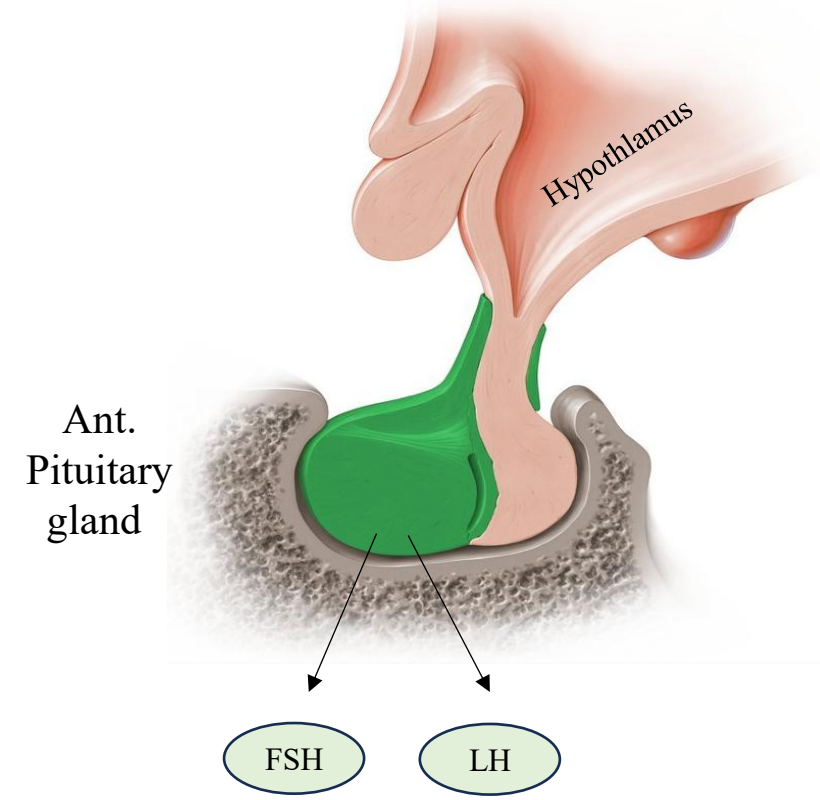
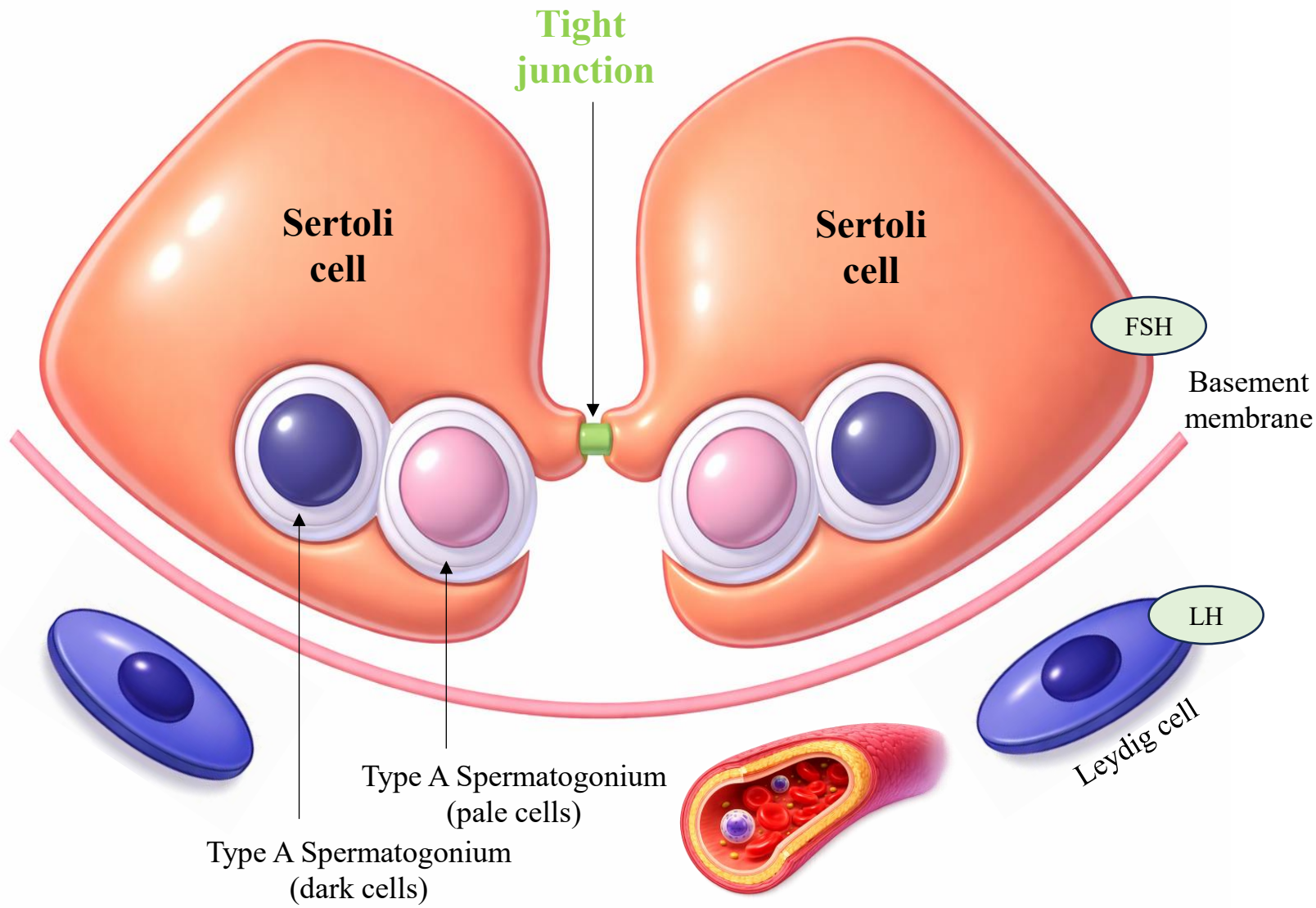
Sertoli cell

Sertoli cell

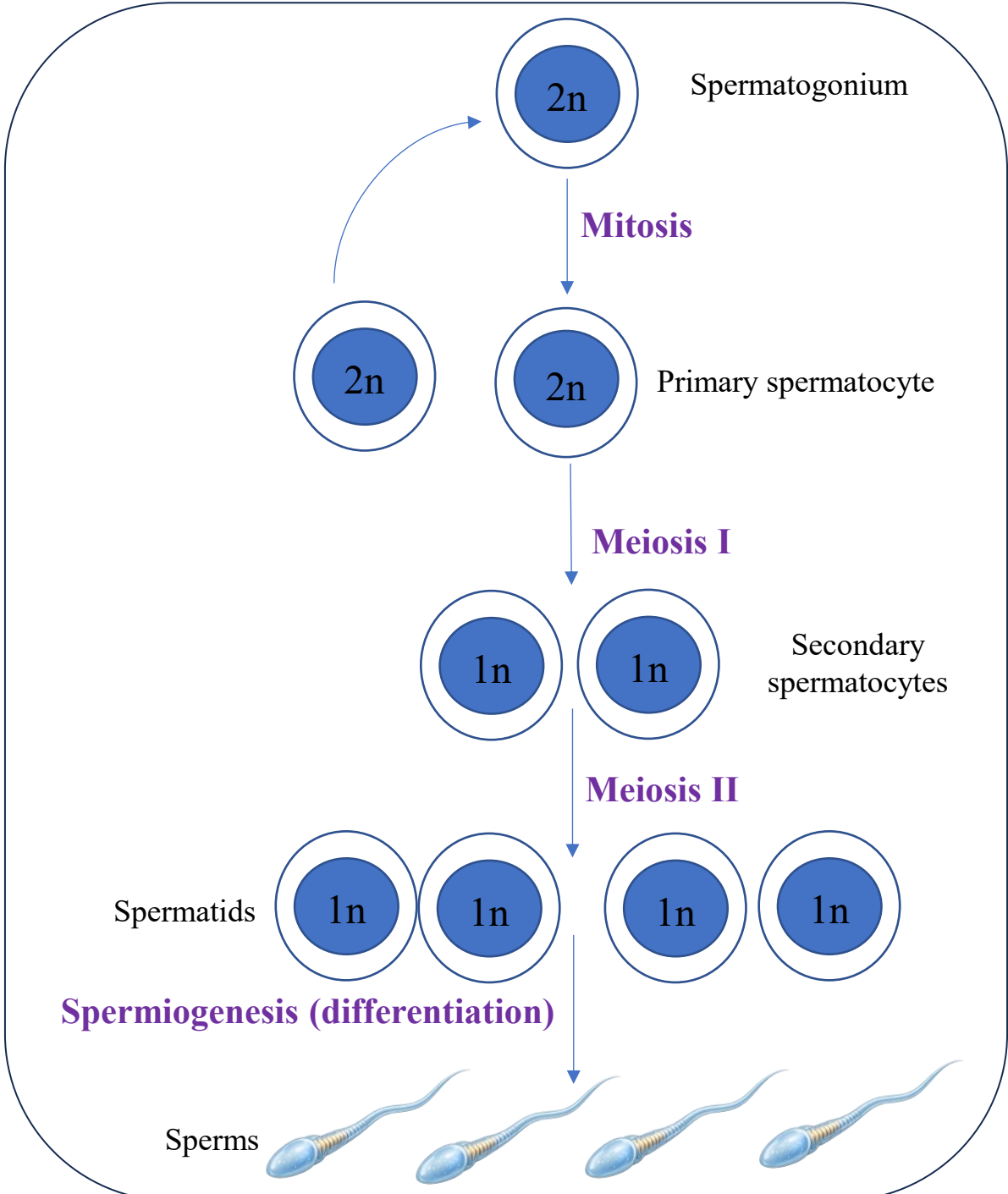
Tight junction

Type A Spermatogonia (pale cells)

Type A Spermatogonia (dark cells)



Spermatogenesis



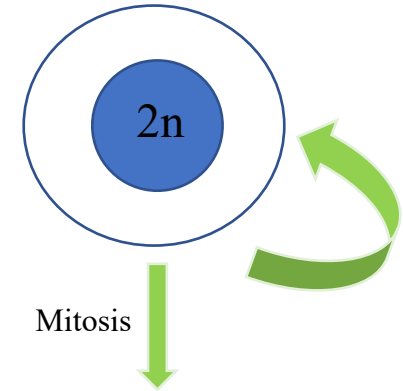
- ✓ The process of sperm formation is called **spermatogenesis**.
- ✓ Spermatogenesis begins at puberty with proliferation of stem and progenitor cells called spermatogonia (Unlike their female counterparts)
- ✓ A **spermatogonium** (plural: spermatogonia) is an undifferentiated male germ cell.
- ✓ Spermatogonia undergo spermatogenesis to form mature spermatozoa in the seminiferous tubules of the testis.
- ✓ There are three subtypes of spermatogonia in humans:

Type A Spermatogonia (dark cells): Reserve stem cells that divide infrequently. They serve as a stem cell pool and can give rise to both Type A dark and Type A pale spermatogonia. (*Reserve stem cells*)

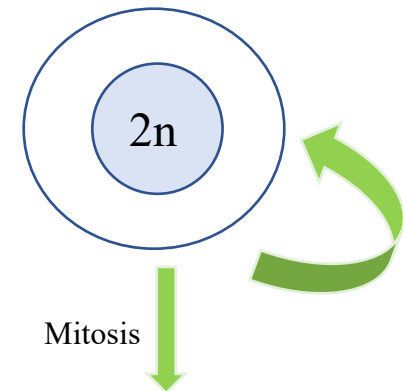
Type A Spermatogonia (pale cells): Actively dividing stem cells. They undergo frequent mitosis and produce Type B spermatogonia. (*Actively proliferating stem cells*)

Type B Spermatogonia: Undergo a final mitotic division. The daughter cells grow and differentiate into primary spermatocytes, which then enter meiosis I. (*Last mitotic generation before meiosis/ progenitor cell*)

Type A Spermatogonia (dark cells)

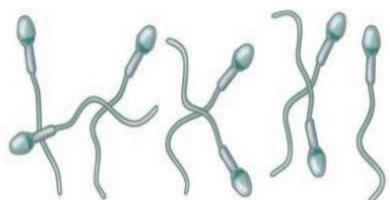


Type A Spermatogonia (pale cells)



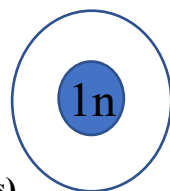
Note: The total production time for mature human spermatozoa is 74 days

Mature spermatozoa



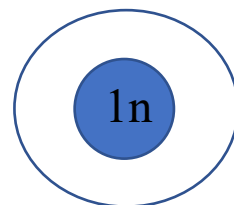
Metamorphosis
(Spermiogenesis)

Spermatid



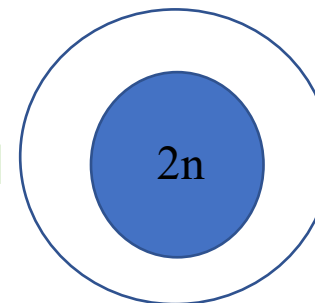
Meiosis II

Secondary spermatocyte



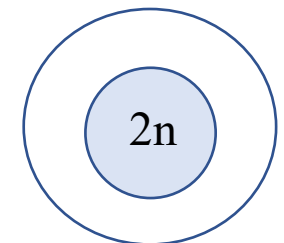
Meiosis I

Primary spermatocyte



Mitosis
Growth

Type B Spermatogonia



- ✓ The Primary spermatocytes undergo the meiosis I to produce secondary spermatocytes.
- ✓ The Secondary spermatocytes complete meiosis II and produce round spermatids.

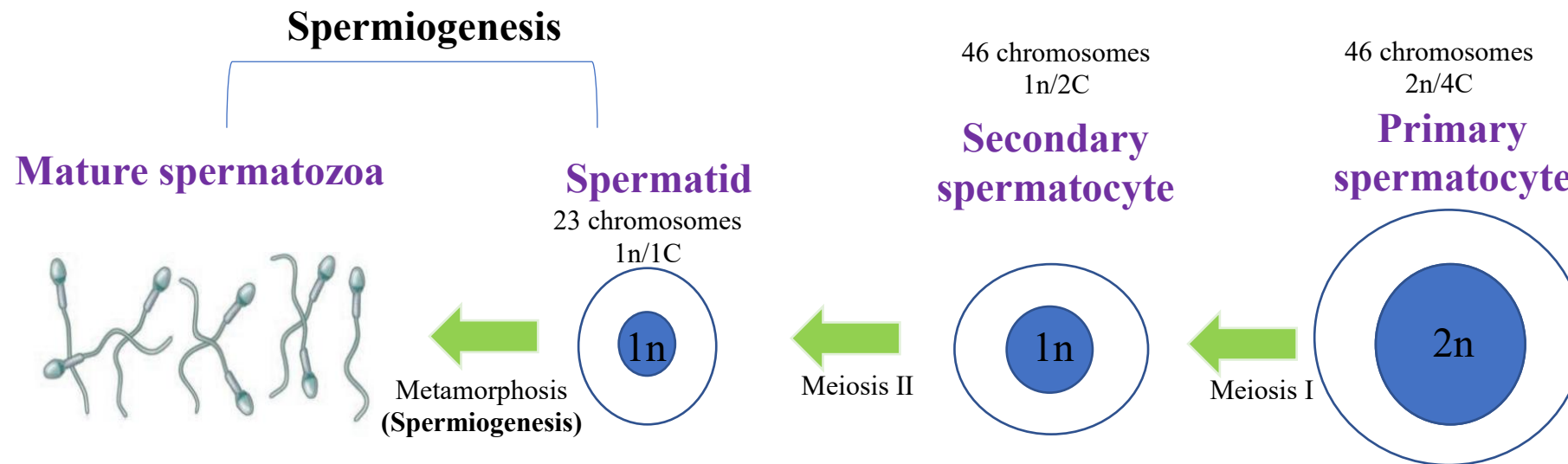
During these meiotic divisions, there is a reduction in the number of chromosomes and the amount of DNA in each cell.

- ✓ After the completion of meiosis II, the spermatids now contain 23 single chromosomes (22 + X or 22 + Y).
- ✓ Spermatids do not undergo any further divisions, but instead undergo extensive morphologic transformation. **Spermiogenesis** is a morphologic process by which the spherical spermatids are transformed into elongated sperm cells (spermatozoa).

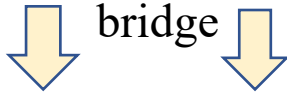Upon fertilization of the egg by the sperm, the total normal number of chromosomes is restored to 46.

Remember !!
The production of sperm and eggs/ova (gametes) is a procedure called **gametogenesis** (spermatogenesis and oogenesis). Gametogenesis involves two rounds of meiosis, in which one diploid cell gives rise to 4 haploid cells.

Thus, the primary spermatocyte gives rise to two cells, the secondary spermatocytes, and the two secondary spermatocytes by their subdivision produce four spermatozoa (four haploid cells)



In males, the cell division is incomplete and spermatocytes retain a cytoplasmic



Note: cells interconnected as a **syncytium**

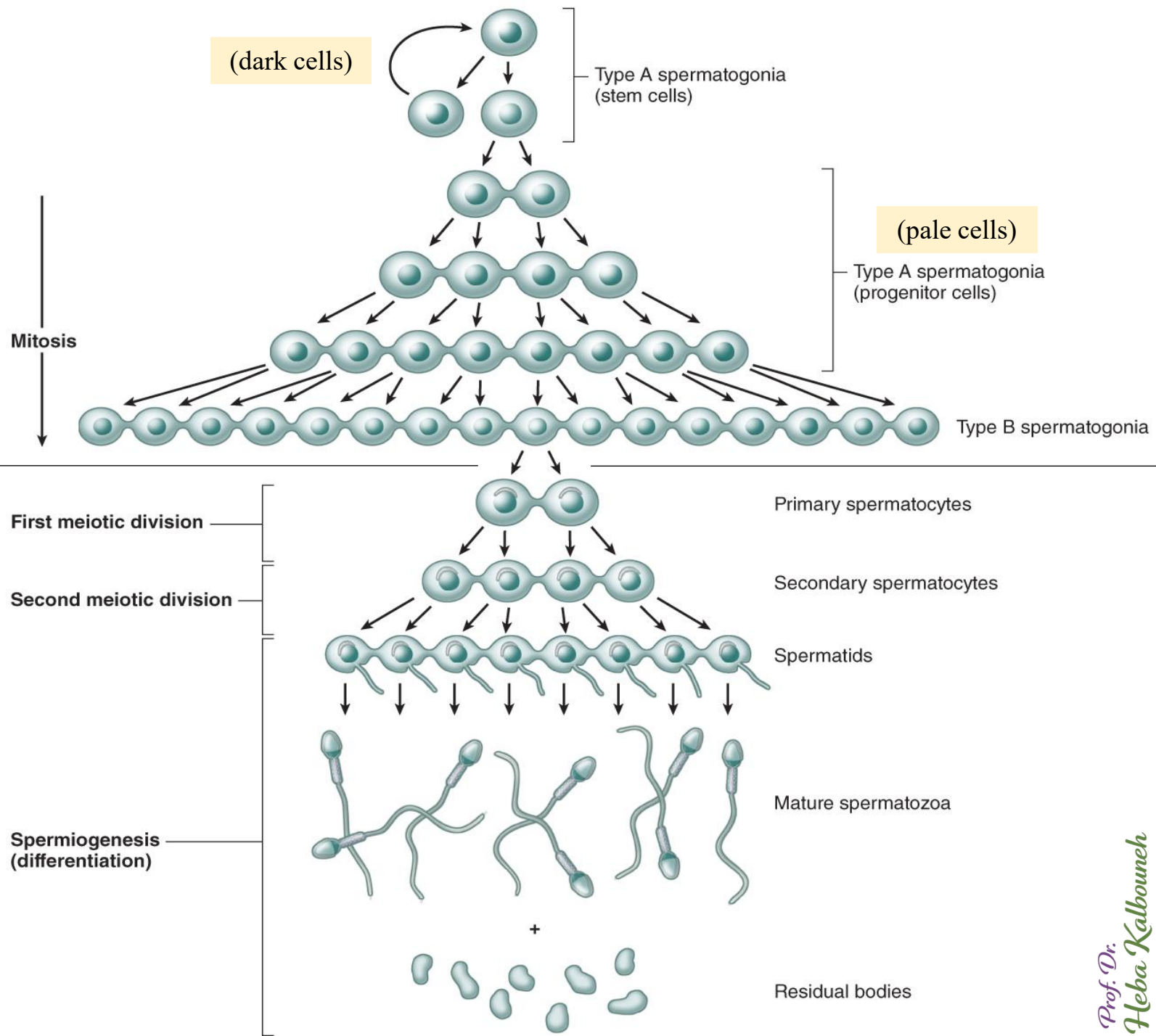
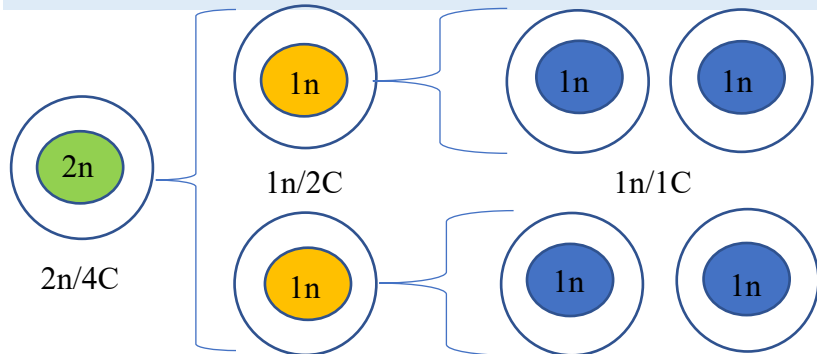
Remember!!!

Mitosis produces two identical diploid cells from one diploid cell.

Meiosis is a form of cell division that results in the production of four unique haploid cells (containing 23 chromosomes) from one diploid cell (contains 46 chromosomes).

Meiosis occurs in two stages (meiosis I and II); each containing a specialized form of prophase, metaphase, anaphase and telophase.

This is different from general cell division (Mitosis)!!!!



✓ Each seminiferous tubule is lined with a specialized stratified epithelium called **germinal or spermatogenic epithelium**

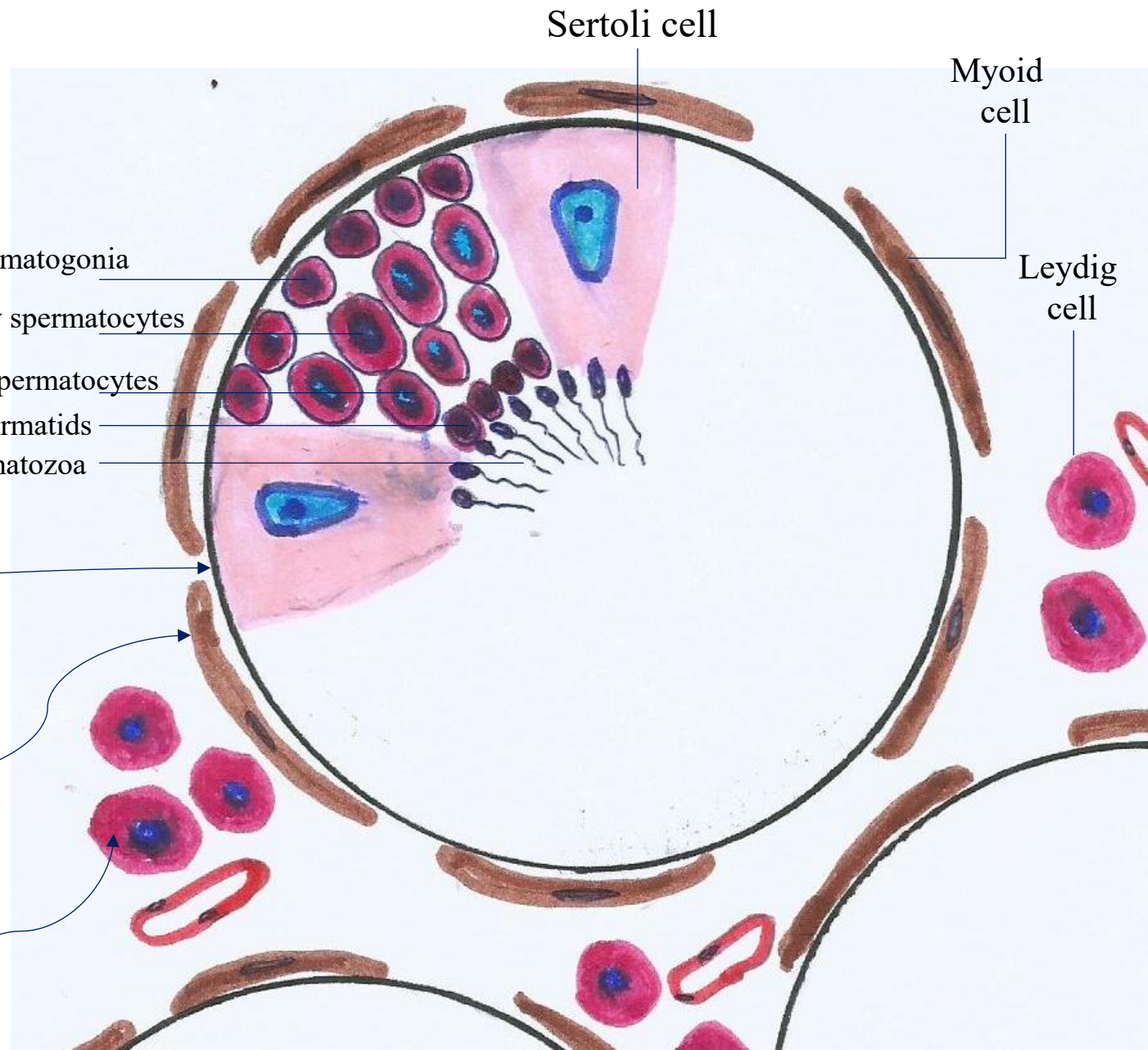
✓ The germinal epithelium consists of two types of cells:

1- Spermatogenic (germ) cells
(Dividing cells)

2- Sertoli cells
(Nondividing cells): which physically and metabolically support developing spermatogenic cells

The **basement membrane** of this epithelium is covered by connective tissue containing **myoid cells** (smooth muscle-like) → which allow weak contractions of the tubule.

Note: **Interstitial or Leydig cells** are located in the connective tissue surrounding the seminiferous tubules → which produce testosterone



Germinal Epithelium of a Seminiferous tubule

Notice the followings in this histological section:

The outlines of Sertoli cells surrounding the spermatogenic cells are very poorly defined

Spermatogenesis starts in the bottom part of seminiferous tubule and, progressively, cells go deeper into tubes and moving along it until mature spermatozoa reaches the lumen

Spermatogonia are found at the base of the tubular epithelium adjacent to the basement membrane of the tubular epithelium

Primary spermatocytes are found at mid-levels within the tubular epithelium

Spermatozoa and Spermatids are found near the lumen of the tubule

Spermatozoa are released from the Sertoli cell surface into the tubule's lumen
(Spermiation)

Spermatozoa

Sertoli cell

Primary spermatocyte

Spermatogonia A (Pale cell)

Basement membrane

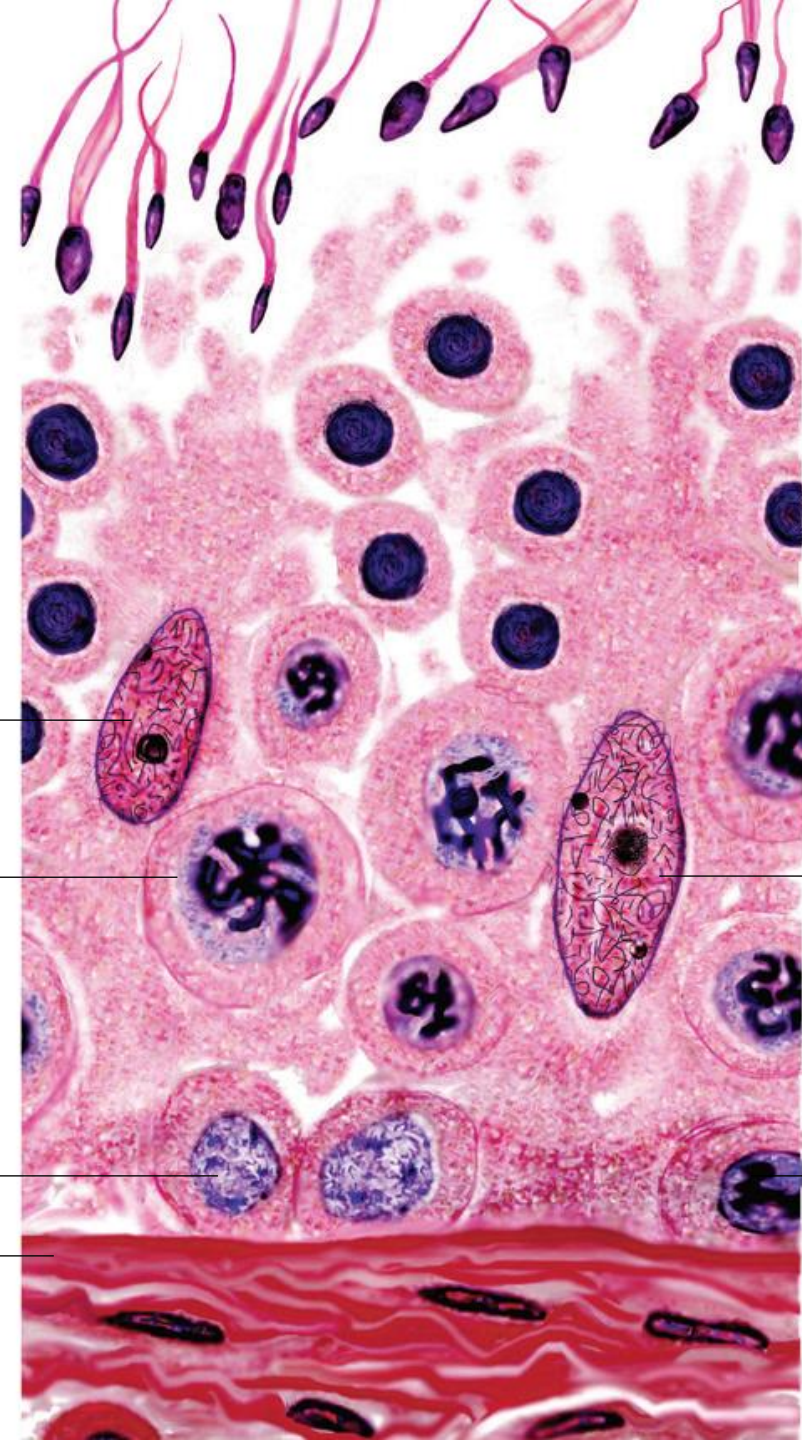
Lumen

Spermatids

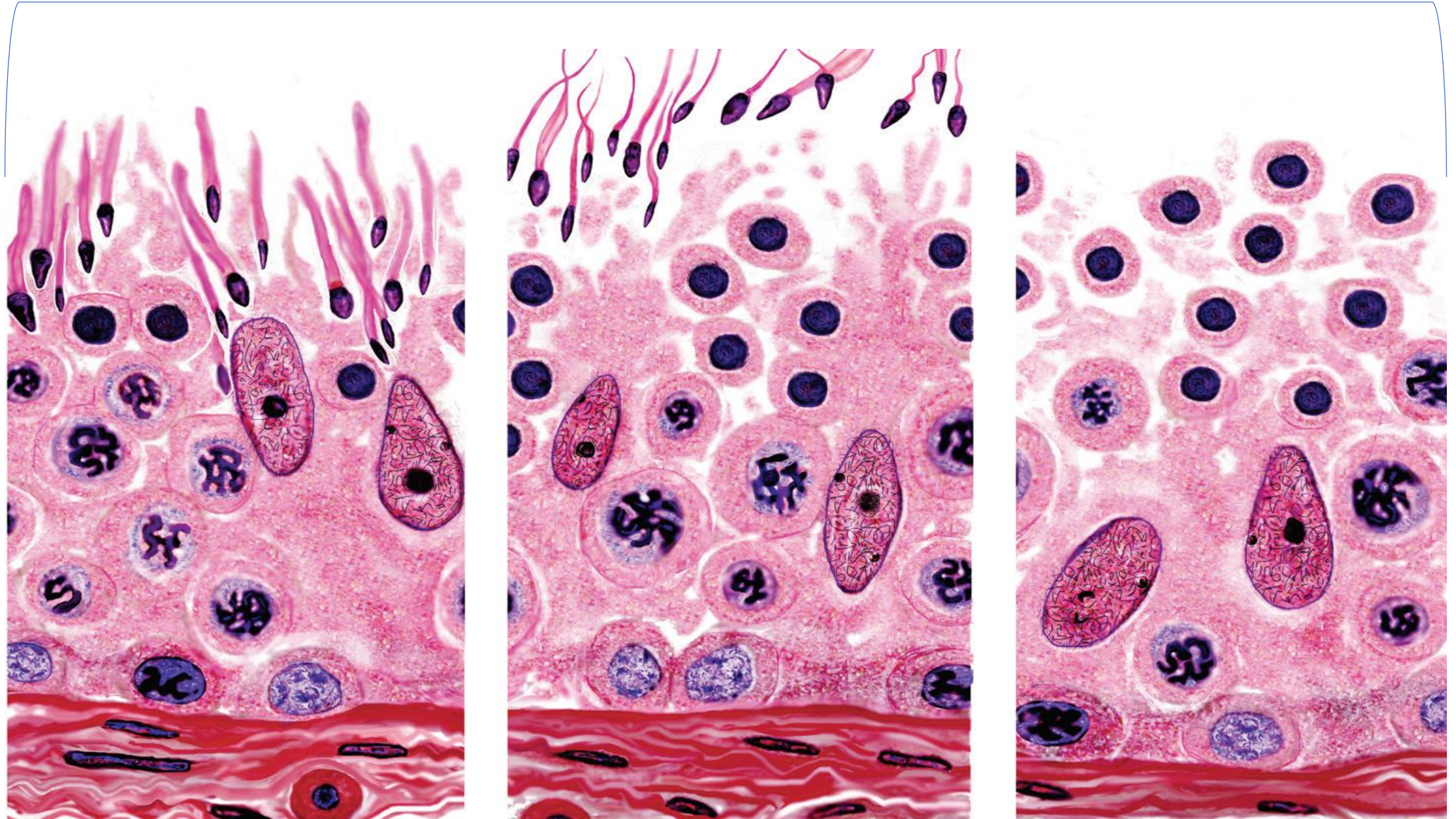
Sertoli cell

Spermatogonia A (Dark cell)

Base



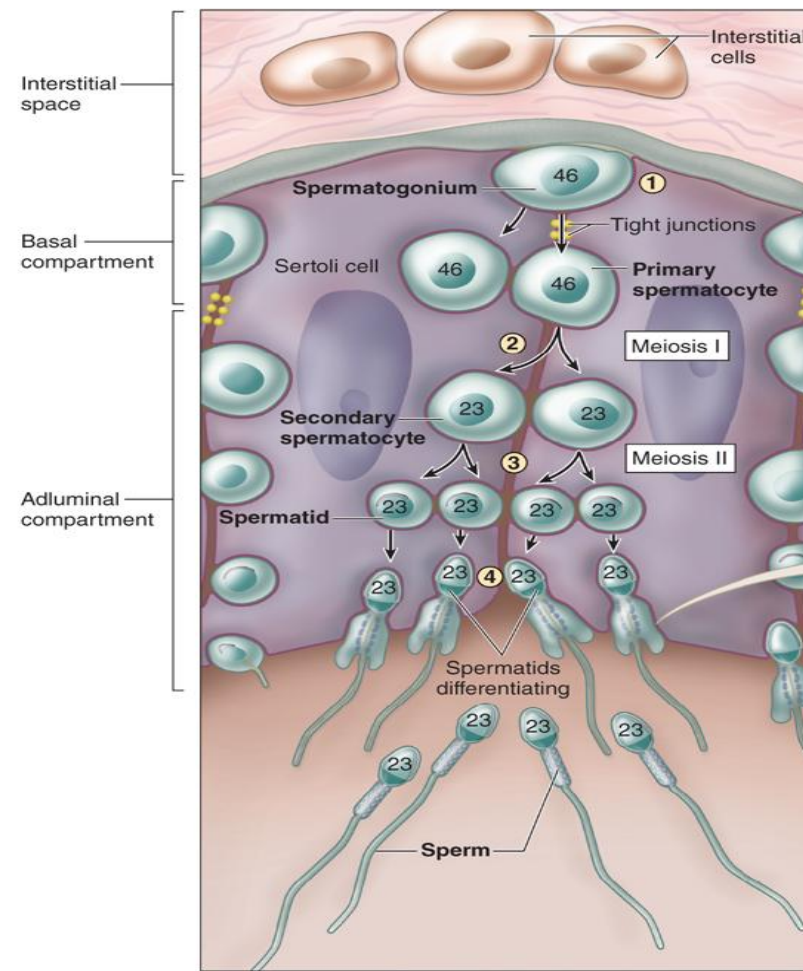
Note: **Spermiation** is the process by which mature spermatids are released from Sertoli cells into the seminiferous tubule lumen prior to their passage to the epididymis.



The diagram shows two large, columnar Sertoli cells with their surfaces binding many germ cells in various stages of spermatogenesis.

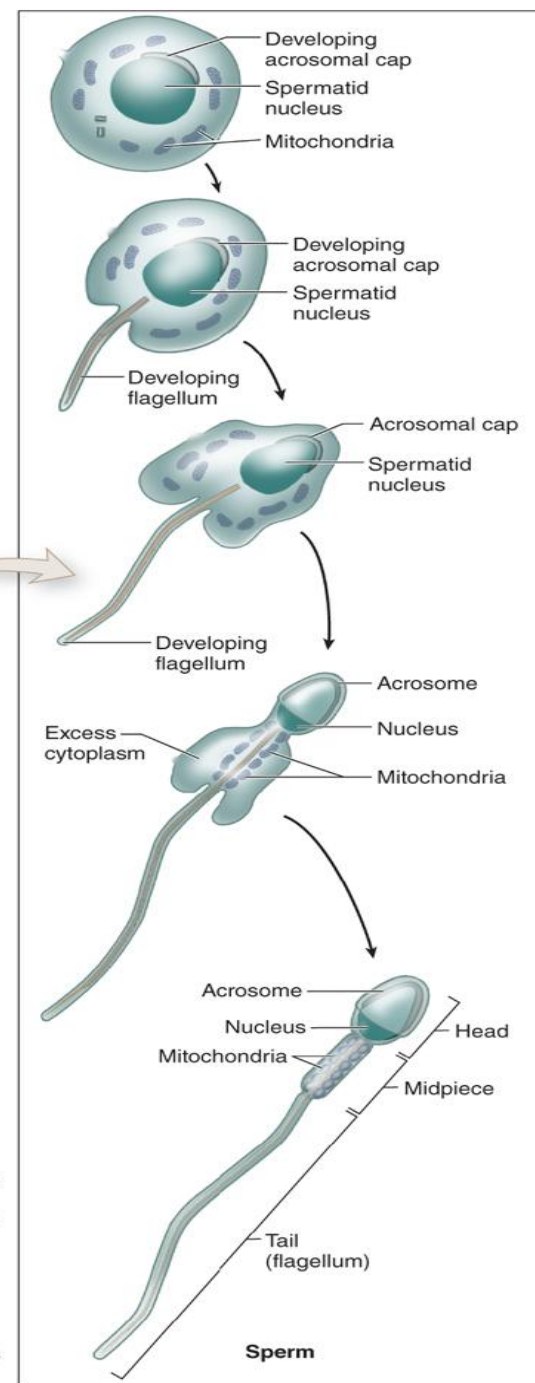
Near the basement membrane are spermatogonia, which divide by mitosis to produce both more spermatogonia and also primary spermatocytes

Primary spermatocytes undergo meiosis to produce secondary spermatocytes and then haploid spermatids differentiating as sperms



(a) Spermatogenesis

- 1 The spermatogenic progenitor cells, called spermatogonia, are diploid cells containing 46 chromosomes (23 pairs). Mitotic divisions of these cells each produce a new spermatogonium and a cell called a primary spermatocyte committed to meiosis.
- 2 Each new primary spermatocyte transiently disassembles the tight junctions of the blood-testis barrier and moves from the tubule's basal compartment to the adluminal compartment. At the same time these cells replicate their DNA, enter meiosis I, and undergo synapsis. The first meiotic division produces two haploid secondary spermatocytes each with 23 chromosomes.
- 3 Meiosis II is rapid as chromatids in the secondary spermatocyte chromosomes separate into two smaller haploid cells, the spermatids.
- 4 Near the lumen but still embedded in Sertoli cells, the spermatids differentiate and undergo the morphological changes required to become motile and capable of fertilization.



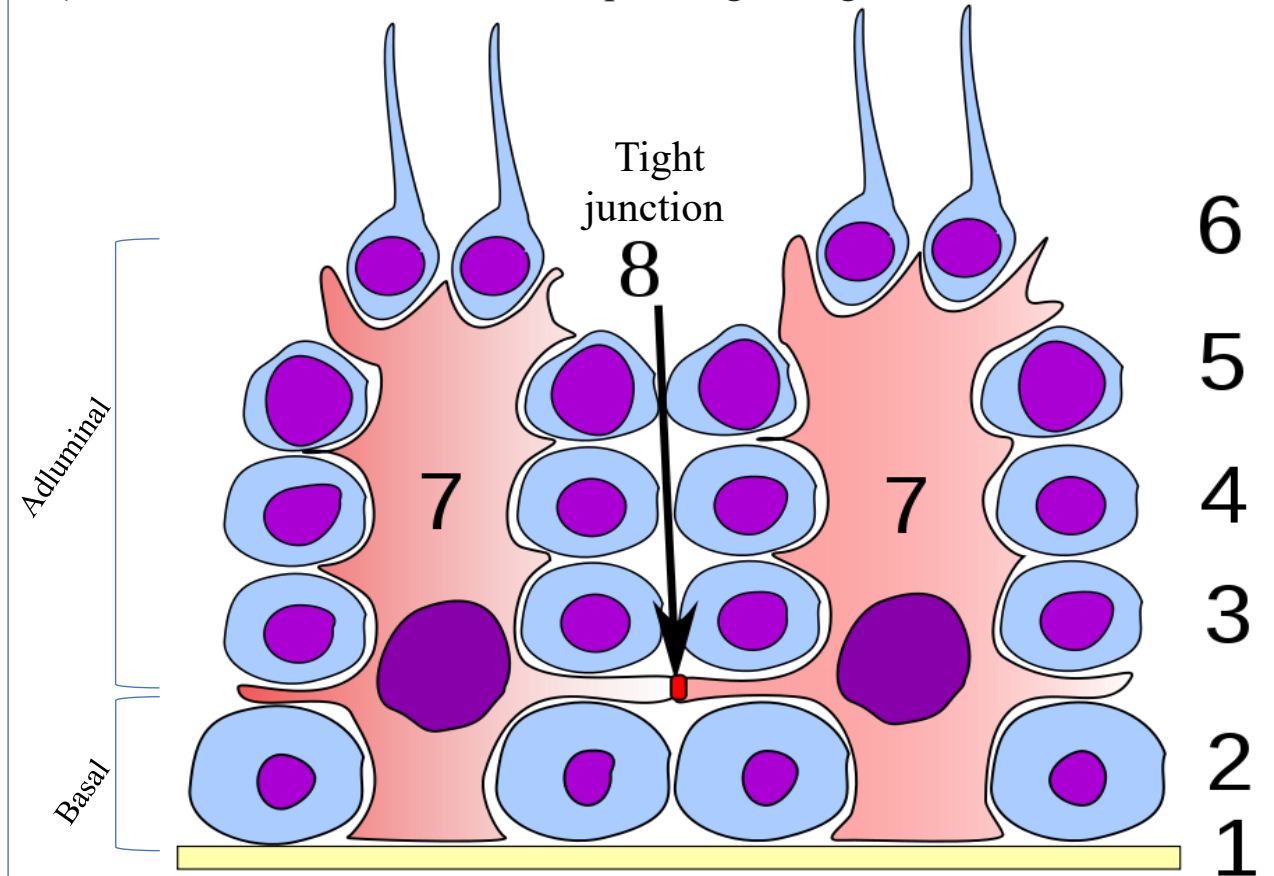
(b) Spermiogenesis

Sertoli cells

- ✓ Sertoli cells are the epithelial supporting cells of the seminiferous tubules.
- ✓ They are tall simple columnar cells, which span from the basement membrane to the lumen.
- ✓ They surround the proliferating and differentiating germ cells forming pockets around these cells, providing nutrients, and phagocytosing excess spermatid cytoplasm (rich in lysosomes)
- ✓ They are connected to each other by continuous tight junctions that seal the tubule into two compartments:
 - Basal compartment** (close to the basal lamina)
 - Adluminal compartment** (towards the lumen)
- ✓ Large molecules cannot pass between the basal and adluminal compartment - this is called the **Blood-Testis Barrier**.

The developing cells are in a very protective environment.

Tight junctions between Sertoli cells comprise the “Blood-Testis Barrier” (BTB isolates the further developed stages of germ cells from the blood)



This physical barrier prevents autoimmune attacks against the unique spermatogenic cells, which first appear after the immune system is mature.

(protecting spermatogenic cells from circulating immune components).

- 1 Basement membrane
- 2 Spermatogonia
- 3 Primary spermatocyte
- 4 Secondary spermatocyte
- 5 Spermatid
- 6 Mature spermatozoon
- 7 Sertoli cell
- 8 Tight junction (Blood- Testis Barrier)

Prof. Dr. Heba Kalbouneh

!!!! Each Sertoli cell supports 30-50 developing germ cells

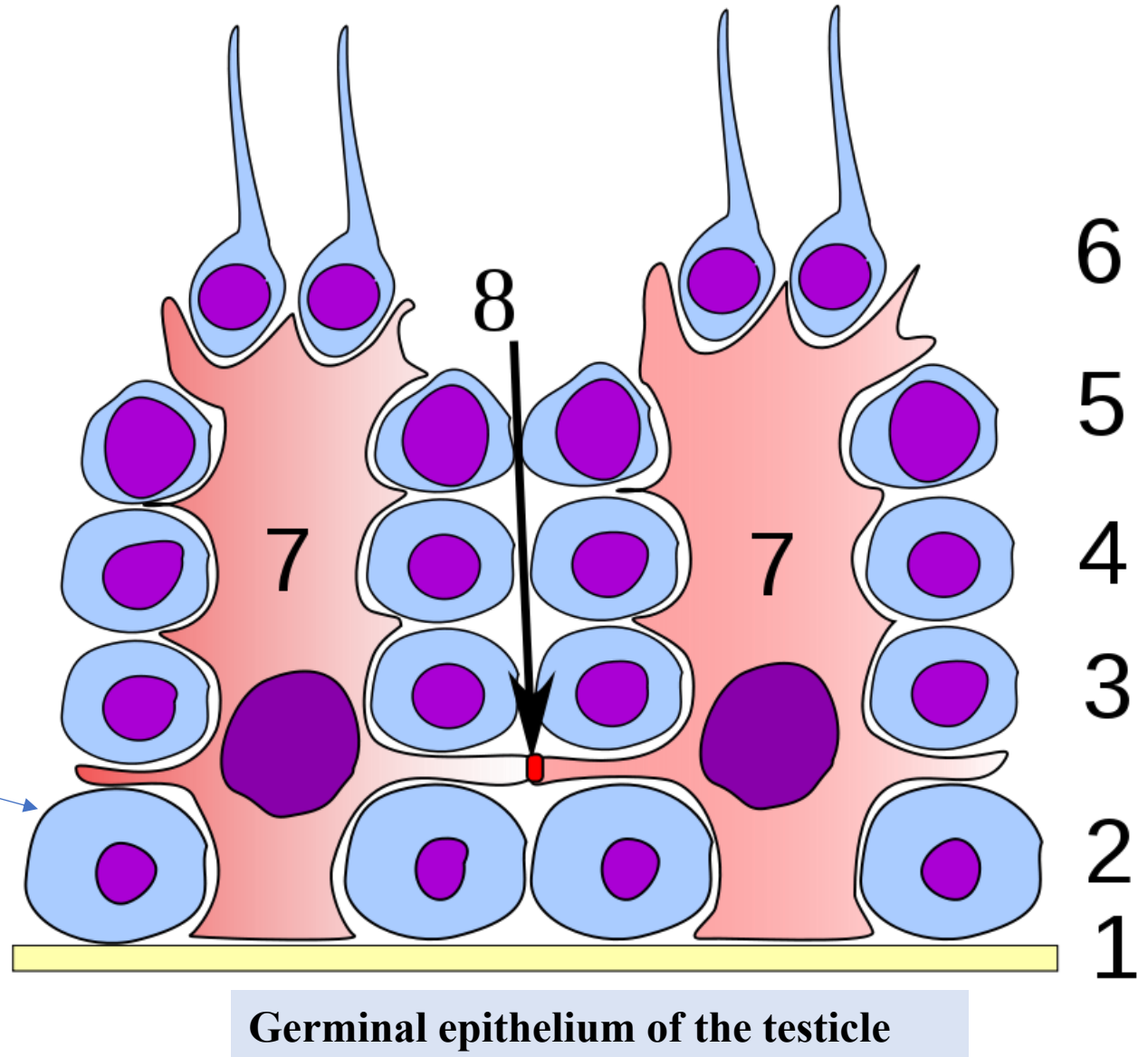
NOTE

Spermatogonia, all spermatocytes and spermatids lie within invaginations of the Sertoli cells surfaces.

Spermatogonia lie in a basal compartment of the tubule, below the tight junctions

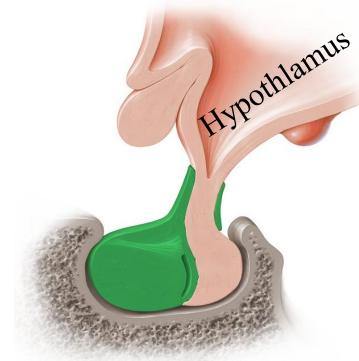
Newly formed primary spermatocytes temporarily disassemble the tight junctions between Sertoli cells and move from the basal compartment to the adluminal compartment of the tubule, while still adhering to Sertoli cells (Adluminal migration)

As the flagellar tails of the spermatids develop, they appear as tufts extending from the apical ends of the Sertoli cells.



Spermatogenesis

Under the influence of gonadotropin releasing hormone from the hypothalamus, the pituitary gland releases both luteinizing and follicle stimulating hormones (LH & FSH).



Ant. Pituitary gland

LH



Leydig cells

Luteinizing hormone acts on Leydig cells of the testicles that subsequently secrete **testosterone**.

FSH

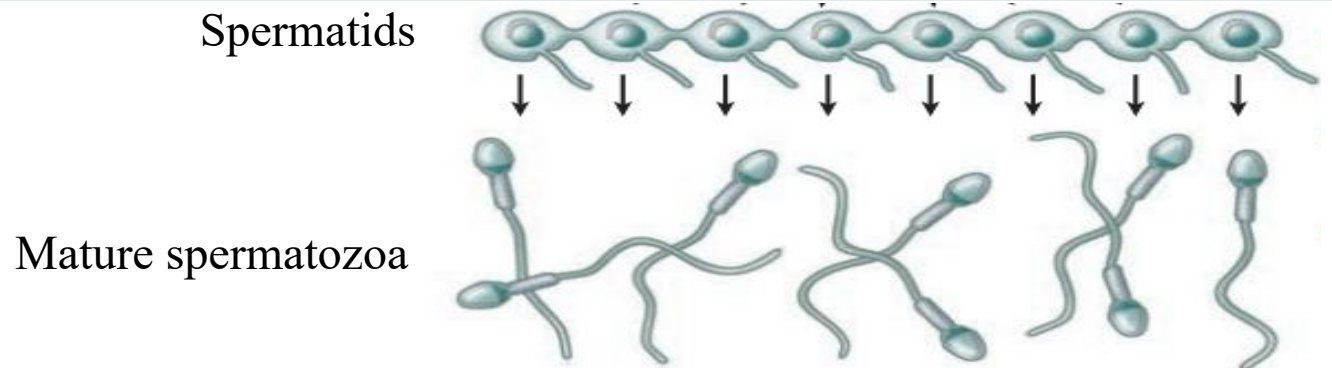


Sertoli cells

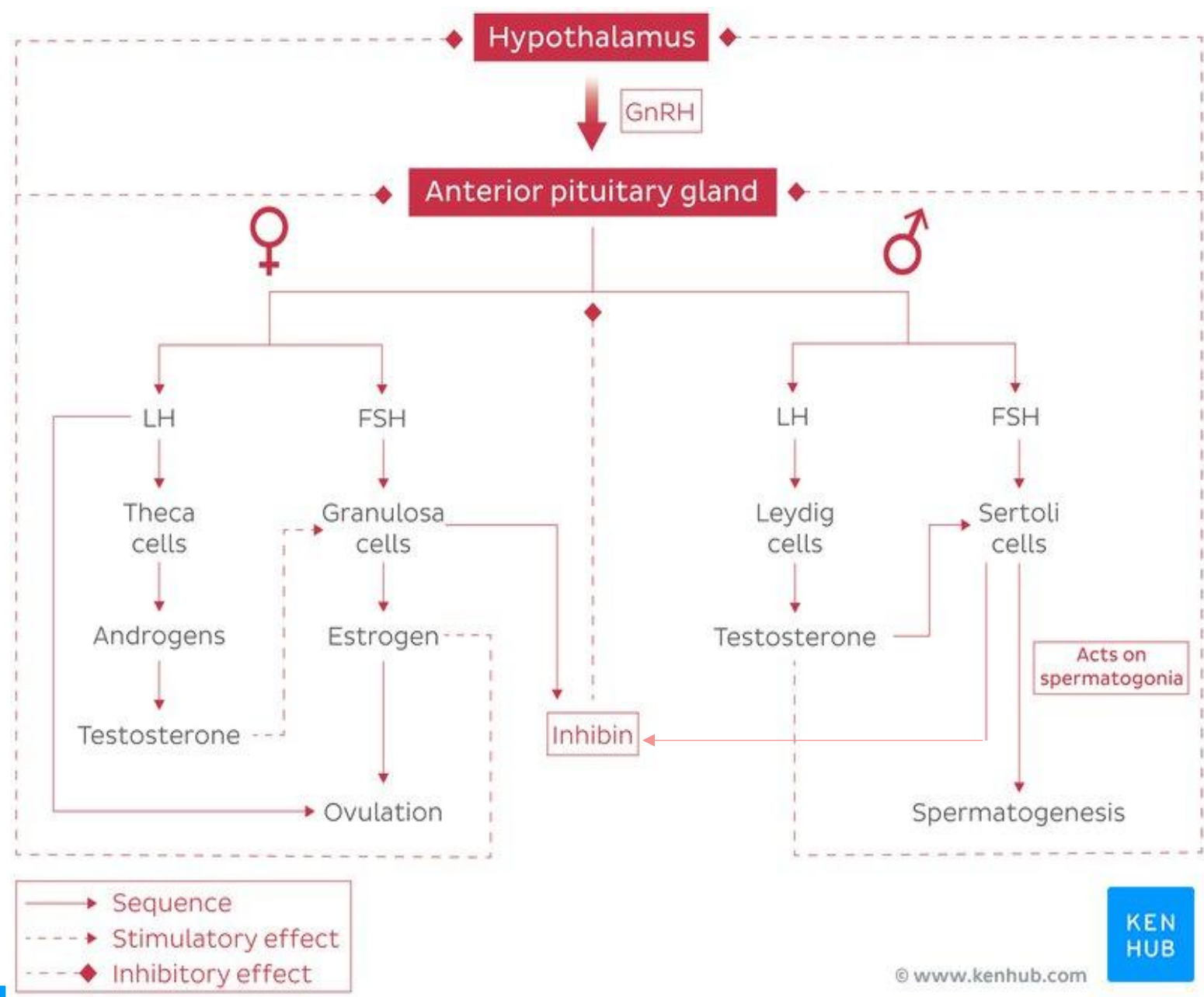
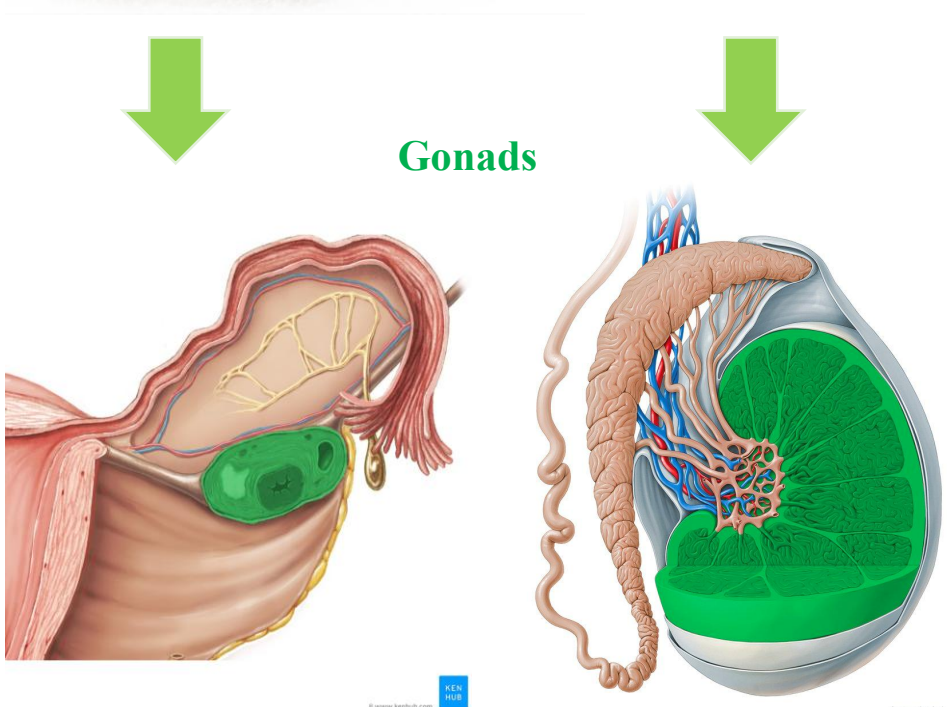
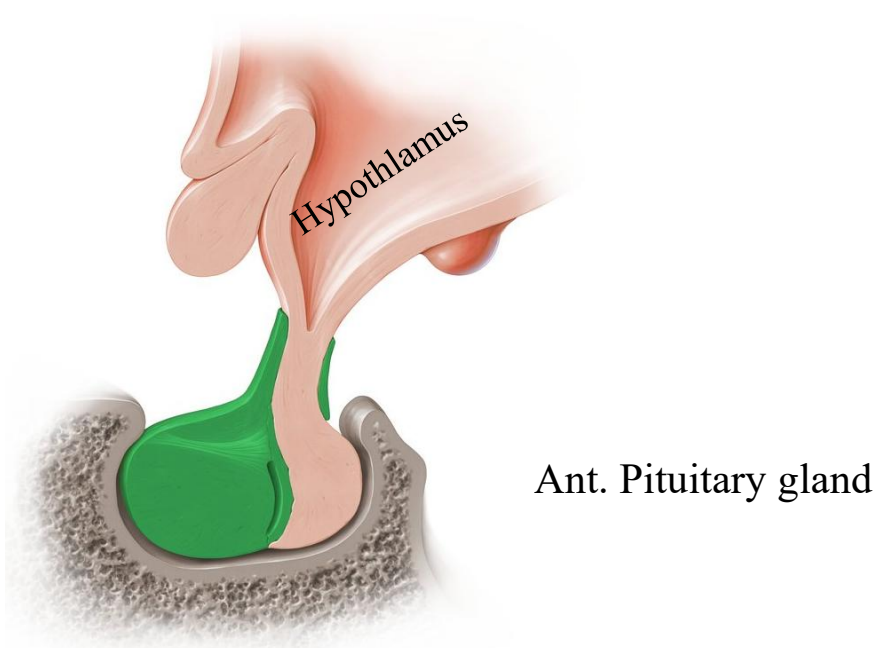
FSH stimulates the Sertoli cells to secrete **androgen-binding protein** into the lumen of the seminiferous tubules. Binding of testosterone in the lumen provides a local testosterone supply for the developing spermatogonia.

Resulting in activation of spermatogenesis

Spermiogenesis is the temperature-sensitive process by which spermatids differentiate into spermatozoa



Prof. Dr. Heba Kalbouneh

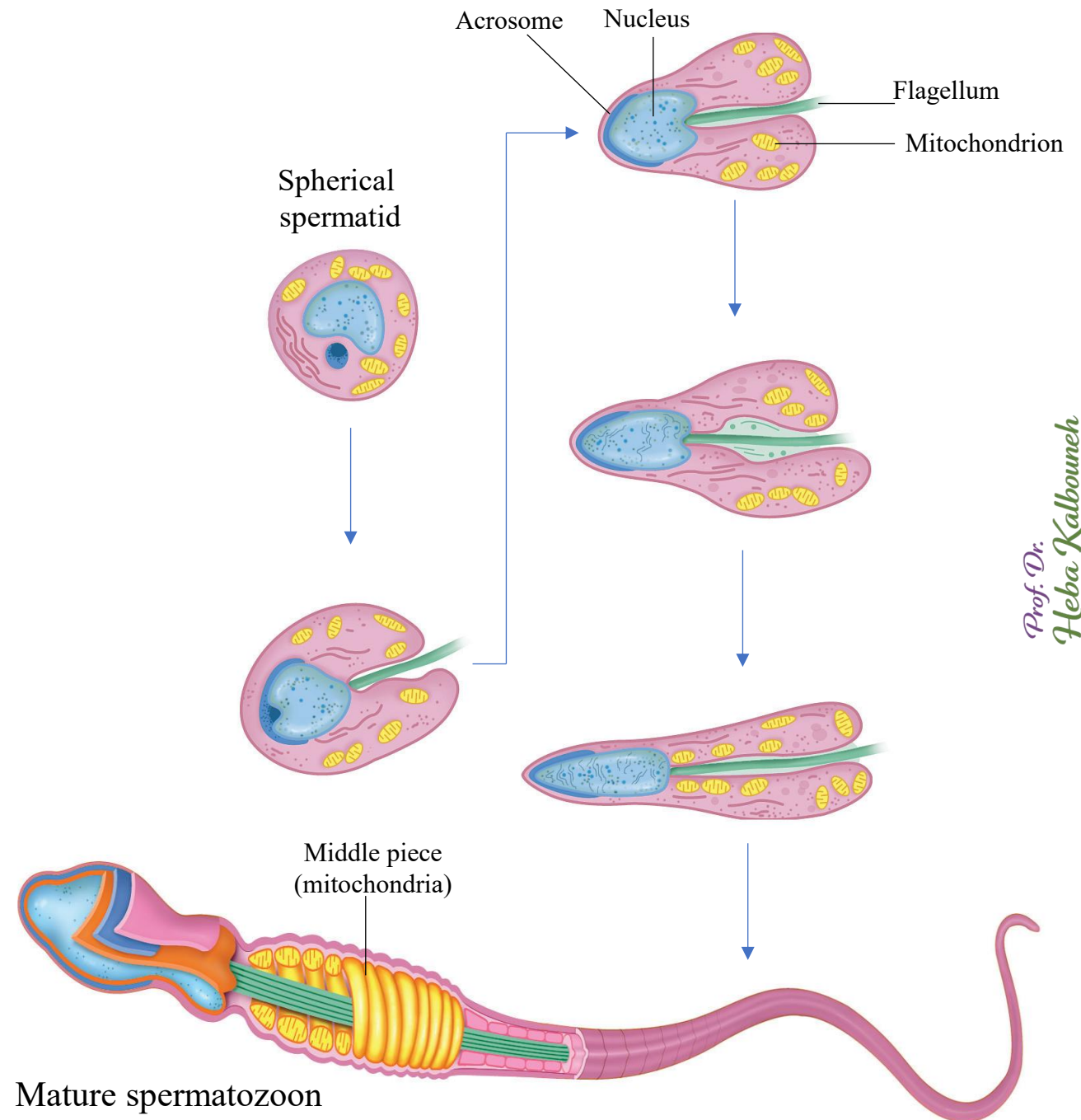


Spermiogenesis is the process by which the spherical spermatids are transformed into elongated sperm cells (spermatozoa). 60um in length


The major changes that occur during spermiogenesis are:

- 1- Condensation and elongation of the nucleus
- 2- Formation of the acrosome (Gr. akron, extremity + soma, body)
- 3- Development of the flagellum (L, whip)
- 4- Reorganization of the mitochondria in the midpiece region
- 5- Shedding of unneeded cytoplasm

The end result is the mature spermatozoon (Fully formed, but not yet functional or mobile), which is released from the Sertoli cell surface into the tubule's lumen



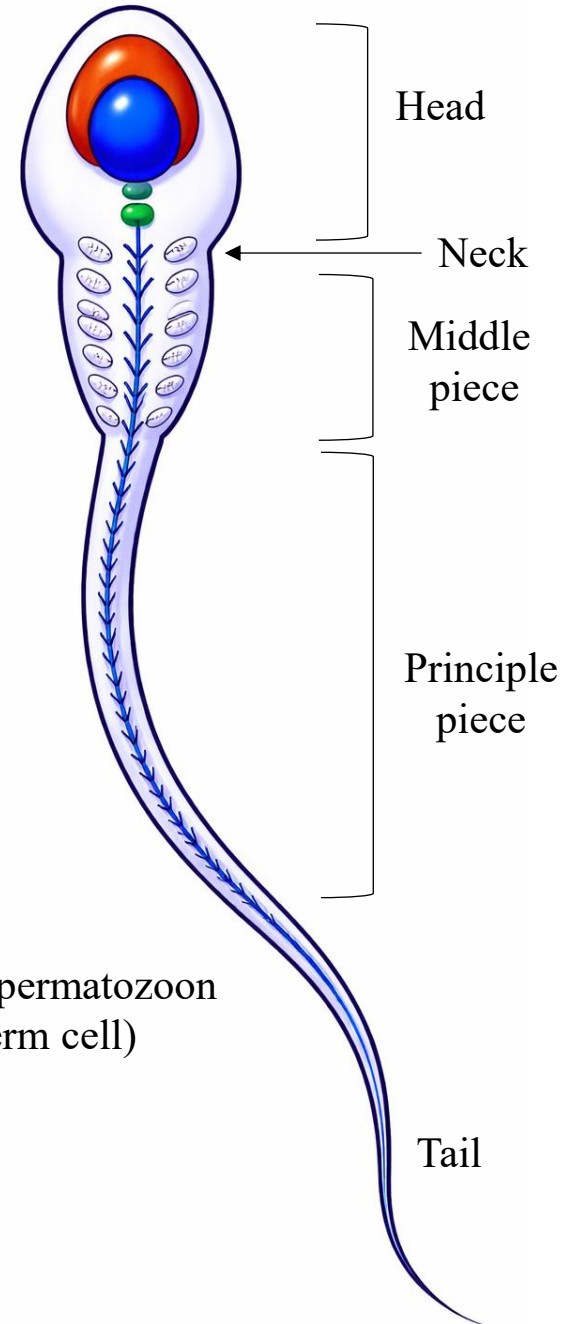
Spermatid

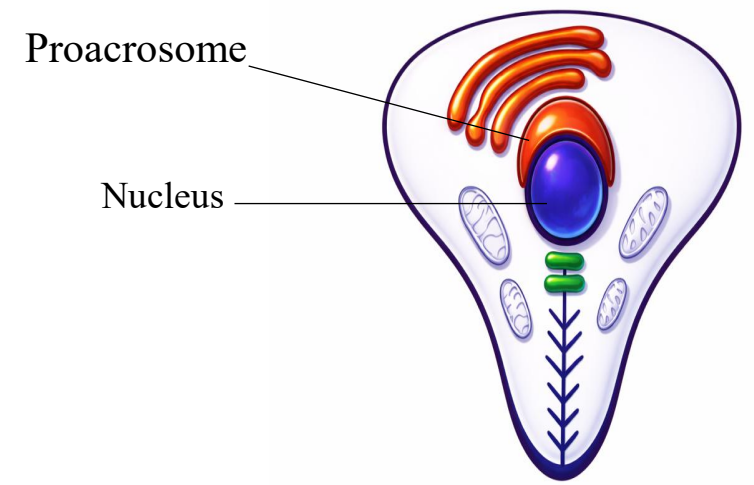
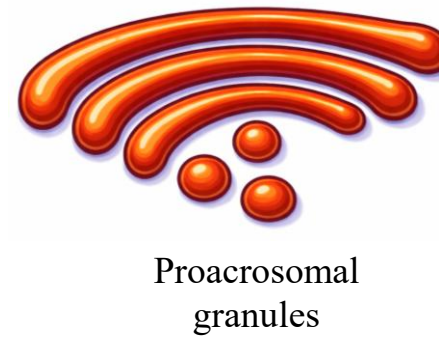
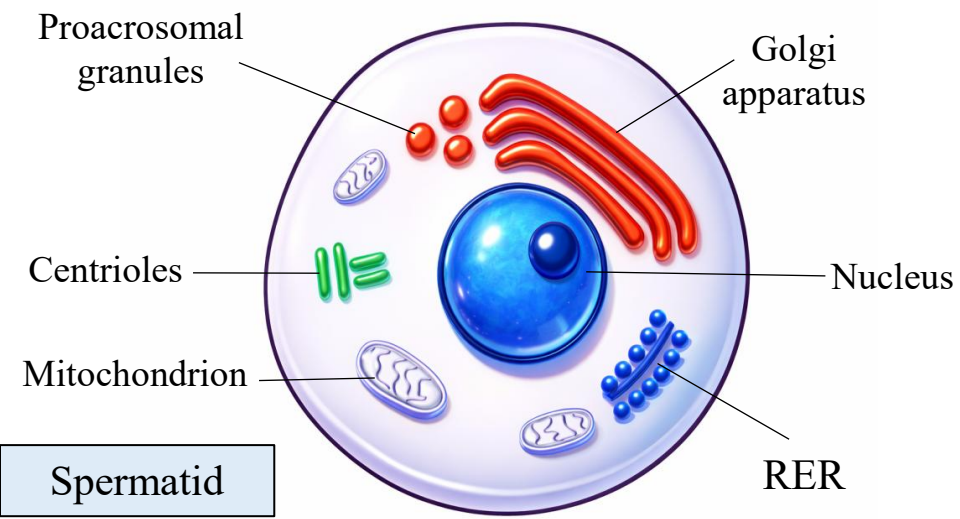


Spermiogenesis



Mature spermatozoon
(Sperm cell)



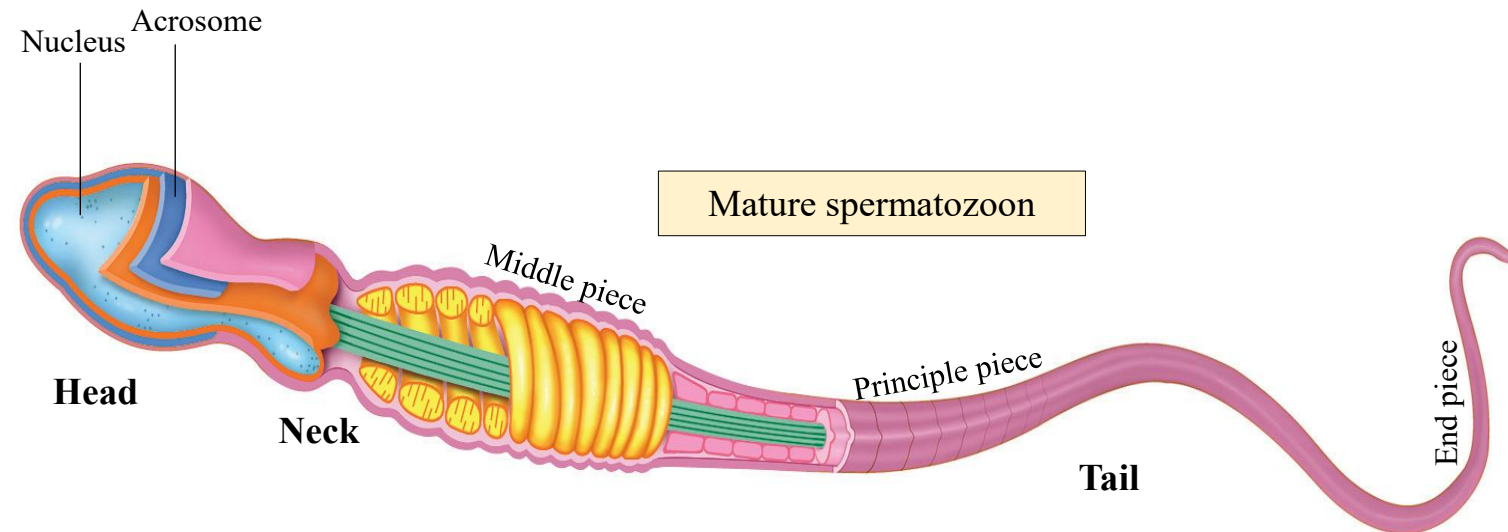


The mature spermatozoa are comprised of:

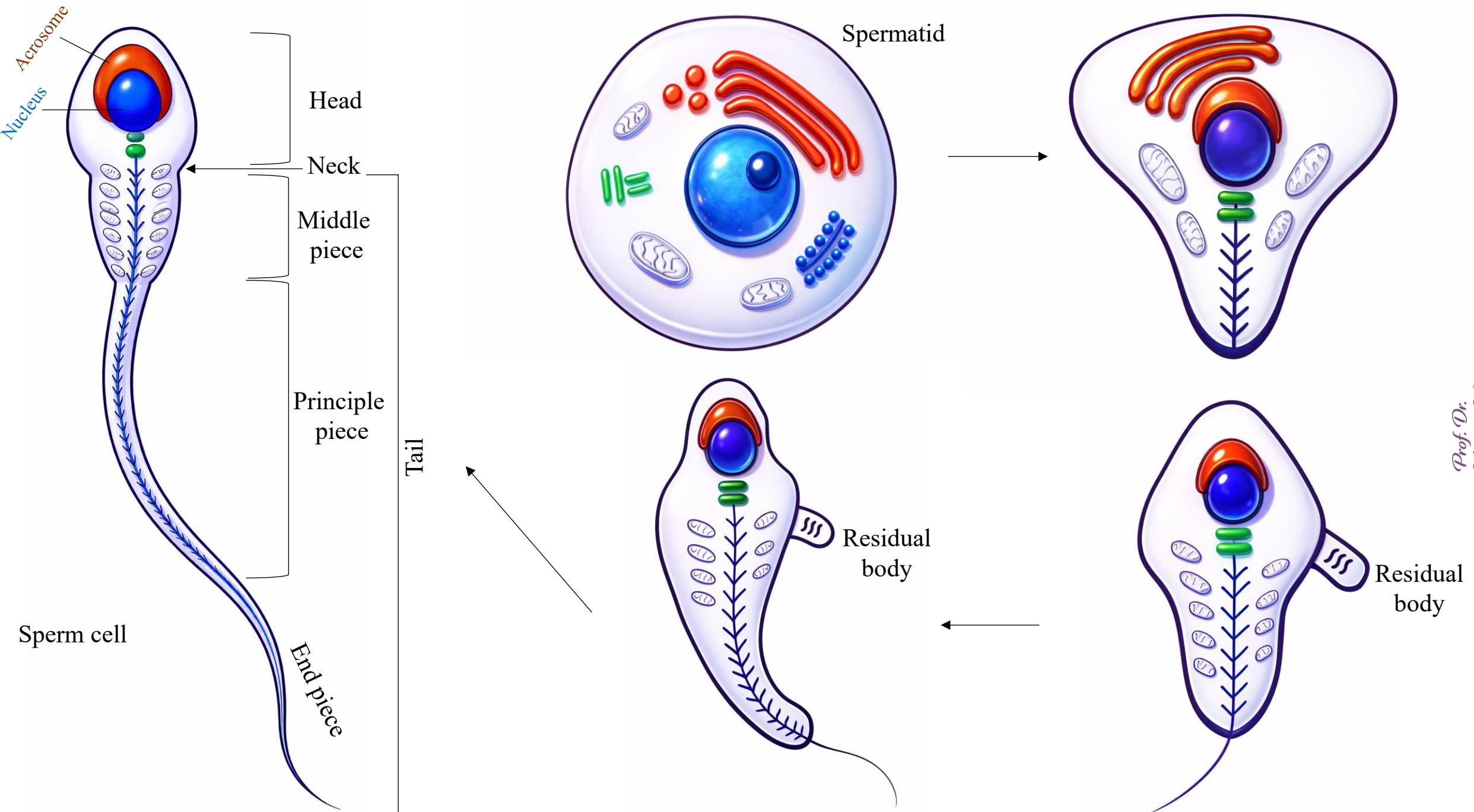
- 1- A **head** that contains the haploid nucleus and the **acrosome** that contains proteolytic enzymes needed for fertilization.
- 2- A **neck** that forms a bridge between the head and tail.
- 3- A **tail** that is divided into middle, principal and end pieces. It also houses the mitochondria that produce ATP for cellular motility.

Note that the acrosome is a derivative of the Golgi apparatus of the spermatid.

Prof. Dr.
Heba Kalbouneh



The acrosome is a unique membranous organelle located over the anterior part of the sperm nucleus. It contains digestive/hydrolytic enzymes that, when secreted, help the sperm penetrate the egg's coats.



Prof. Dr. Heba Kalbouneh

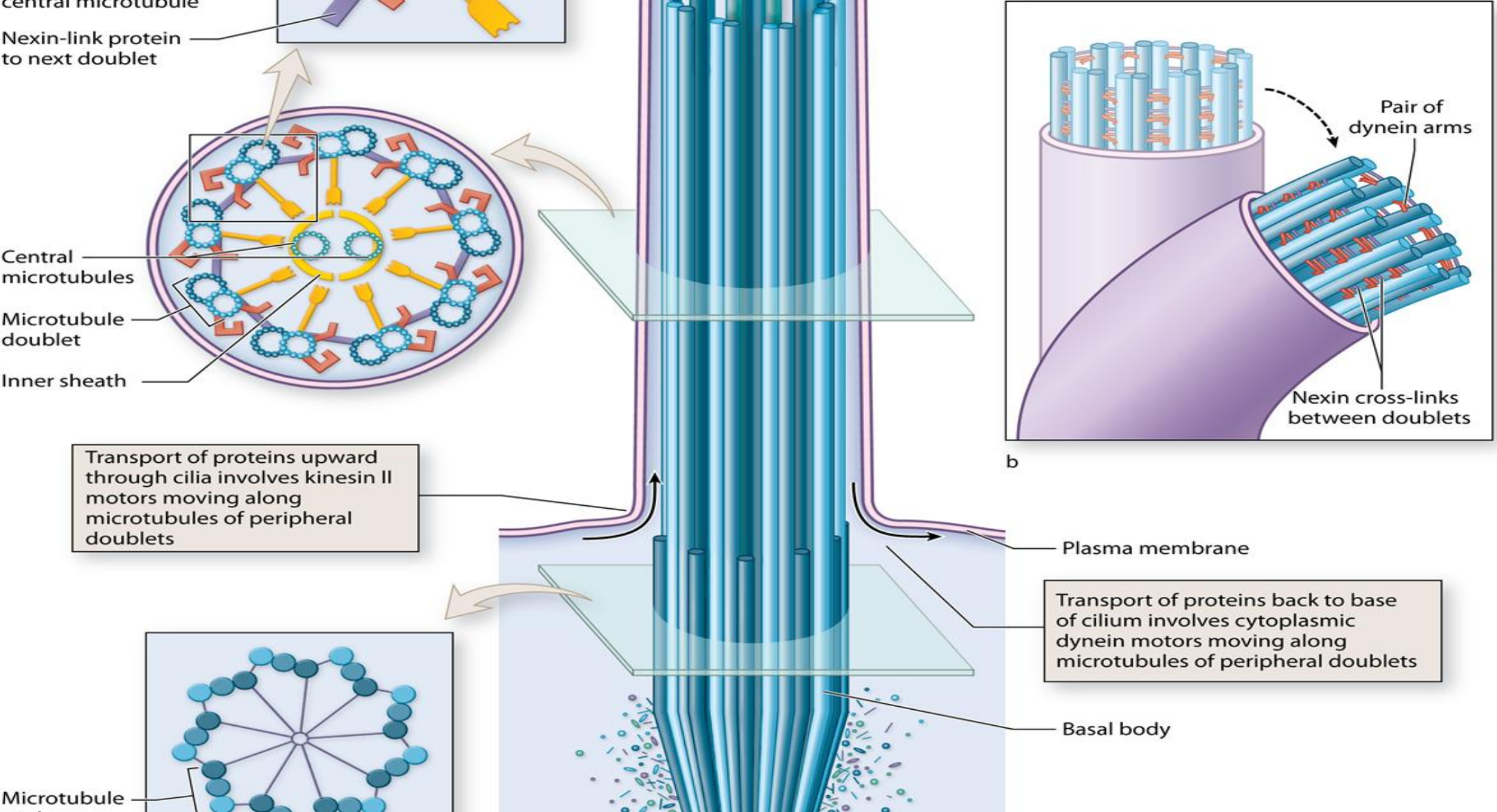
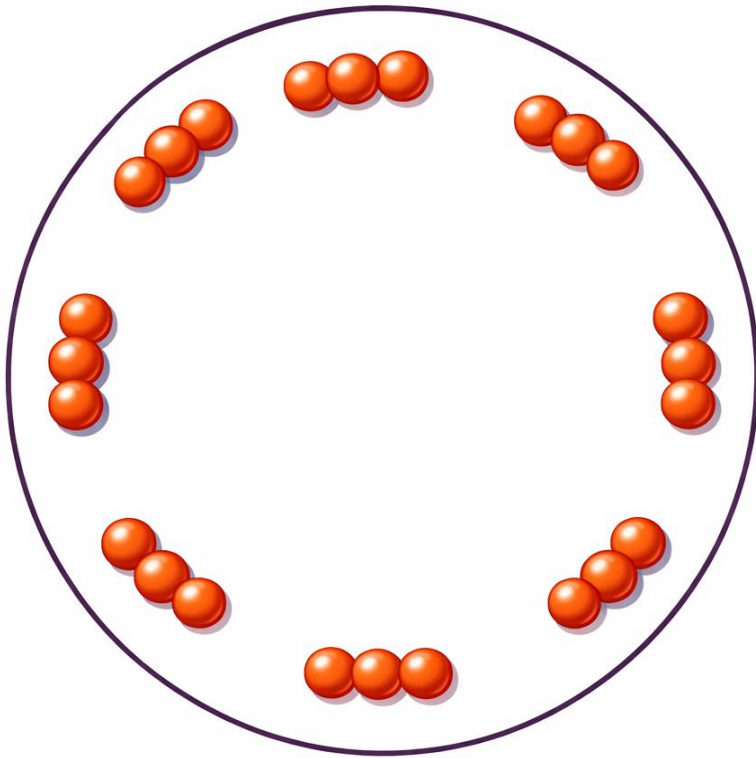


Figure 4-11

They are built from microtubules (tubulin proteins)

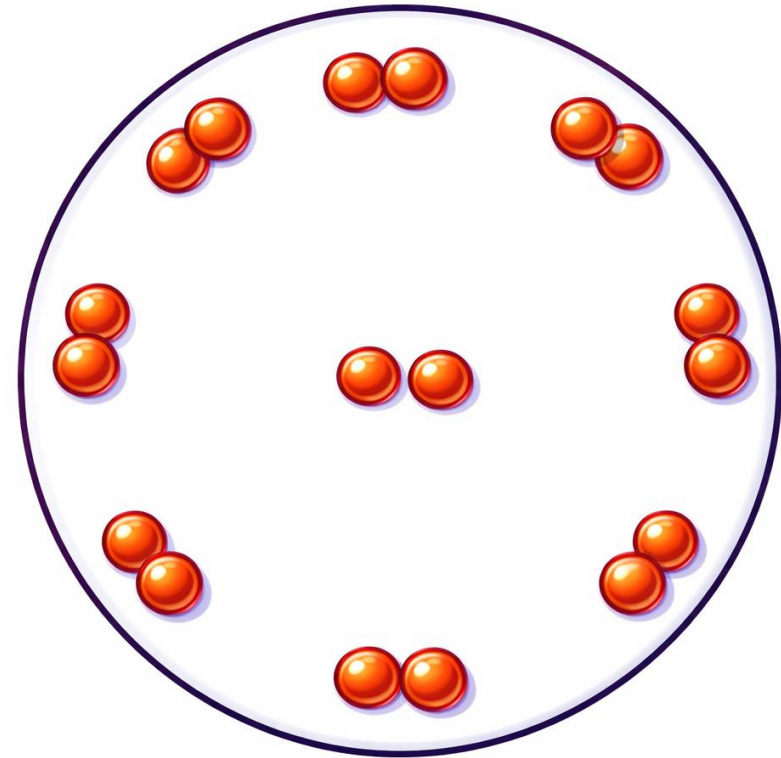


Basal body/ Centriole

(9 peripheral triplets, no central singlets)

(9+0)

A basal body comes from a centriole



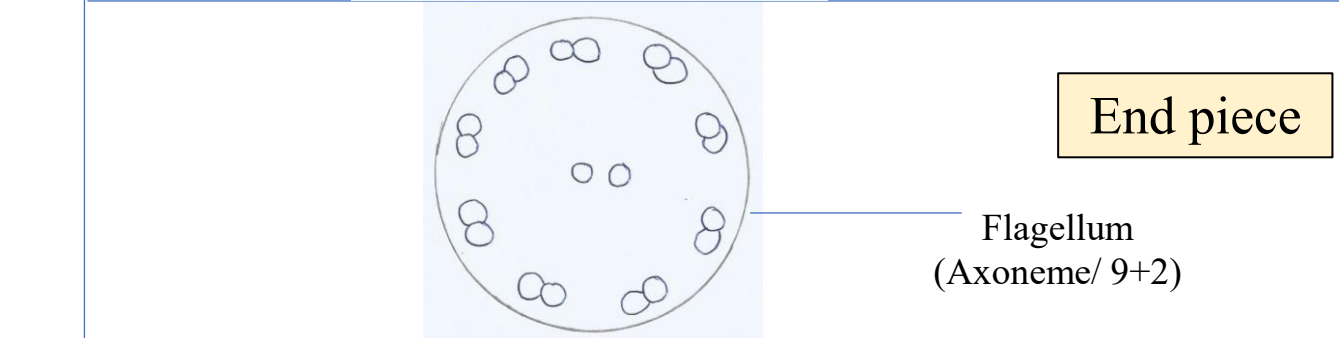
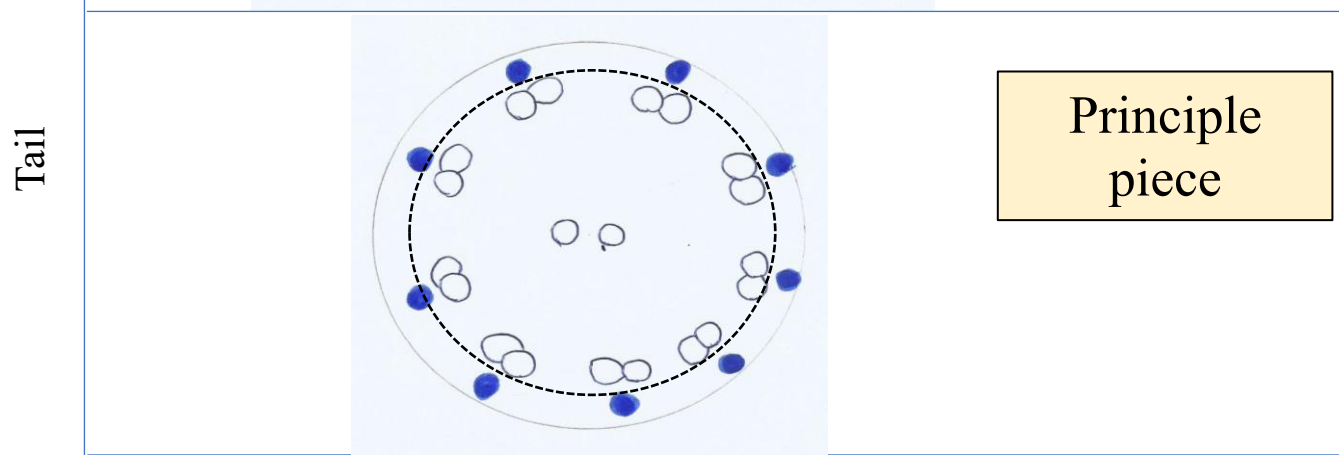
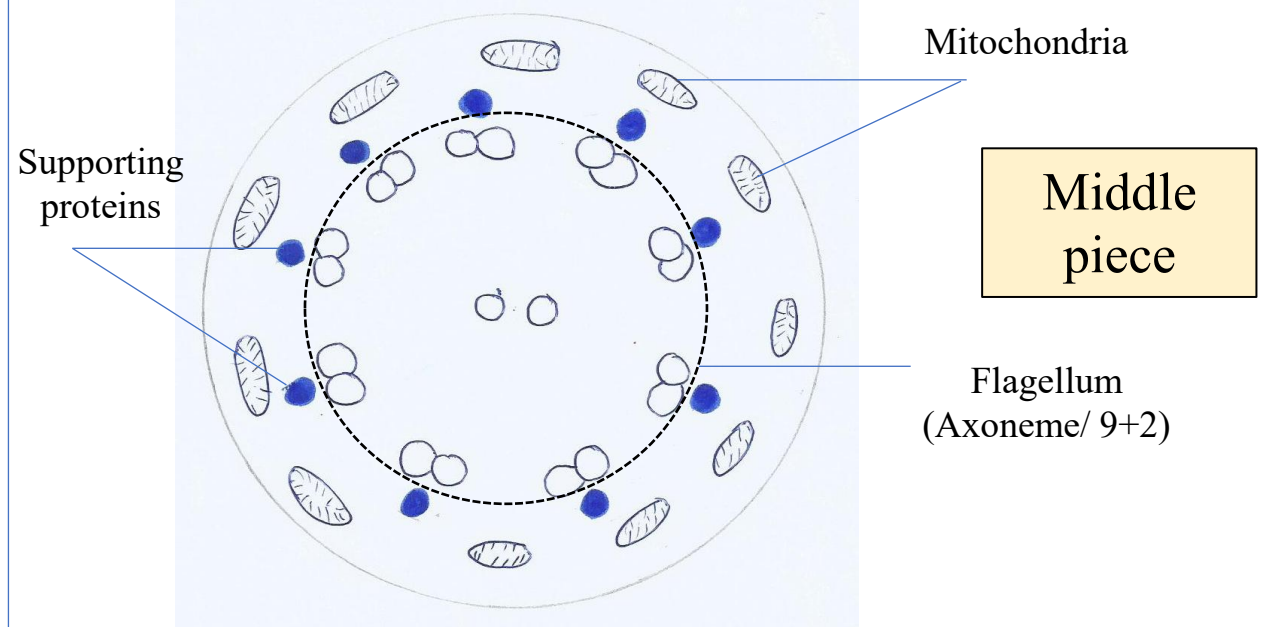
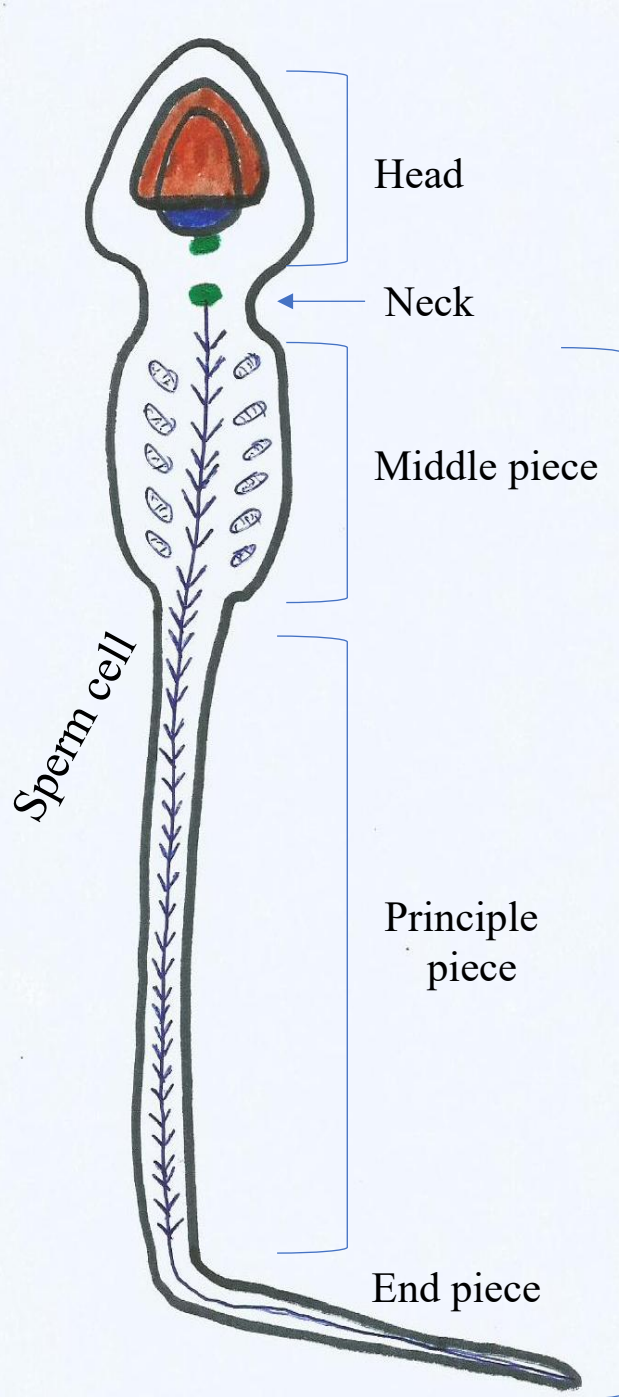
Flagellum/ Cilium

(9 peripheral doublets+ 2 central singlets)

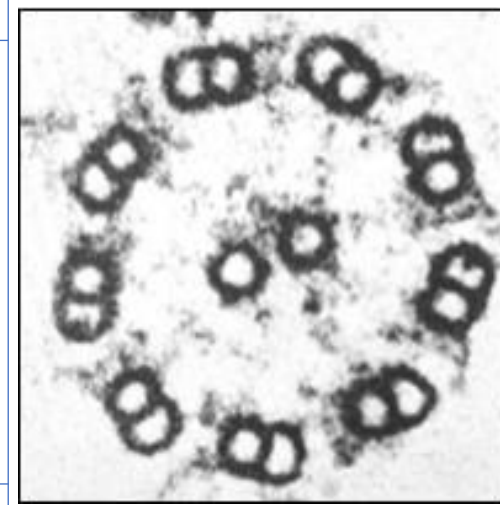
(9+2)

Axoneme

Formed from a basal body → which comes from a centriole



From which part of the sperm cell this section is taken?

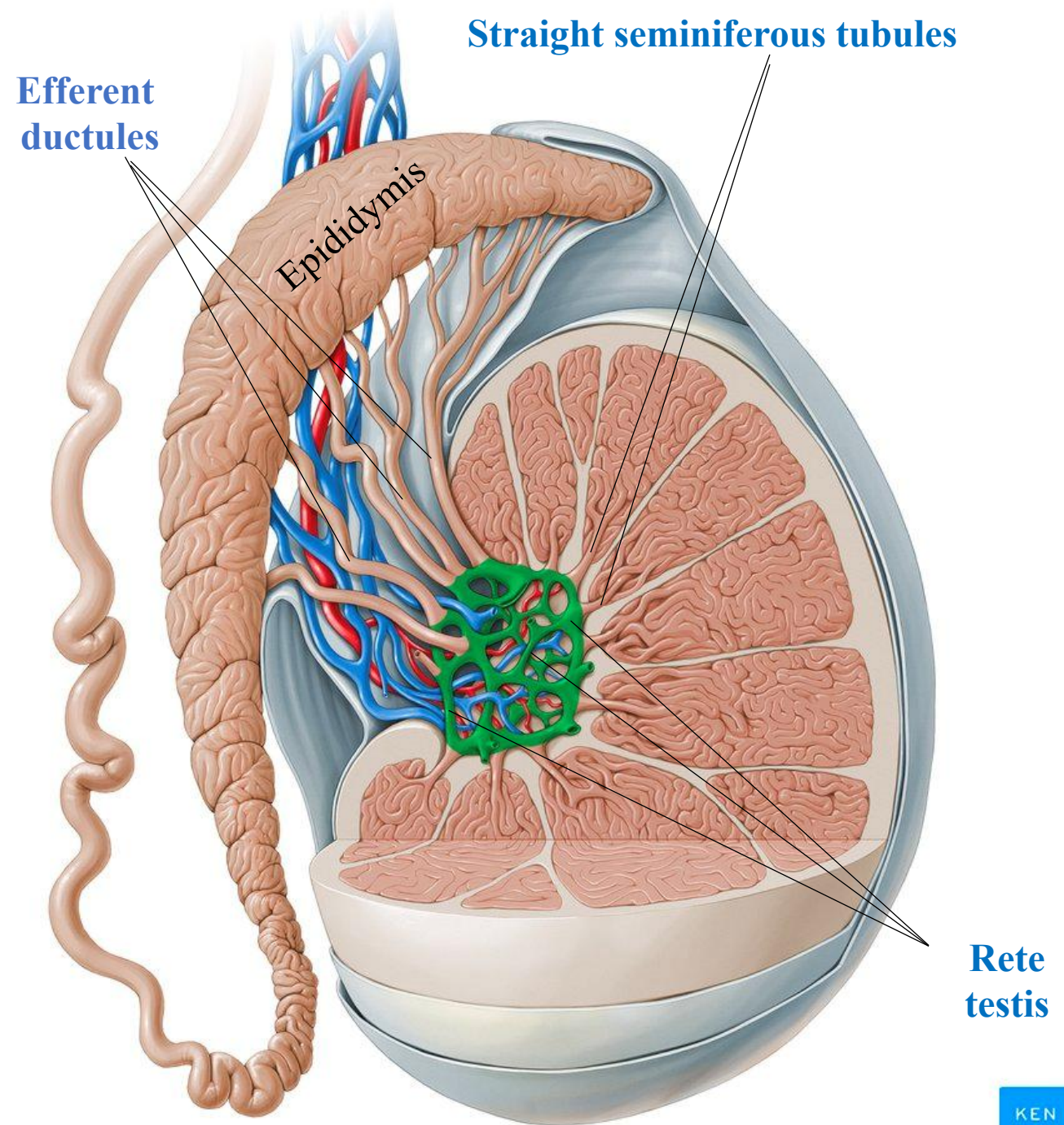


The Intratesticular Ducts

The intratesticular ducts are:

- 1- The **straight seminiferous tubules**
- 2- The **rete testis**
- 3- The **efferent ductules**

All of which carry spermatozoa and liquid from the seminiferous tubules to the epididymis where spermatozoa become fully mature and mobile



Efferent ductules

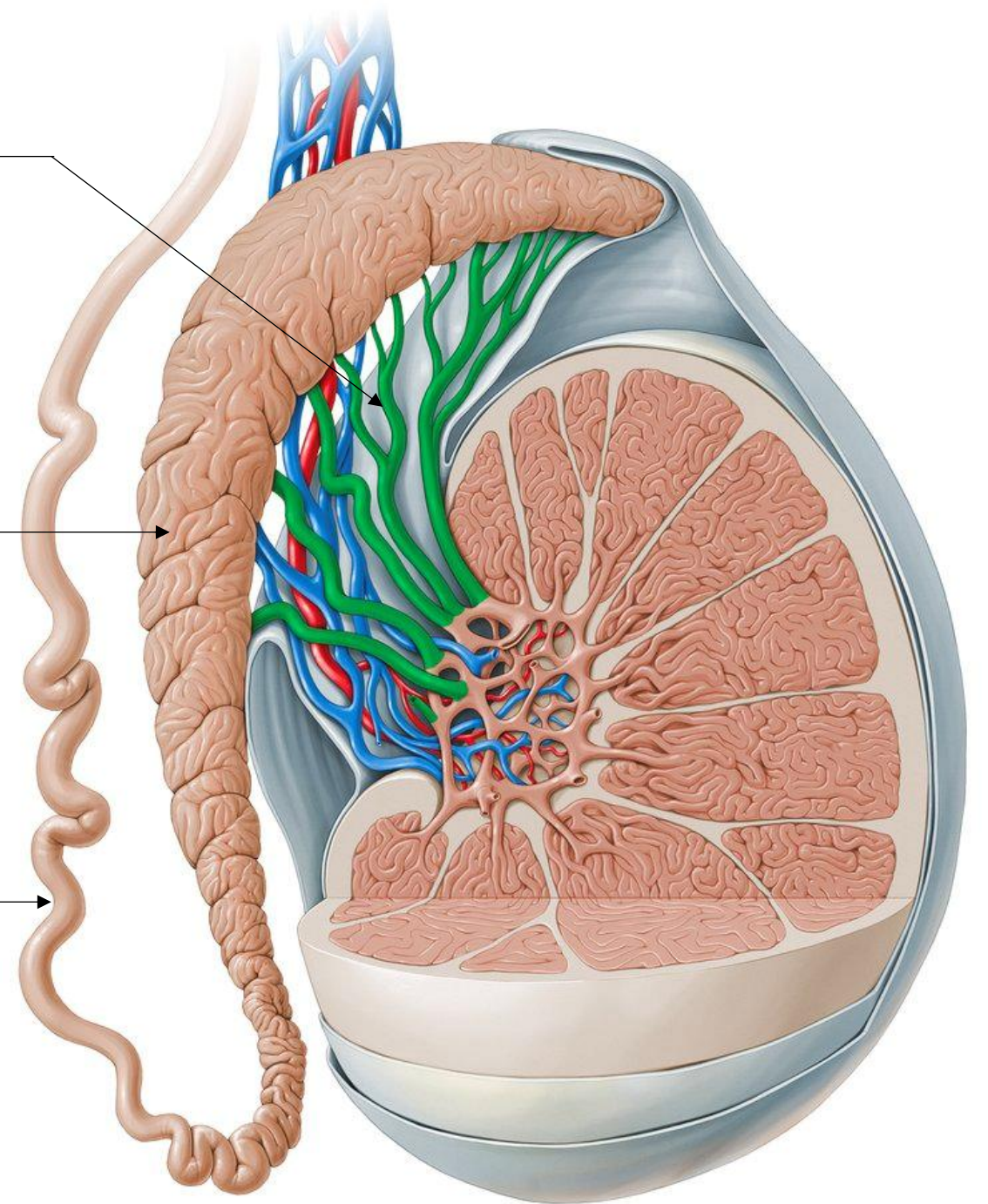
Absorb most fluid from seminiferous tubules; convey sperm into the epididymis

Epididymis

Site for sperm maturation and short-term storage; expels sperm at ejaculation

Vas Deference

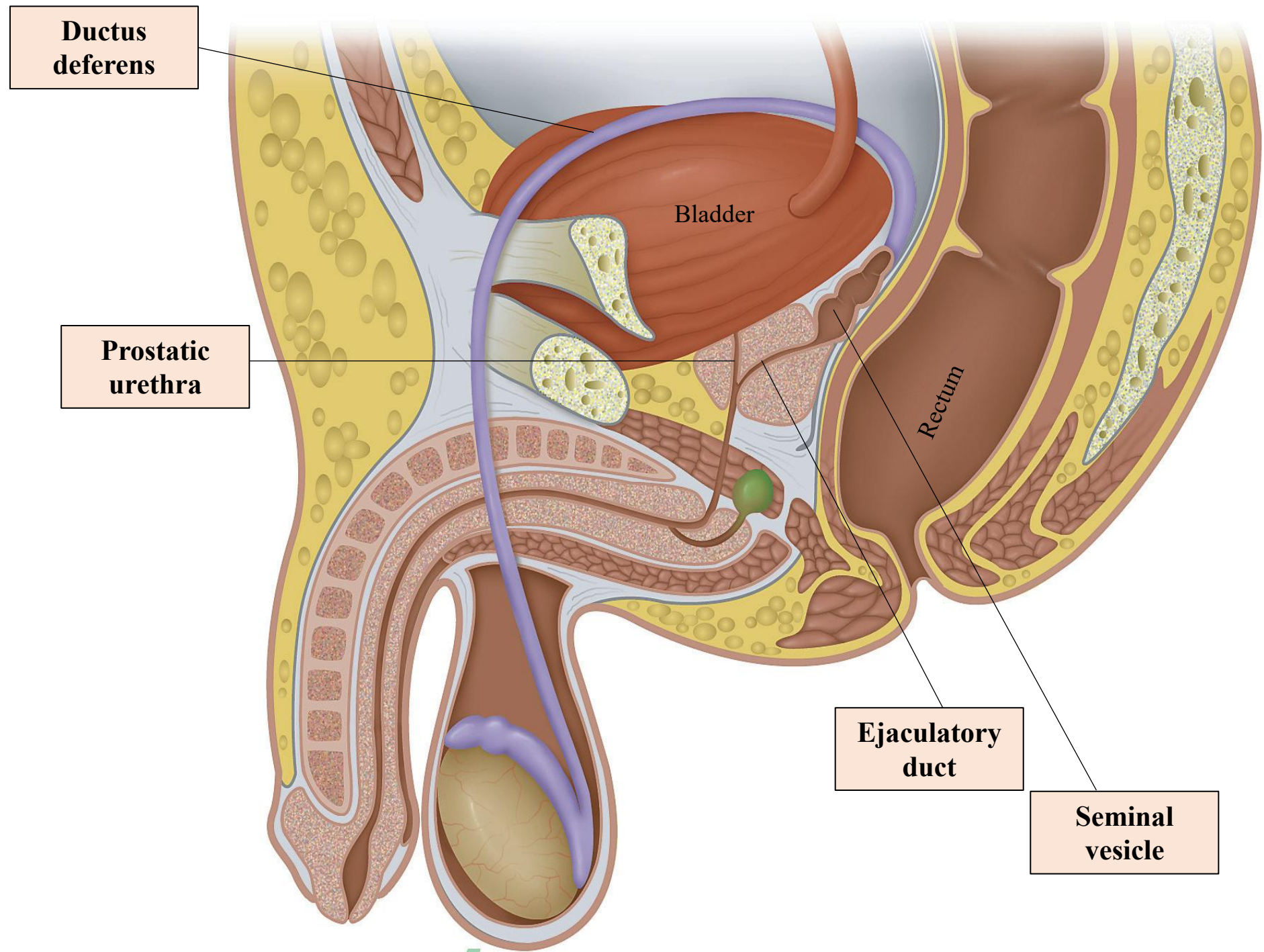
Carries sperm by rapid peristalsis from the epididymis to the ejaculatory ducts



Each ejaculatory duct is formed by the union of the vas deferens with the duct of the seminal vesicle and opens into the prostatic urethra.

Prof. Dr. Heba Kalbouneh

Ejaculatory ducts
Mix sperm and seminal fluid; deliver semen to urethra, where prostatic secretion is added

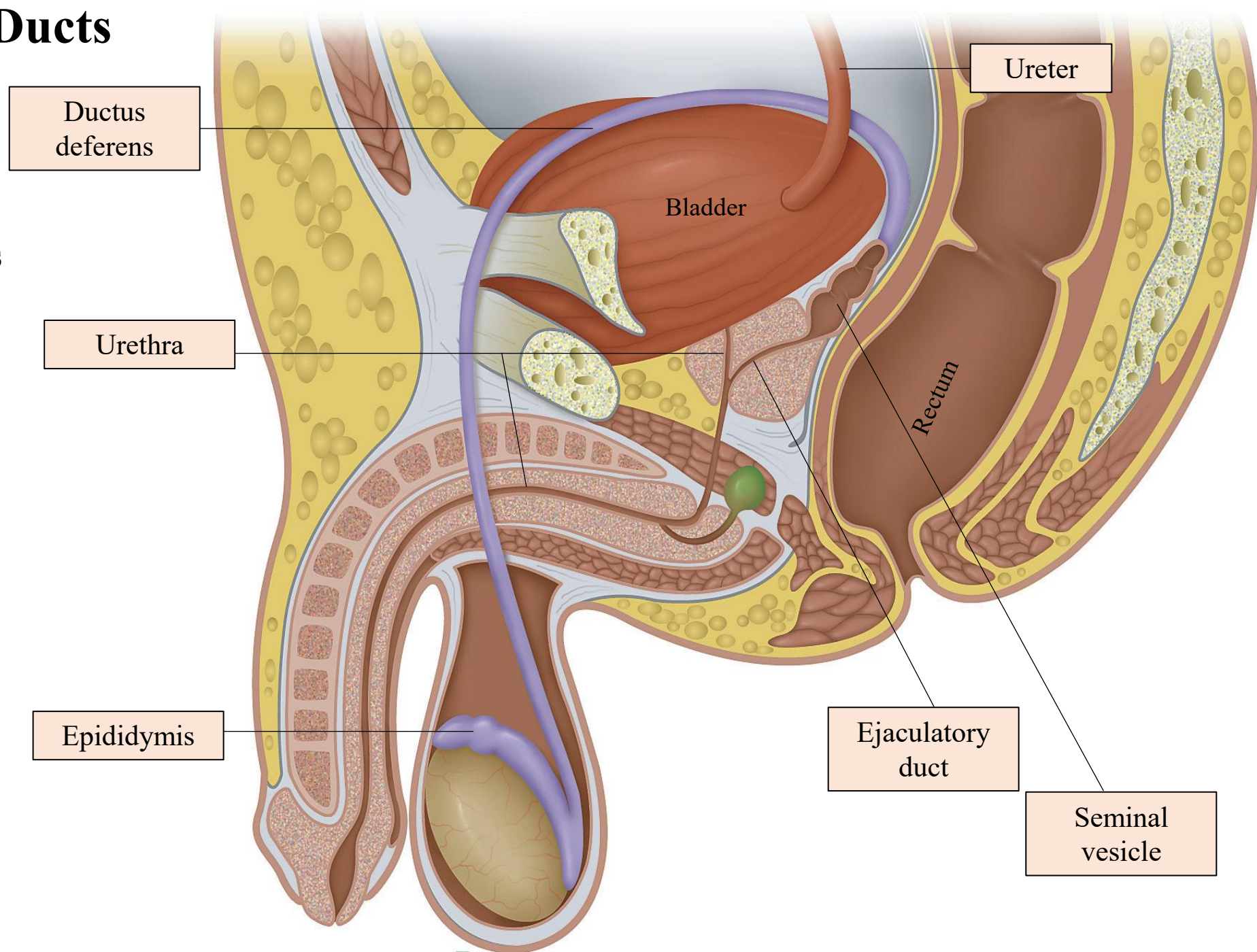


The Extratesticular Ducts

The extratesticular ducts are those of :

- 1- The **epididymis**
- 2- The **ductus (or vas) deferens**
- 3- The **ejaculatory duct**
- 4- The **urethra**

They transport sperm from the scrotum to the penis during ejaculation.



The accessory glands

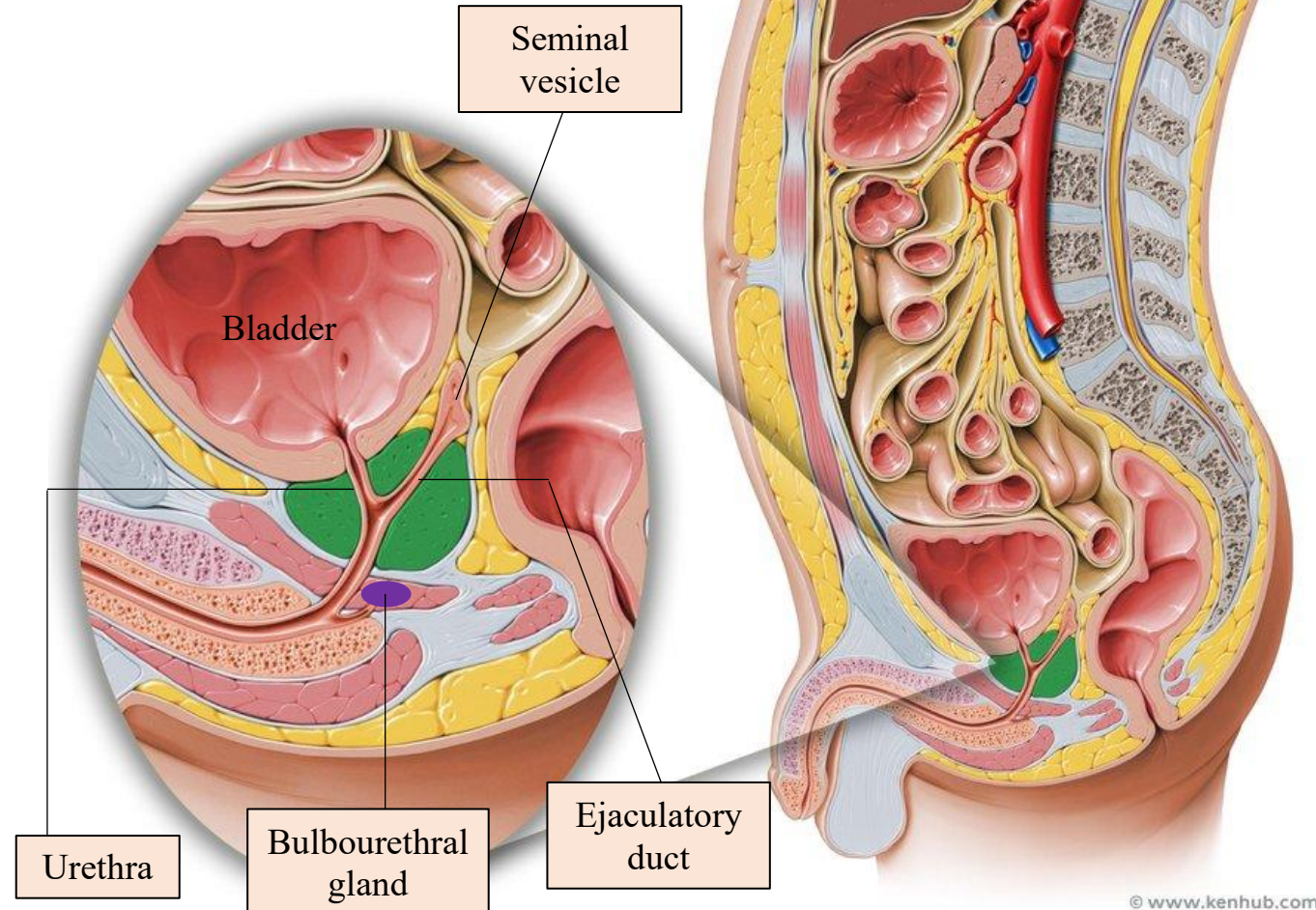
The accessory glands of the male reproductive system consist of:

- 1- Paired **seminal vesicles**
- 2- Paired **bulbourethral glands**
- 3- A single **prostate gland**

These structures produce numerous secretory products that mix with sperm to produce a fluid called semen.

Note:

The prostate gland is a dense organ surrounding the urethra below the bladder.



Test your knowledge

Which of the following accurately describes spermiogenesis?

- a. Occurs before puberty
- b. Involves stem cells, meiosis, and spermatogenesis
- c. Involves cytodifferentiation of early spermatids
- d. Occurs in diploid cells
- e. Results in the formation of primary spermatocytes

Interstitial cells of Leydig have an important function in male gamete production. Because of this function, which of the following organelles is abundant within these cells?

- a. Lysosomes
- b. Smooth endoplasmic reticulum
- c. Peroxisomes
- d. Polyribosomes
- e. Golgi complexes

A 20-year-old man contracts cholera during a long tour of military duty in a remote, completely undeveloped region. After a 5-day period of severe diarrhea and treatment, he gradually recovers and slowly returns to work. He is married 3 years later but after a few years of trying to conceive a child, semen analysis reveals that his sperm are few in number and malformed, and blood tests show a high titer of antibodies against sperm antigens. The causative agent of cholera, *Vibrio cholera*, secretes a toxin that interferes with tight (occluding) junctions. What cells in the gonad are the likely target of this toxin in the male reproductive system?

- a. Spermatogonia
- b. Sertoli cells
- c. Myoid cells
- d. Interstitial cells of Leydig
- e. Differentiating spermatozoa

A 39-year-old man undergoing an extensive series of tests for infertility is found to have a genetic mutation preventing formation of a protein structure that mediate chromosome synapsis and recombination during meiosis, causing almost complete failure of sperm formation. Which cells would be directly affected by this mutation?

- a. Primary spermatocytes
- b. Spermatogonia
- c. Secondary spermatocytes
- d. Spermatids
- e. Cells undergoing spermiogenesis

What is the stage of the large cells with pale cytoplasm?

