



Introduction to Anatomy

Practical Lab

1st year Medical Students

2025-2026

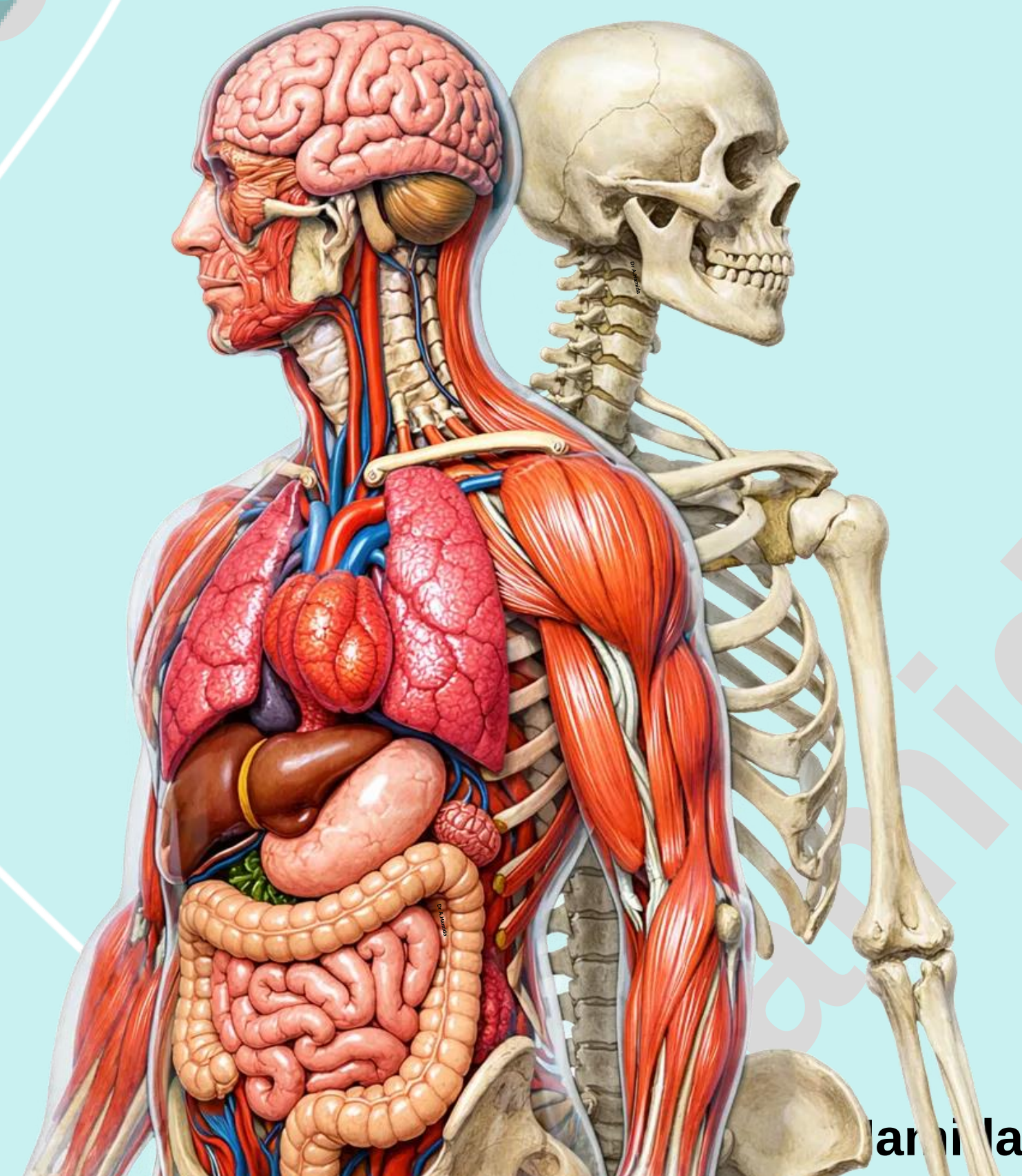
Second Semester

Dr. Abedallah Hamida, MBBS, PhD

Department of Anatomy and Histology

School of Medicine-The University of Jordan

a_hamida@ju.edu.jo



Hamida

Practical Lab-4

Upper Limb Bones

- 1. Humerus (distal end)**
- 2. Radius**
- 3. Ulna**
- 4. Hand bones**

Check List: Upper Limb Bones

Practical Lab-4

1. Humerus (distal end)

- ✓ Outline the major parts of distal (lower) end of the humerus:
 - Condyles: Capitulum, Trochlea;
 - Epicondyles: Medial epicondyle, Lateral epicondyle;
 - Supracondylar Ridges: Medial supracondylar ridge, Lateral supracondylar ridge;
 - Fossae: Radial fossa, Coronoid fossa, Olecranon fossa

2. Radius

- ✓ Identify the shape and anatomical location of the radius
- ✓ Outline the major parts of the radius:
 - **Proximal (upper) end**: Head, Neck, Radial Tuberosity;
 - **Shaft**: Interosseous border;
 - **Distal (lower) end**: styloid process, ulnar notch

Check List: Upper Limb Bones

Practical Lab-4

3. Ulna

- ✓ Identify the shape and anatomical location of the ulna
- ✓ Outline the major parts of the ulna:
 - **Proximal (upper) end:** Olecranon Process, Coronoid Process, Trochlear Notch, Radial Notch
 - **Shaft:** Interosseous border
 - **Distal (lower) end:** Head, Styloid process

4. Hand Bones

- ✓ Outline the major parts of the hand:
 - wrist or carpus, hand proper (or metacarpus), **and** digits (thumb and fingers).

4.1 Carpal bones

- ✓ Outline the names and type of the carpal bones.
 - **Proximal row (lateral → medial):** Scaphoid, Lunate, Triquetrum, Pisiform
 - **Distal row (lateral → medial):** Trapezium, Trapezoid, Capitate, Hamate

4.2 Metacarpal bones

- ✓ Outline the number and type of metacarpal bones.

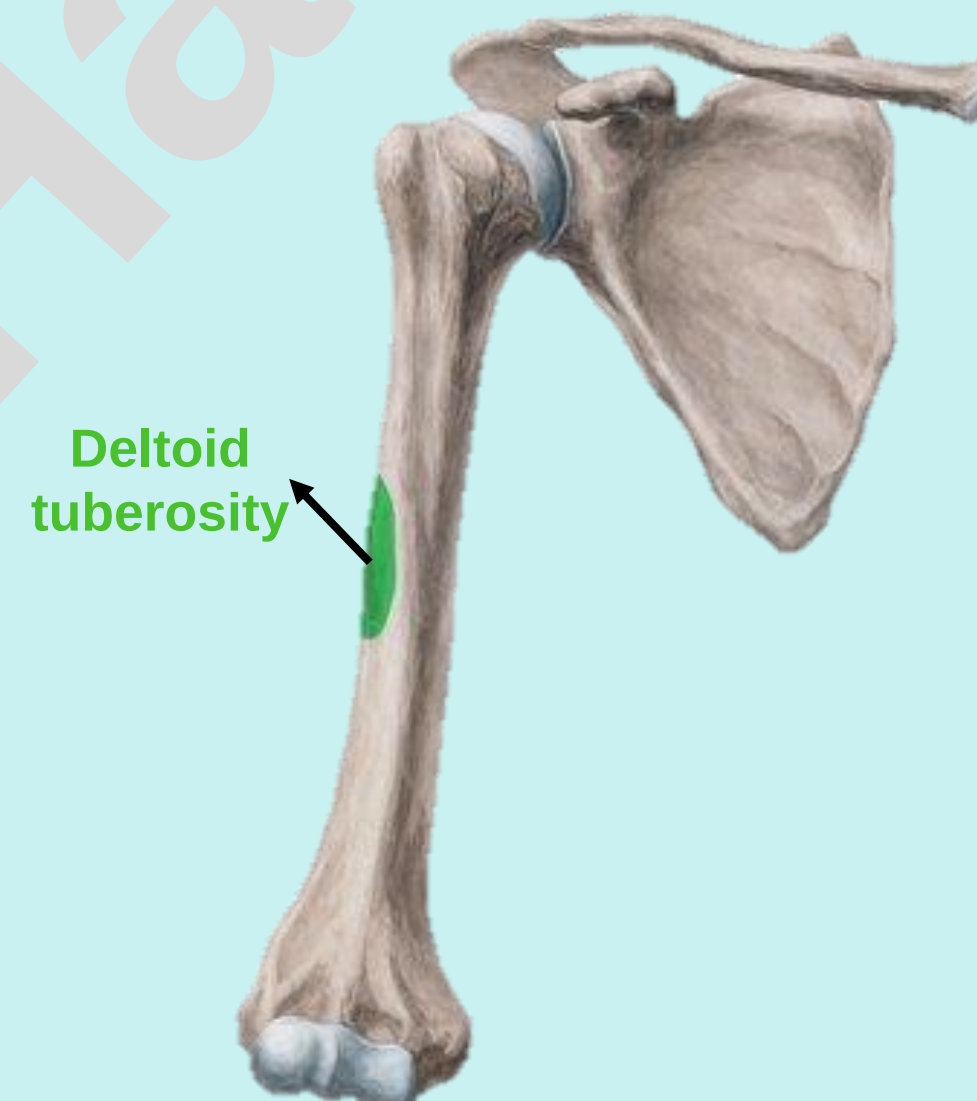
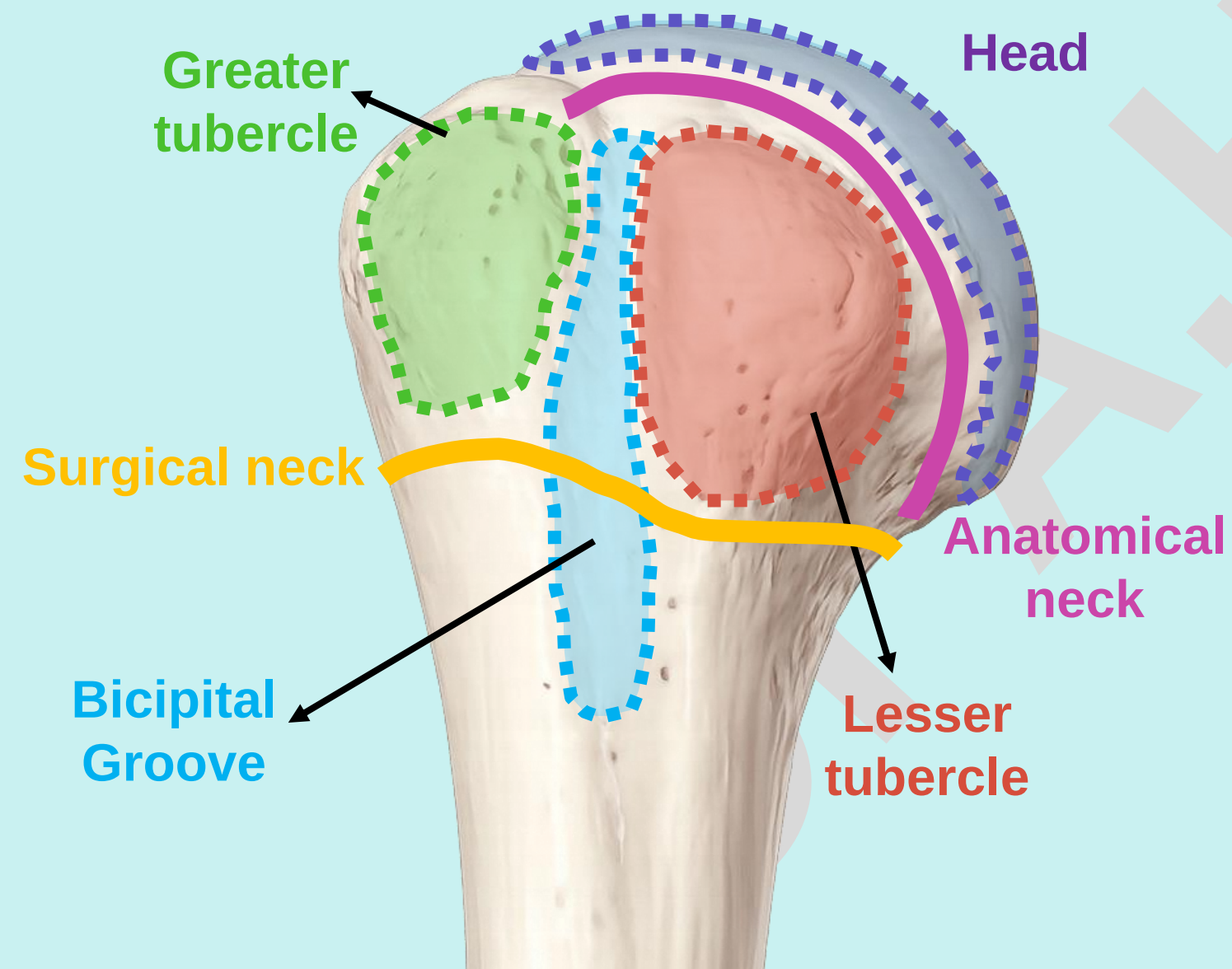
4.3 Digits

- ✓ Outline the number of phalanges in each digit.

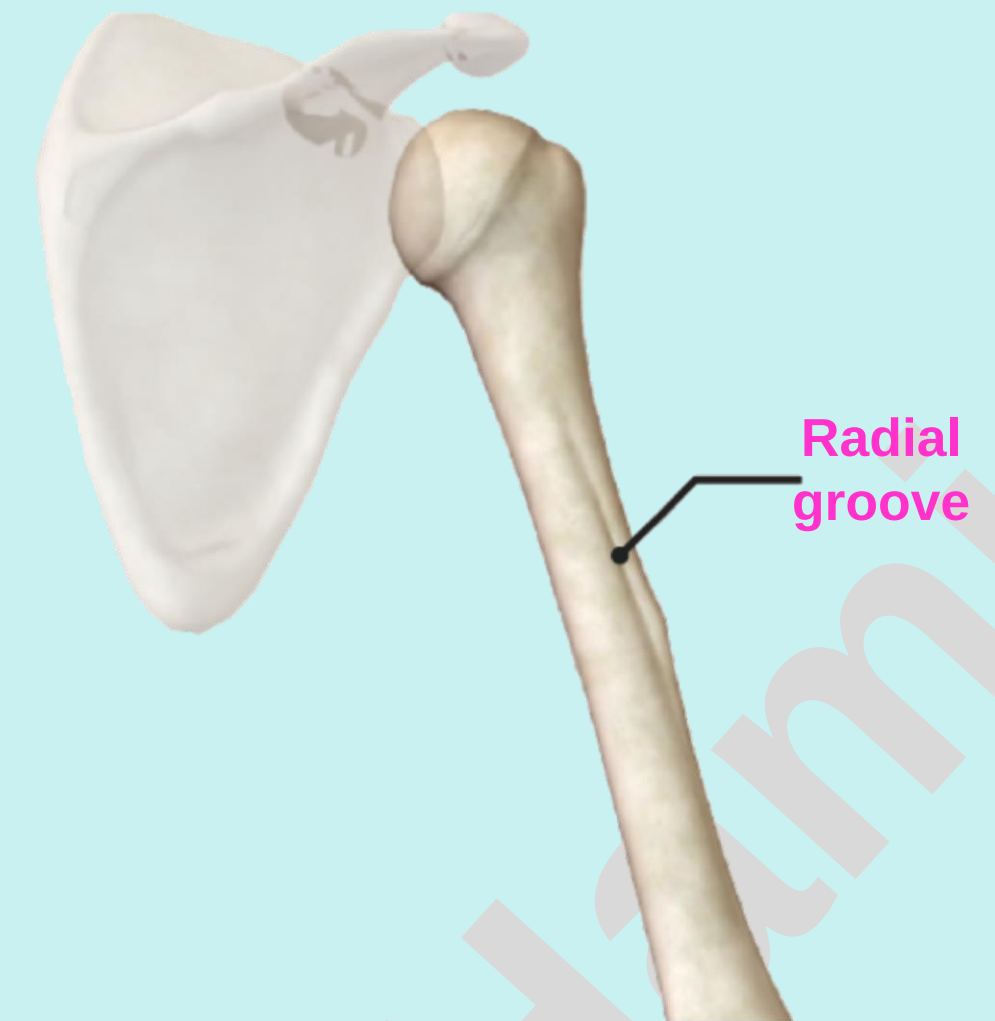
Check List:

1. Humerus (distal end)

- ✓ Revise the shape and anatomical location of the humerus.
- ✓ Revise the parts of the proximal end and the shaft of the humerus:
 - **Proximal (upper) end** (Head, Anatomical neck, Greater tubercle, Lesser tubercle, Bicipital Groove, and Surgical neck),
 - **Shaft** (Deltoid tuberosity and Radial groove)



Anterior view



Posterior view

Check List:

1. Humerus (distal end)

Distal (lower) End: Identify the following features of the distal end:

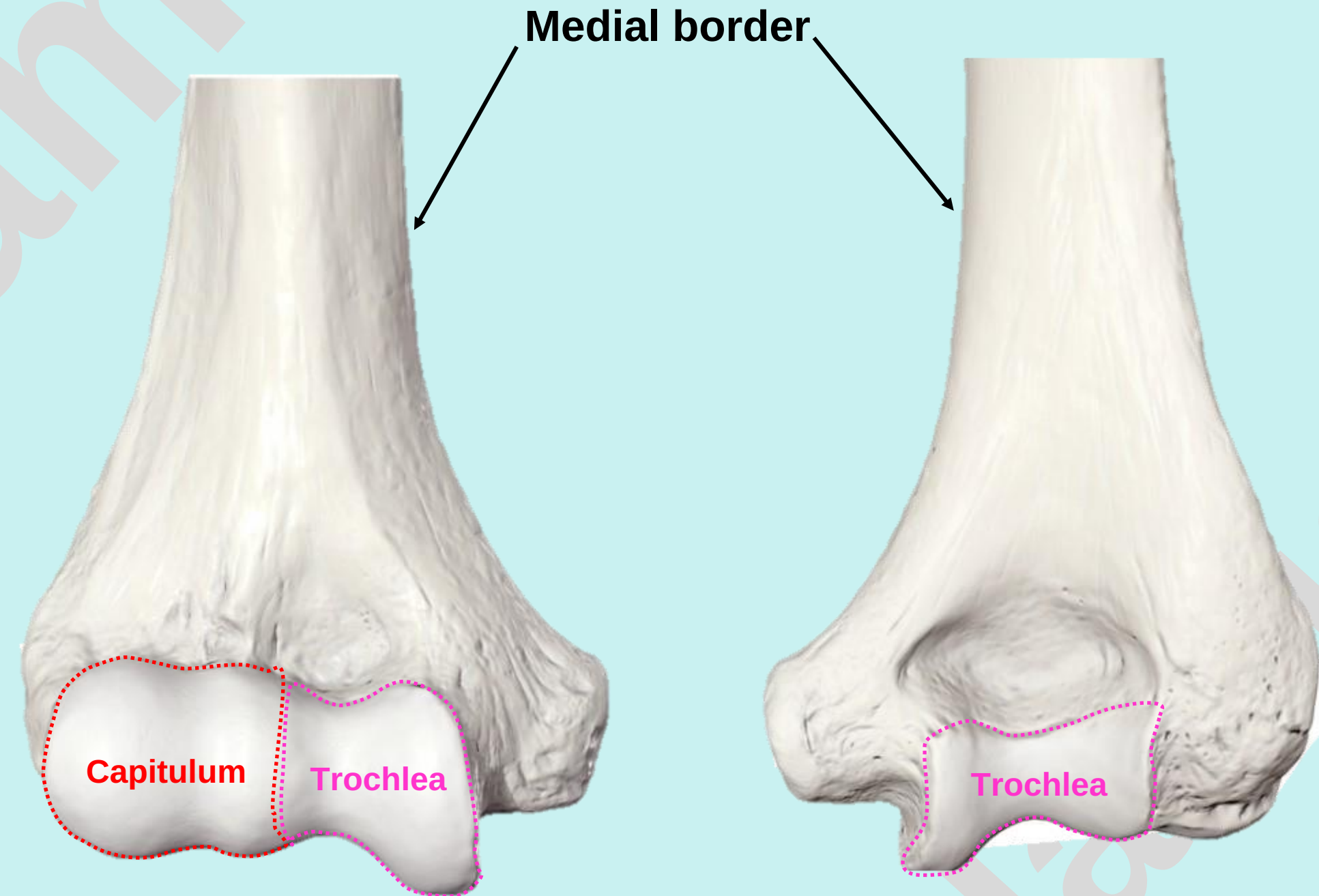
- Two Condyles:

1. Capitulum

- A rounded lateral convex projection.
- Articulates with the head of the radius.

2. Trochlea

- A medial pulley-shaped structure.
- Articulates with the trochlear notch of the ulna.



Anterior view

Posterior view

Condyle: is a rounded articular prominence at the end of a bone

Check List:

1. Humerus (distal end)

Distal (lower) End: Identify the following features of the distal end:

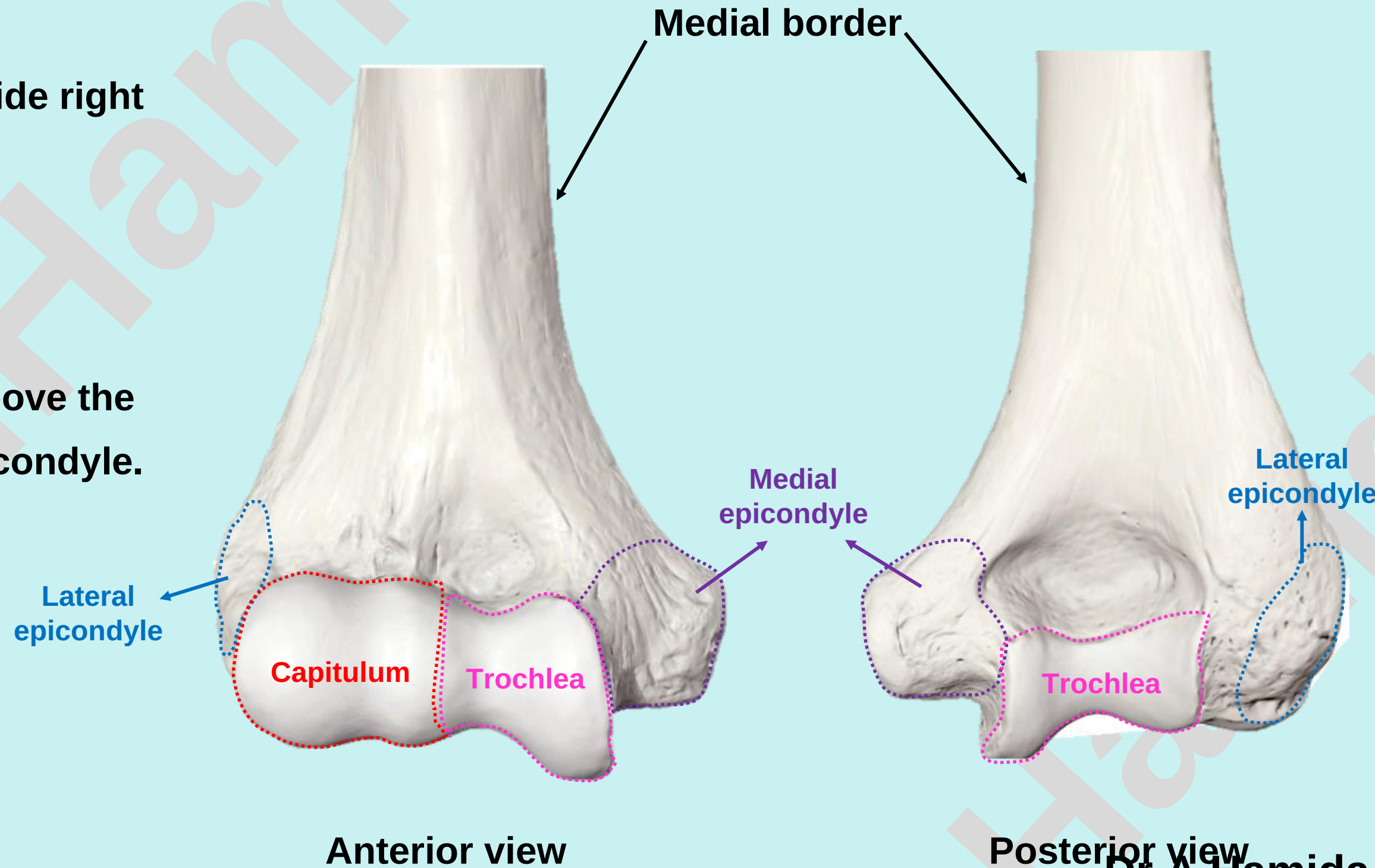
- Two Epicondyles:

1. **Medial epicondyle**

- A prominent projection on the medial side right above the trochlea

2. **Lateral epicondyle**

- A projection on the lateral side right above the Capitulum, smaller than the medial epicondyle.



Check List:

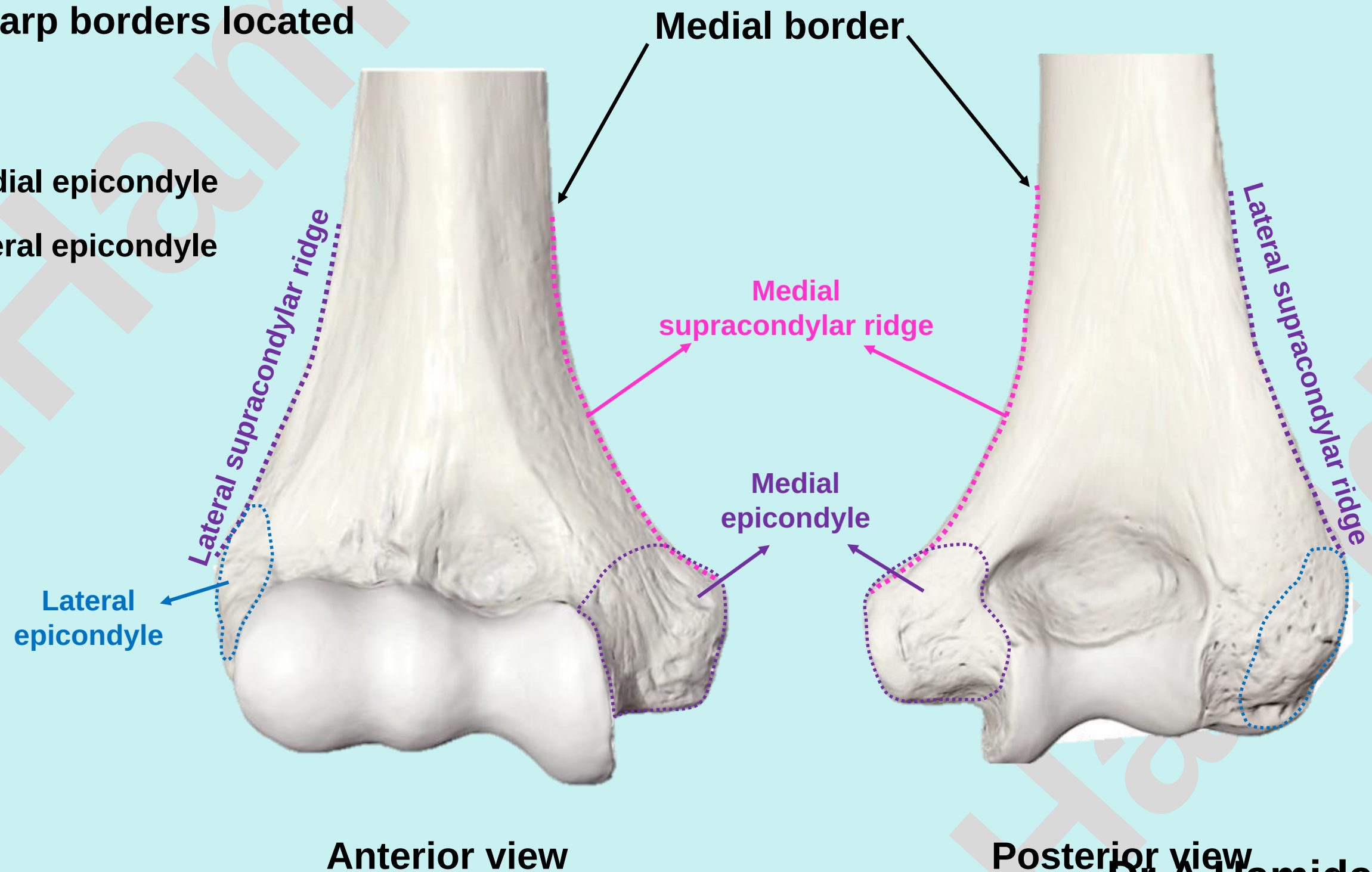
1. Humerus (distal end)

Distal (lower) End: Identify the following features of the distal end:

- Two Supracondylar Ridges:

The distal part of the shaft presents two sharp borders located above the epicondyles:

1. **Medial supracondylar ridge:** above the medial epicondyle
2. **Lateral supracondylar ridge:** above the lateral epicondyle



Check List:

1. Humerus (distal end)

Distal (lower) End: Identify the following features of the distal end:

- Three Fossae:

- 1. **Radial fossa:**

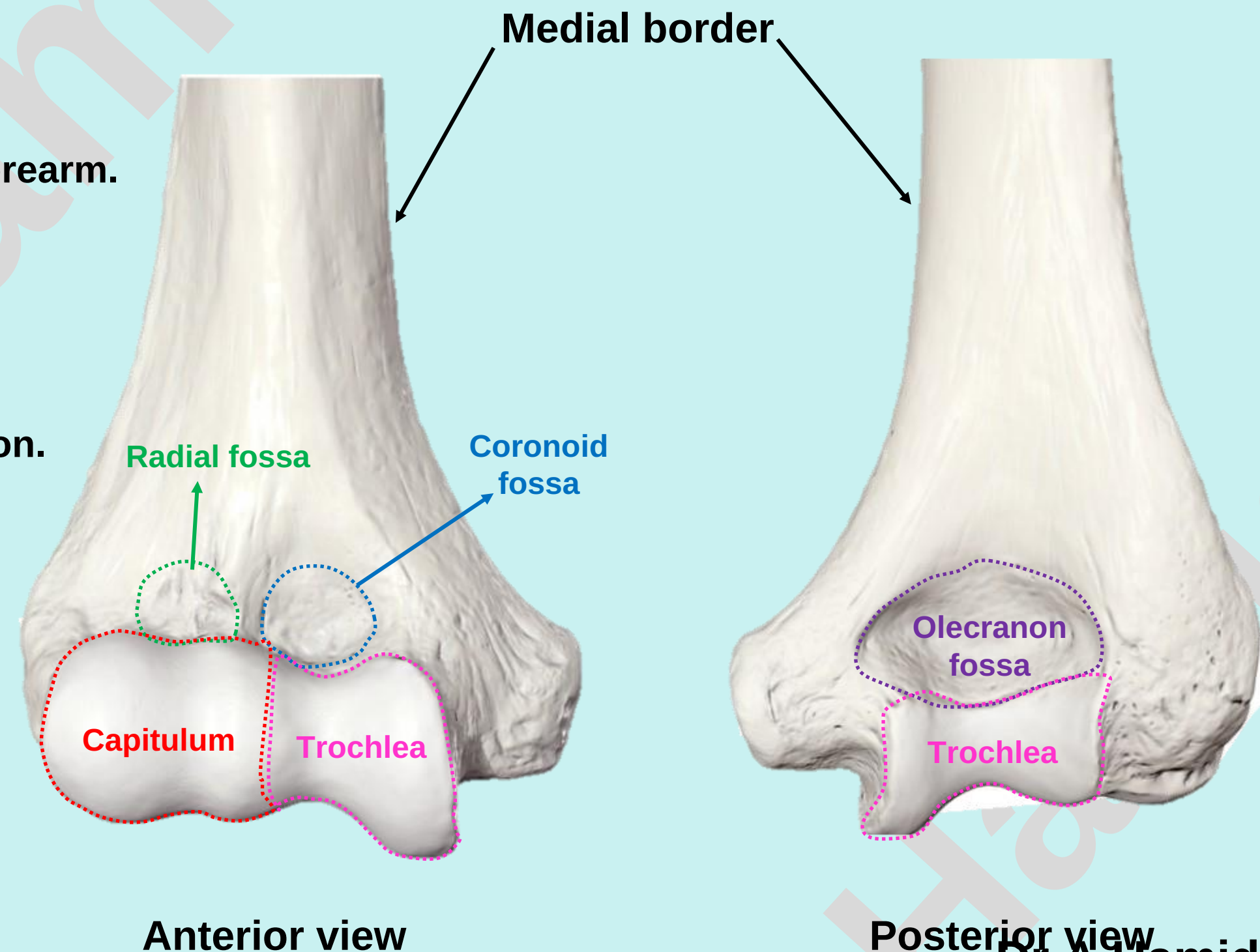
- Small anterior fossa above the capitulum.
- Receives the head of the radius during flexion of the forearm.

- 2. **Coronoid fossa:**

- Small anterior fossa above the trochlea.
- Receives the coronoid process of the ulna during flexion.

- 3. **Olecranon fossa**

- Large deep posterior fossa above the trochlea.
- Receives the olecranon of the ulna during extension.



Check List:

Practical Lab-4

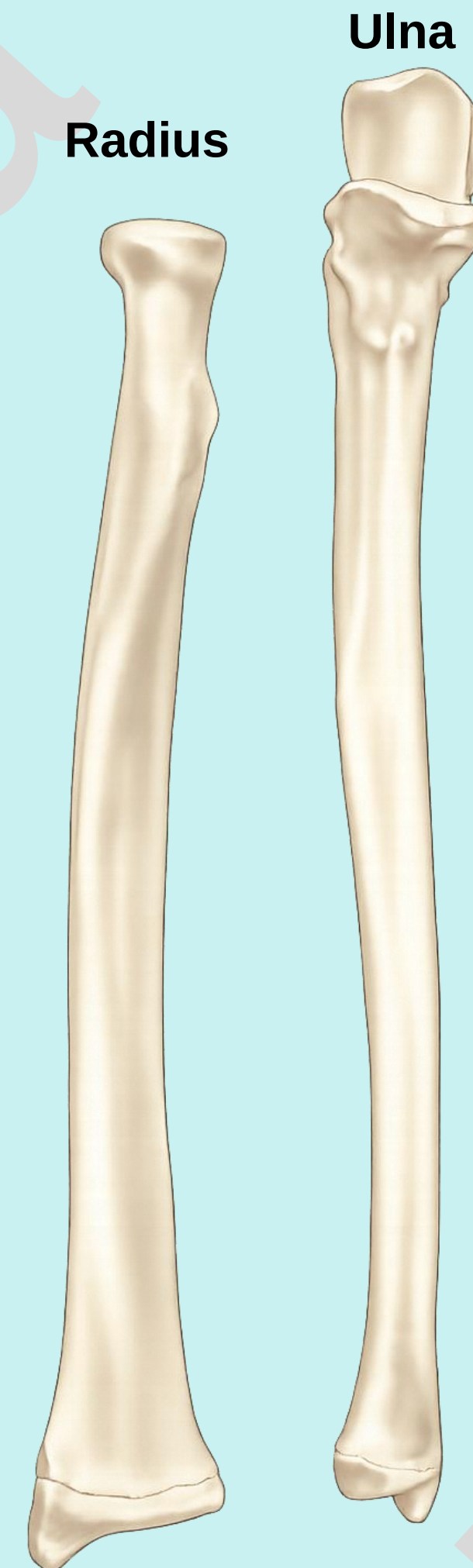
1. Humerus

- ✓ Determine the side and anatomical position by holding it vertically in such a way that:
 1. The rounded head at the upper end faces medially.
 2. The lesser tubercle and bicipital groove at the upper end face anteriorly.
 3. The olecranon fossa on the lower end faces posteriorly.

Check List:

Radius and Ulna

- ✓ Note that the radius is narrow proximally and wider distally, whereas the ulna is wide proximally and narrow distally.



Practical Lab-4

Check List:

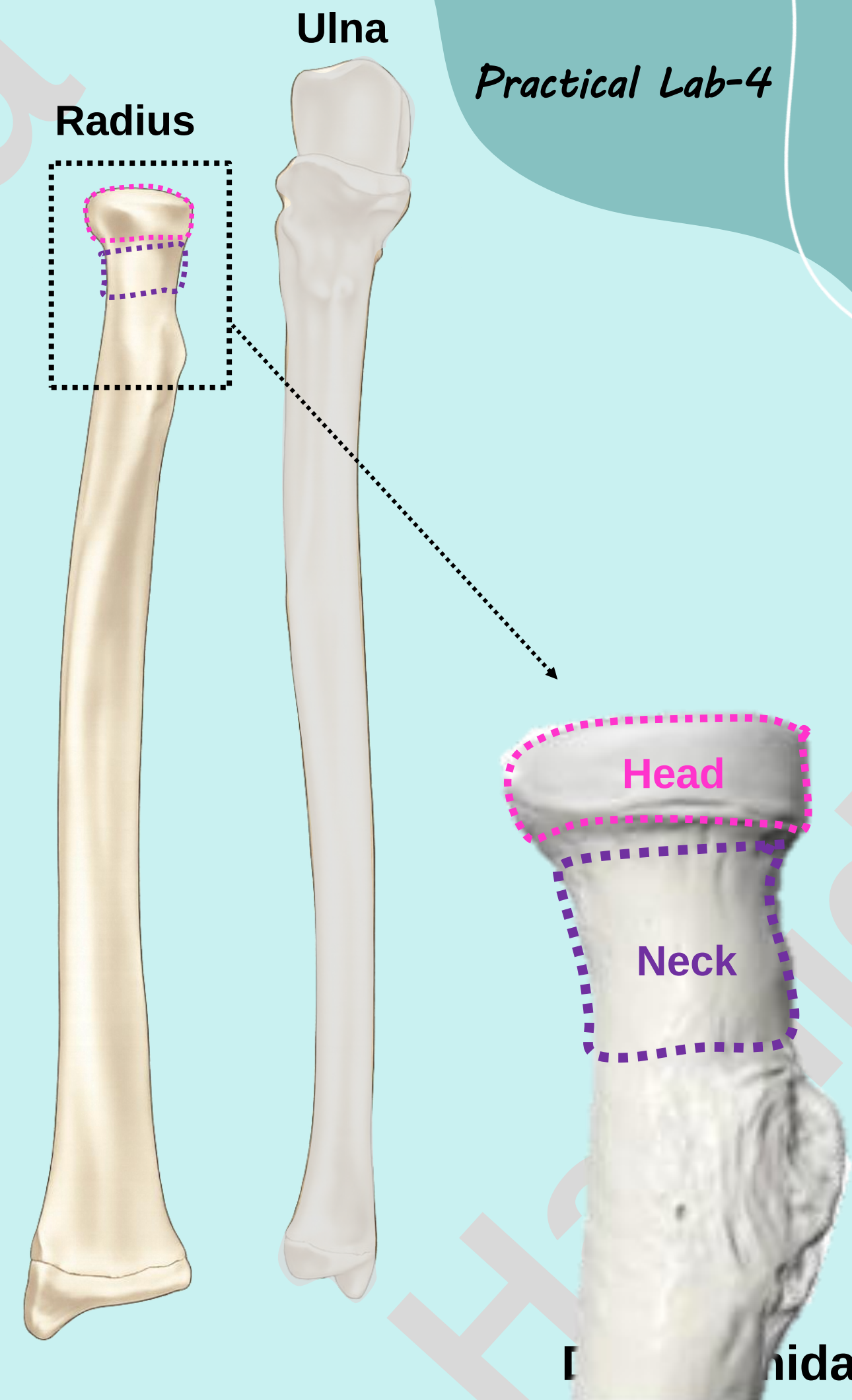
Practical Lab-4

2. Radius

- ✓ Identify the type and anatomical location of the radius.
- ✓ Outline the major parts of the radius: Proximal (upper) end, Shaft, and Distal (lower) end

1. Proximal (Upper) End: Identify the following features of the proximal end:

- **Head:** Disc-shaped
 - Articulates superiorly with the capitulum of the humerus to form the elbow joint
 - Articulates medially with the radial notch of the ulna to form the proximal radioulnar joint
- **Neck:** A constricted part below the head



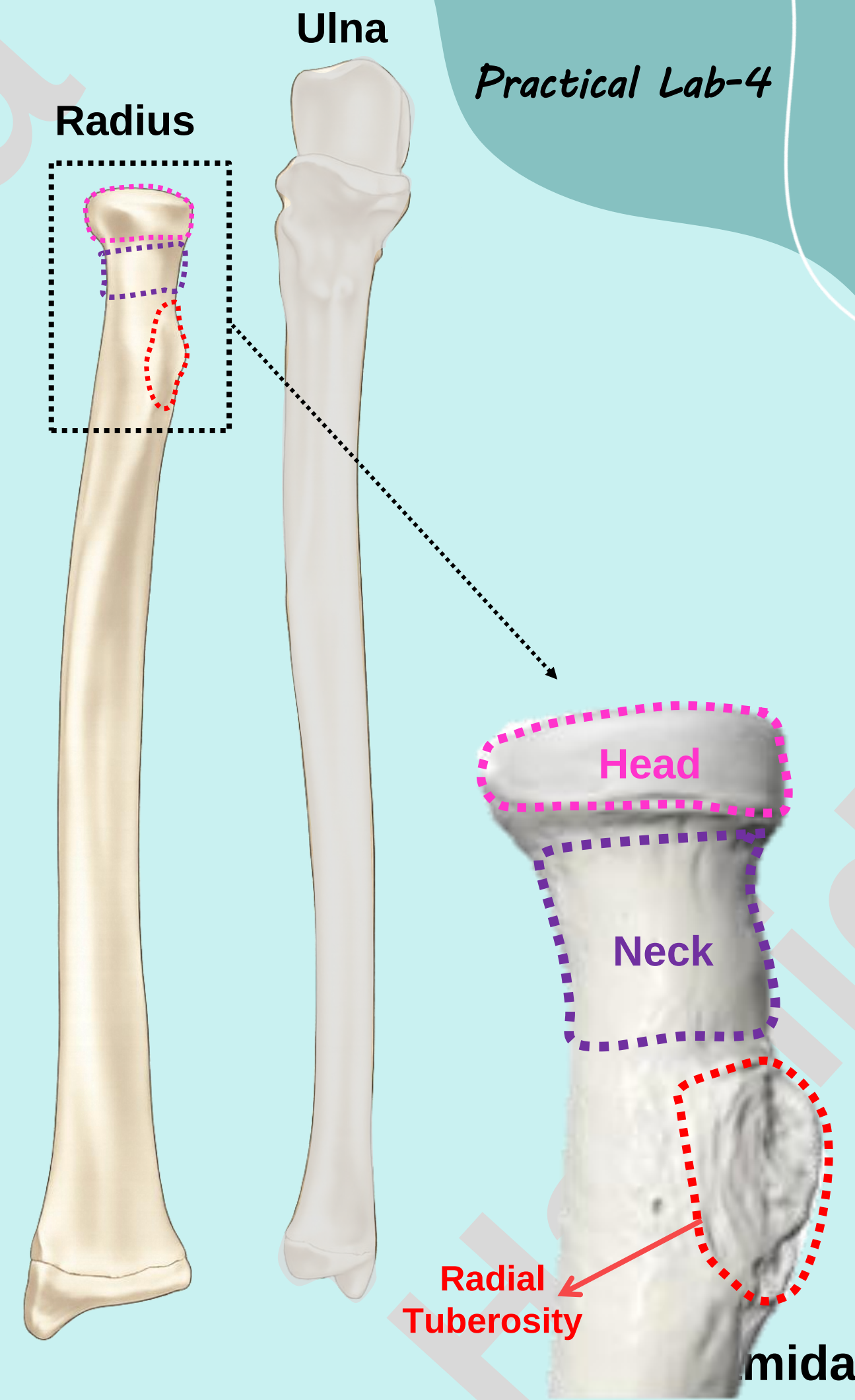
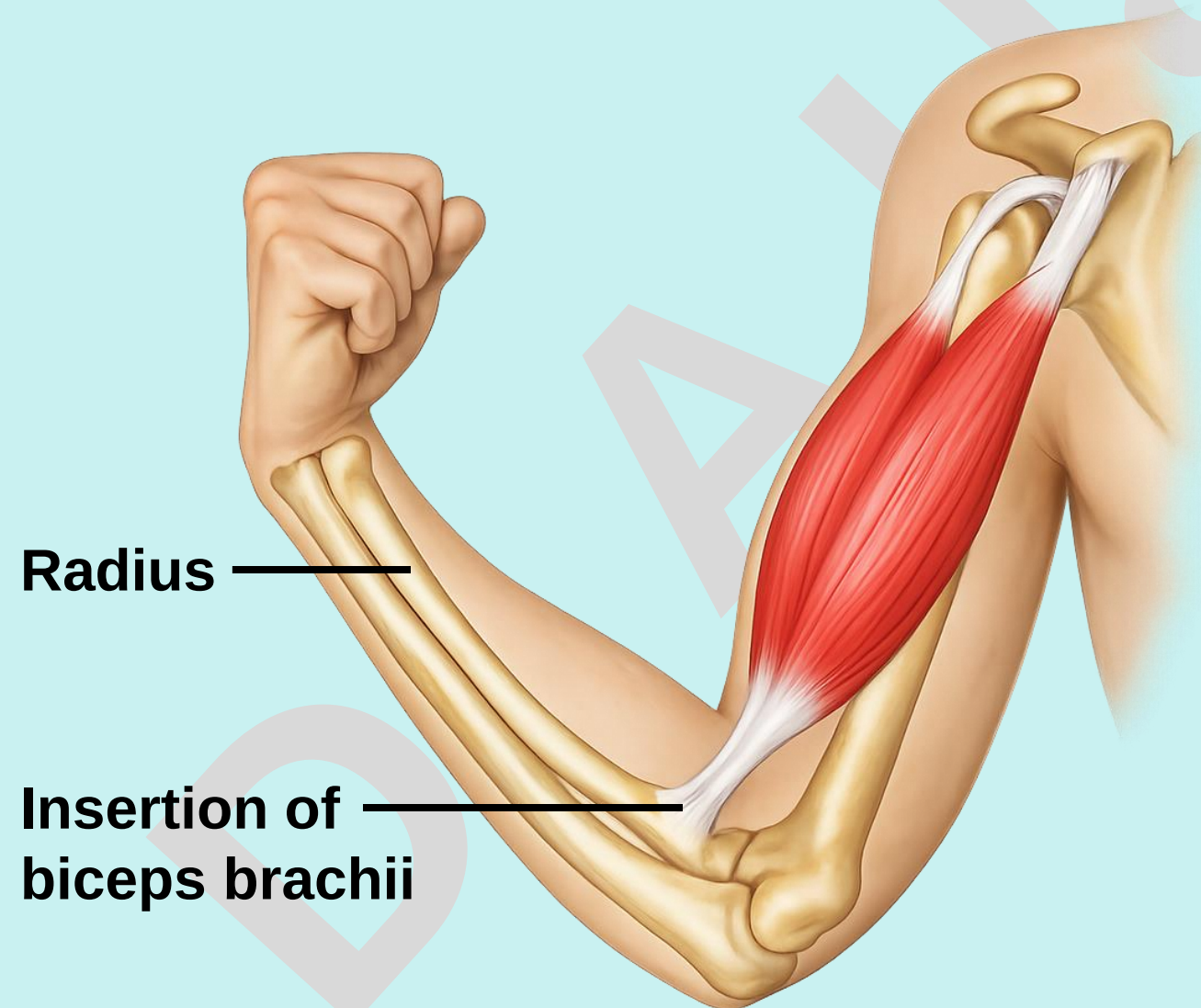
Check List:

2. Radius

✓ Outline the major parts of the radius:

1. **Proximal (Upper) End:** Identify the following features of the proximal end:

- **Radial Tuberosity:**
 - Located just below the medial side of the neck.
 - Site of biceps brachii insertion.



Check List:

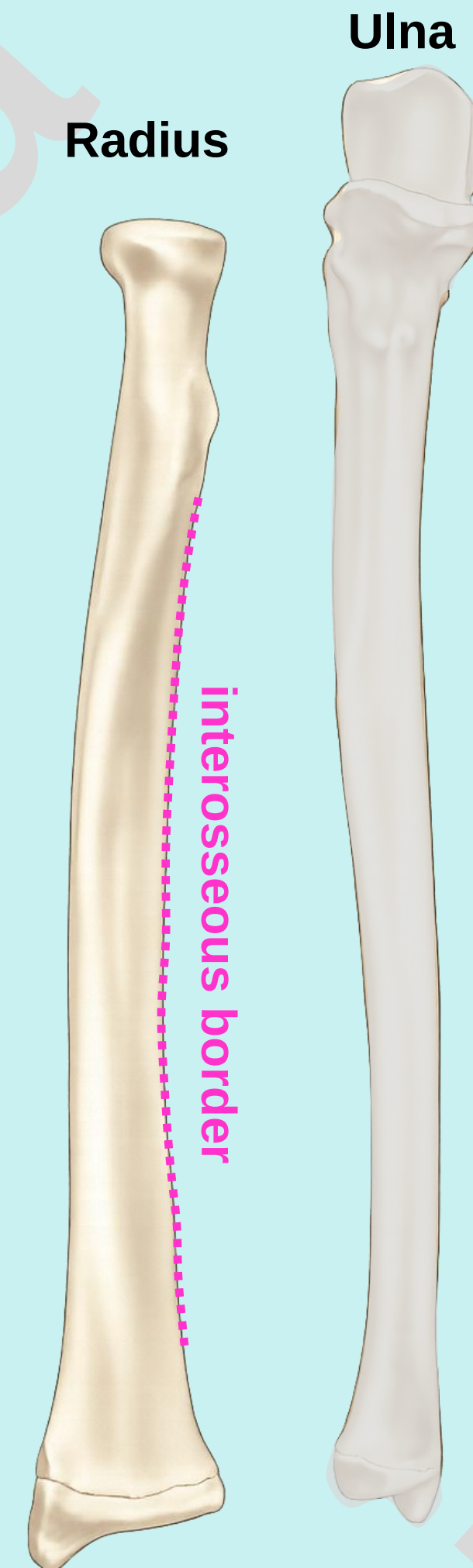
Practical Lab-4

2. Radius

✓ Outline the major parts of the radius:

2. Shaft:

- Extends between the proximal and distal ends.
- Shows a slight lateral convexity
- Has a sharp medial border called the **interosseous border**



Check List:

Practical Lab-4

2. Radius

✓ Outline the major parts of the radius:


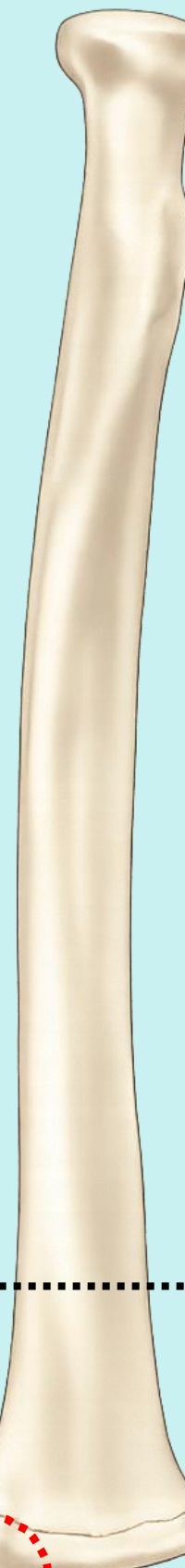
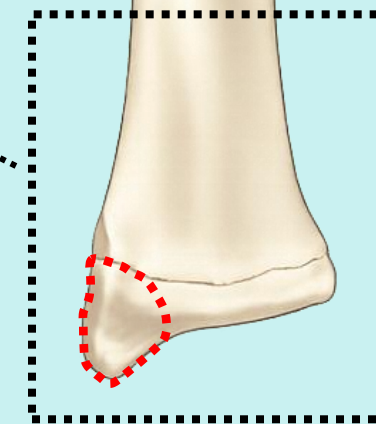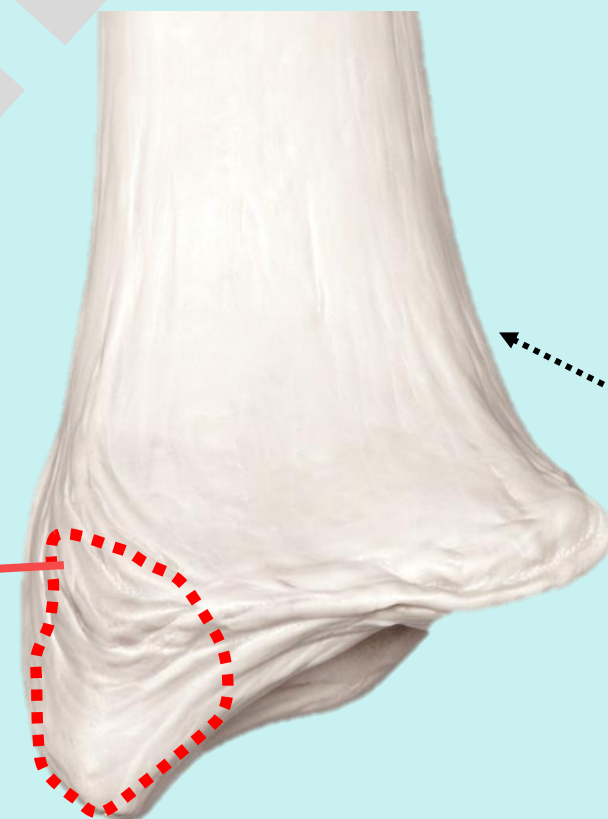
3. Distal (lower) end: Identify the following features of the distal end:

- Styloid process:
 - Lateral surface of the distal end projects downward as the styloid process (palpable proximal to the thumb)

Radius

Ulna

styloid process



Check List:

2. Radius

✓ Outline the major parts of the radius:

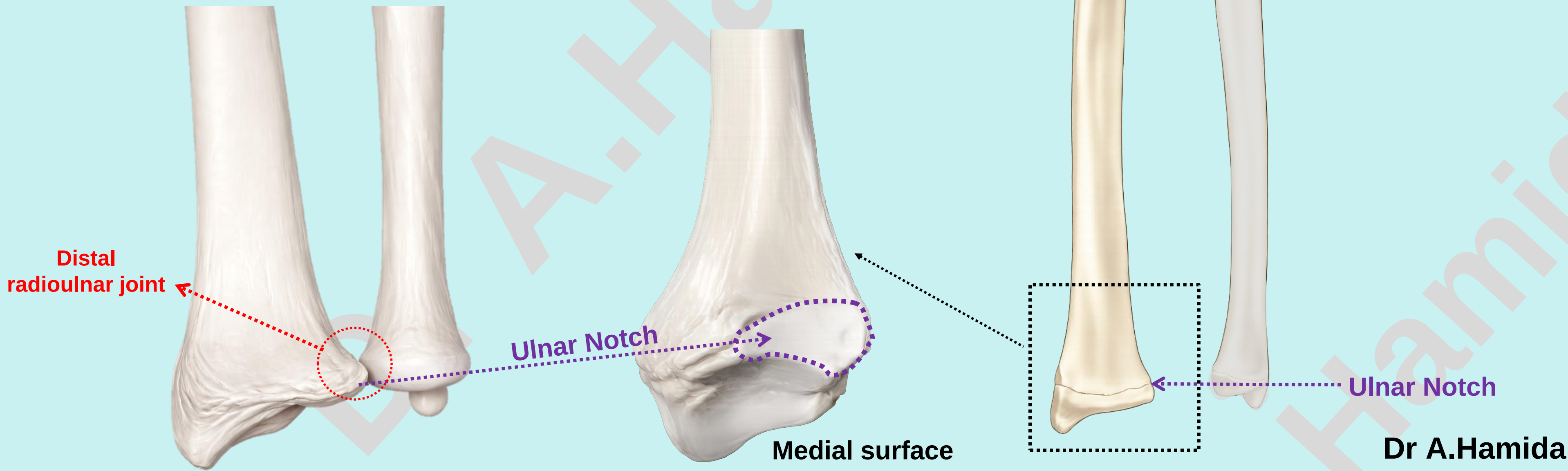
3. **Distal (lower) end:** Identify the following features of the distal end:

- Ulnar Notch:

- The medial surface of the distal end presents the ulnar notch, which articulates with the head of the ulna to form the distal radioulnar joint.

Radius

Ulna



Check List:

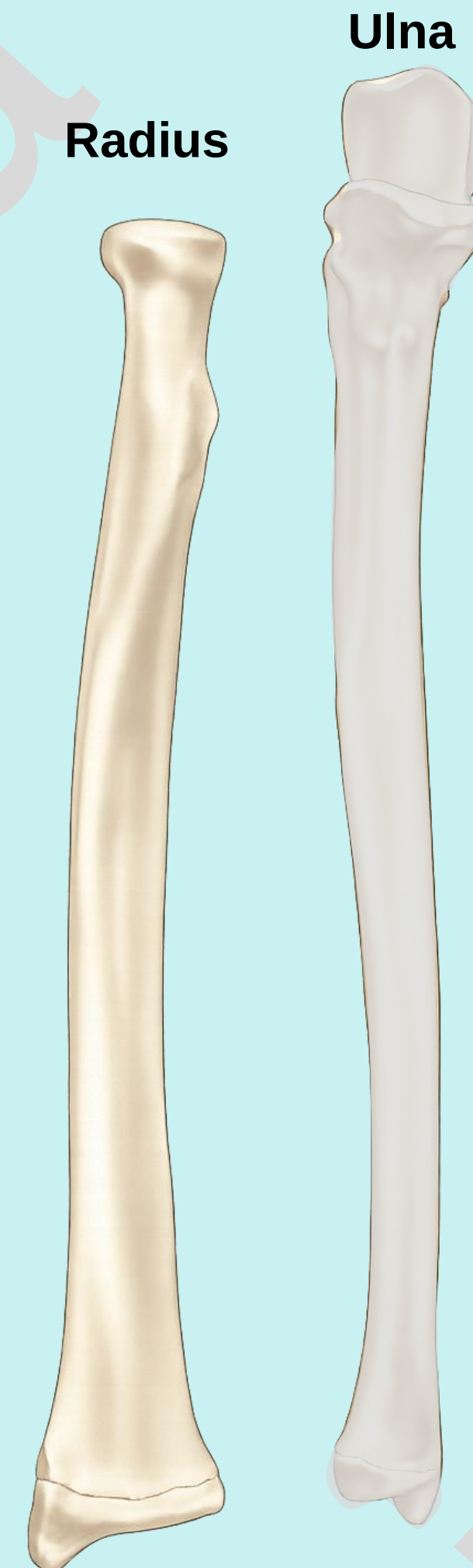
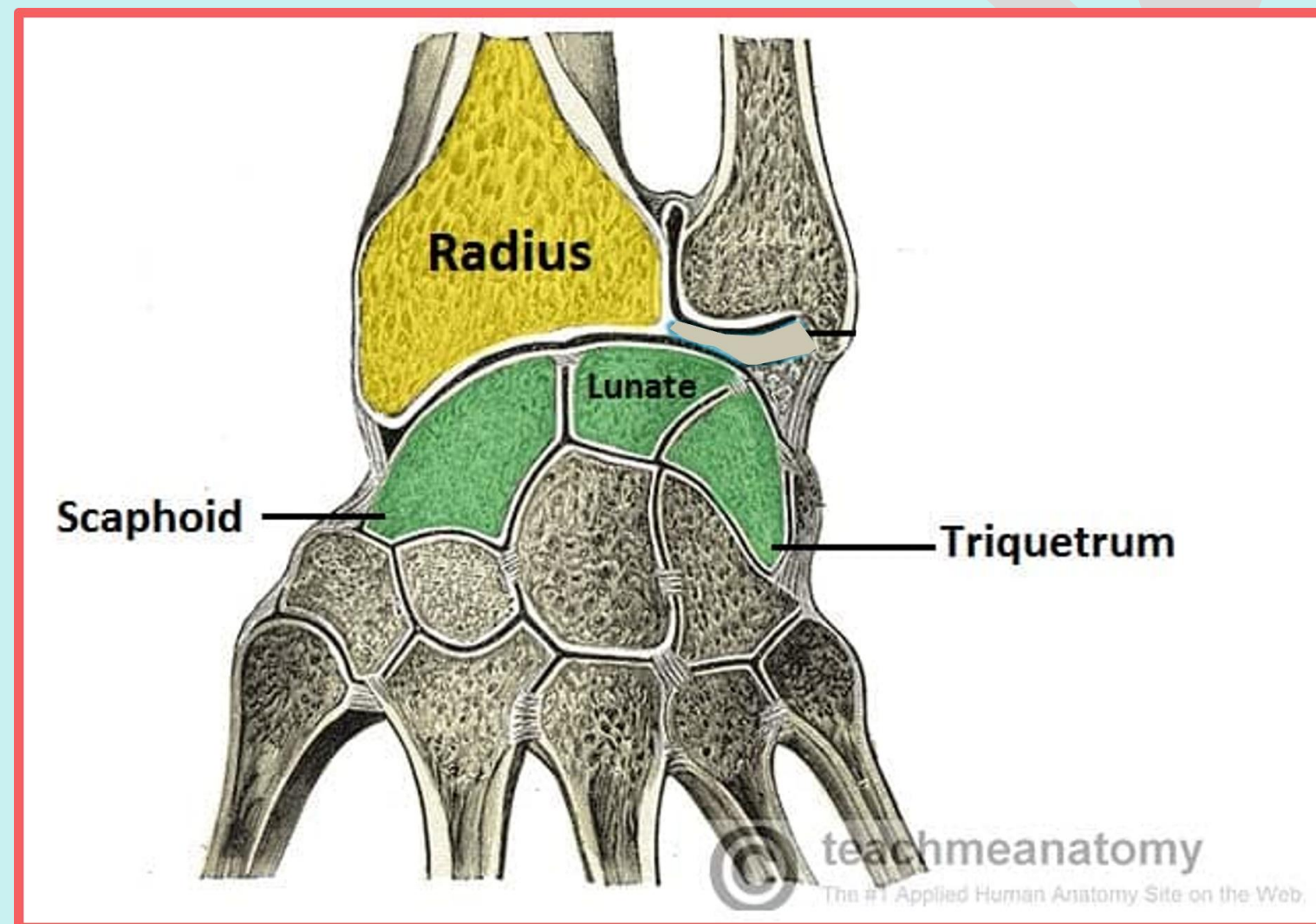
Practical Lab-4

2. Radius

✓ Outline the major parts of the radius:

3. **Distal (lower) end:** Identify the following features of the distal end:

- The inferior surface of the distal end of the radius articulates with the scaphoid, lunate and triquetral of the proximal row of carpal bone to form the radiocarpal (wrist) joint.



Check List:

Practical Lab-4

2. Radius

- ✓ Determine the side and anatomical position by holding it vertically in such a way that:
 1. The head is directed upwards.
 2. The sharpest border (interosseous border) of the shaft is kept medially.
 3. The styloid process at the lower end is directed laterally.

Check List:

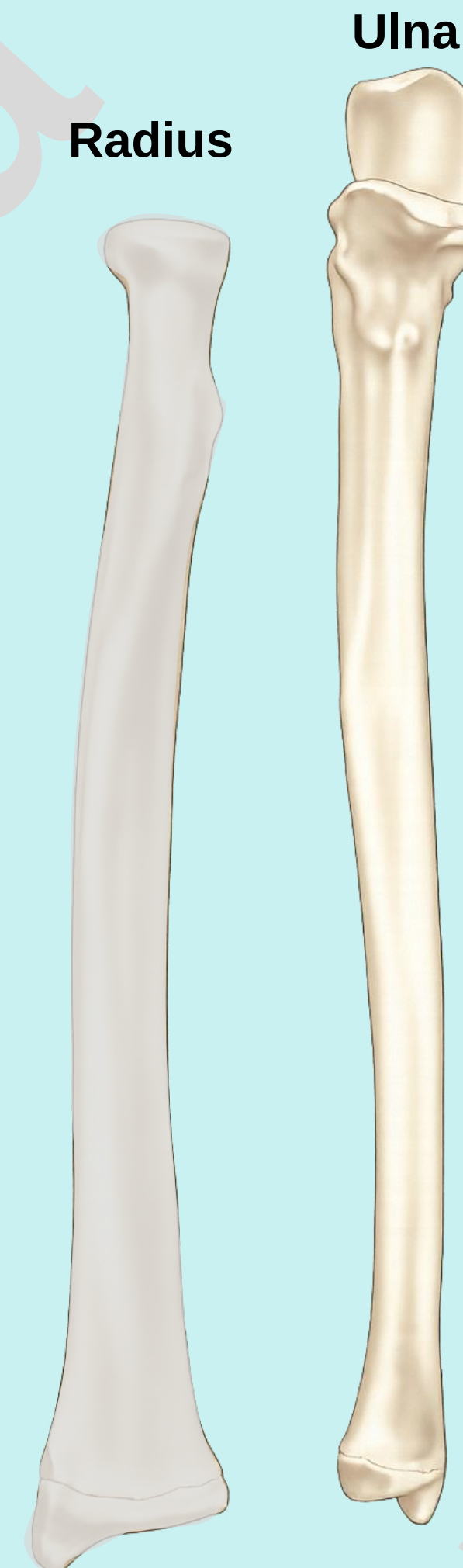
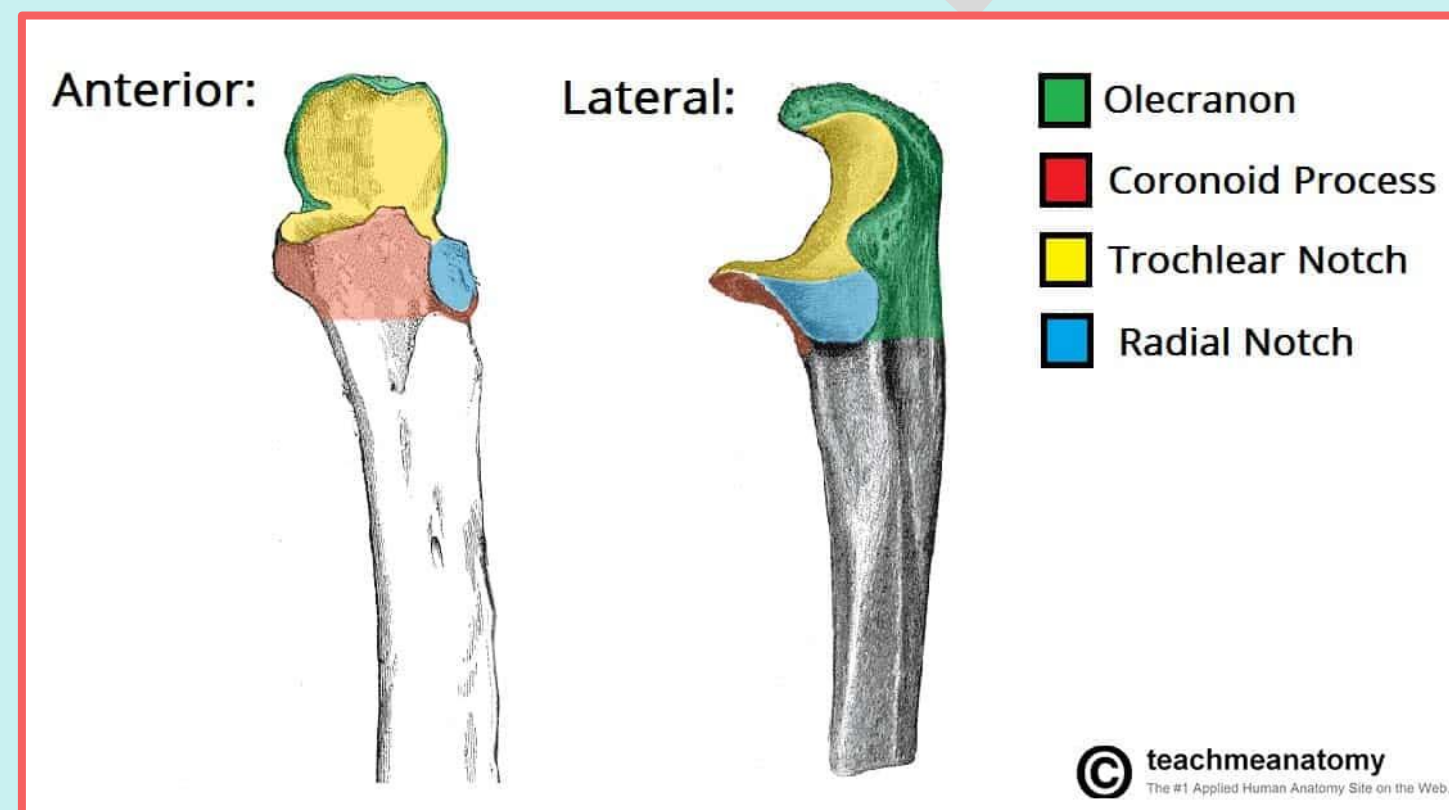
Practical Lab-4

3. Ulna

- ✓ Identify the type and anatomical location of the ulna.
- ✓ Outline the major parts of the ulna: Proximal (upper) end, Shaft, and Distal (lower) end.

1. Proximal (Upper) End:

- The proximal end is expanded and hook-shaped (C-shaped), with the concavity facing anteriorly.
- It has two processes (coronoid and olecranon), and two notches (trochlear and radial).



Check List:

3. Ulna

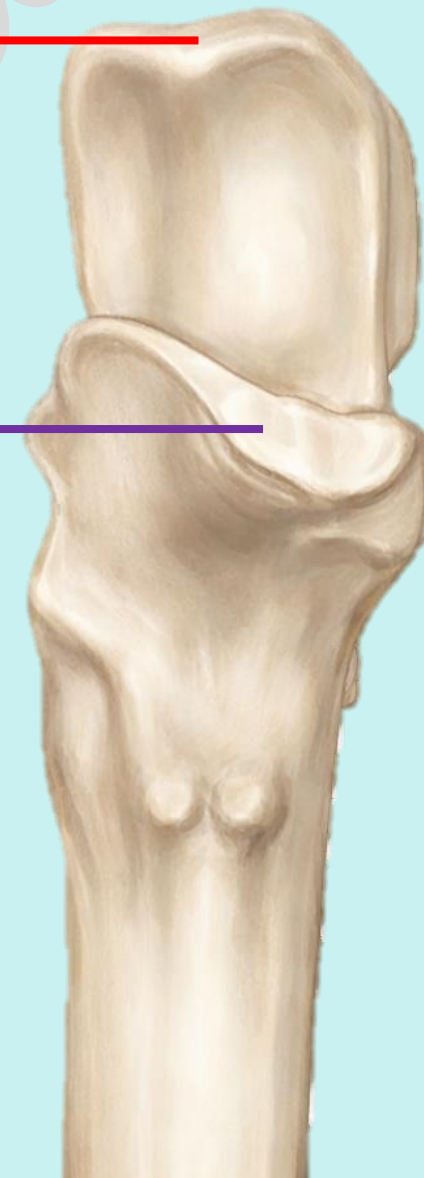✓ Outline the major parts of the ulna:

1. Proximal (Upper) End:

- **Olecranon Process**: Large superior projection
- **Coronoid Process**: Smaller lower projection

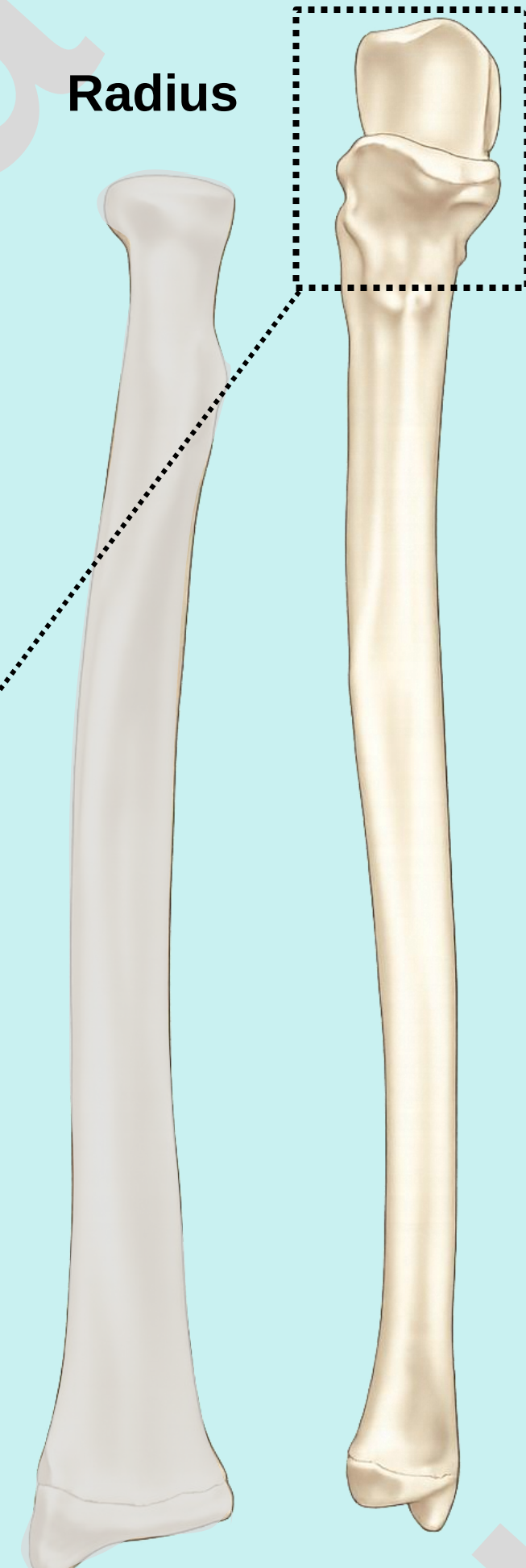
Olecranon Process ←

Coronoid Process ←



Radius

Ulna



Check List:

3. Ulna

✓ Outline the major parts of the ulna:

1. Proximal (Upper) End:

- Trochlear Notch:
 - A C-shaped (semilunar) notch.
 - Located between the olecranon and coronoid processes
 - Articulates with the trochlea of the humerus

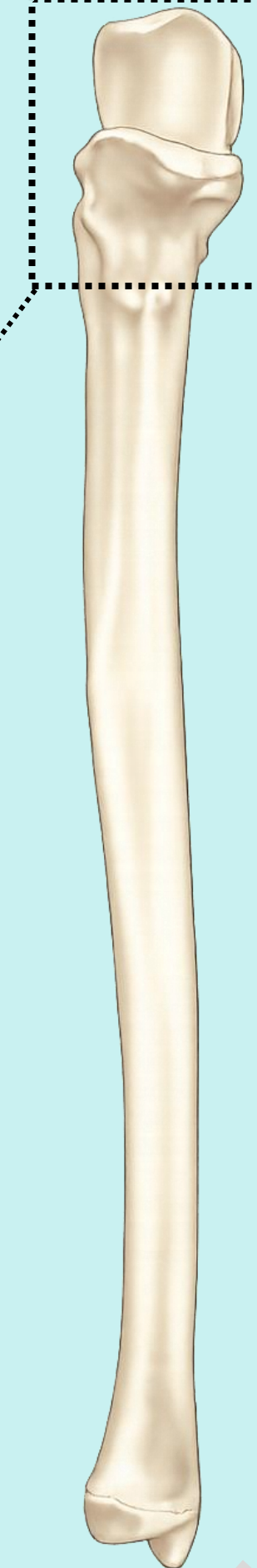
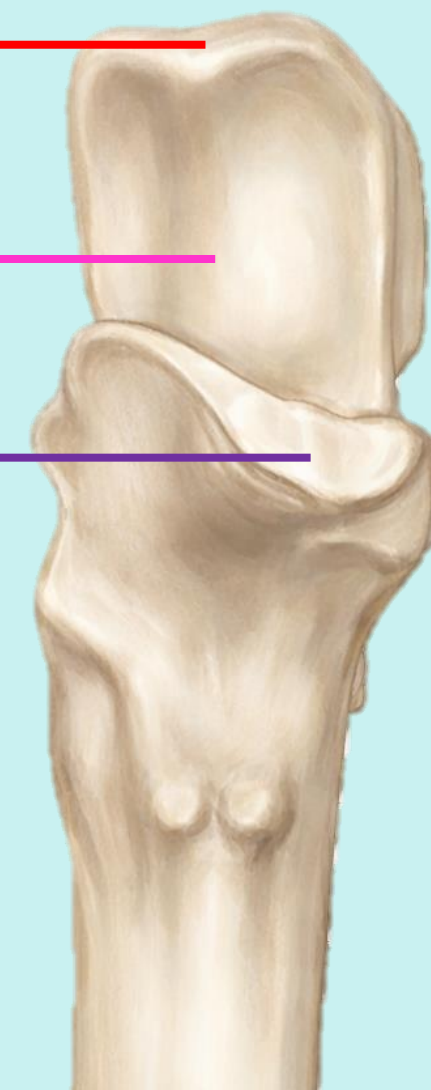Olecranon Process ←

Trochlear Notch ←

Coronoid Process ←

Radius

Ulna



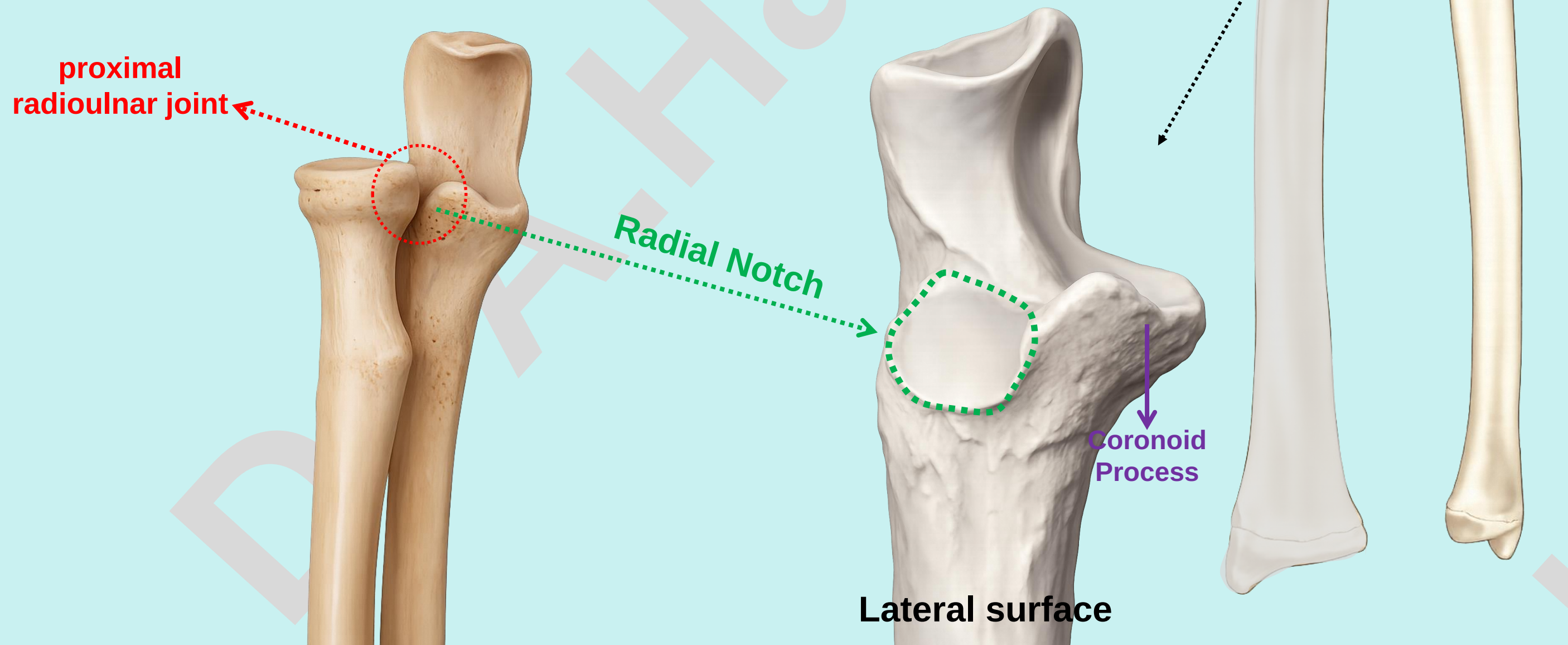
Check List:

3. Ulna

✓ Outline the major parts of the ulna:

1. Proximal (Upper) End:

- Radial Notch:
 - Located on the lateral surface of the coronoid process.
 - Articulates with the head of the radius to form the proximal radioulnar joint



Check List:

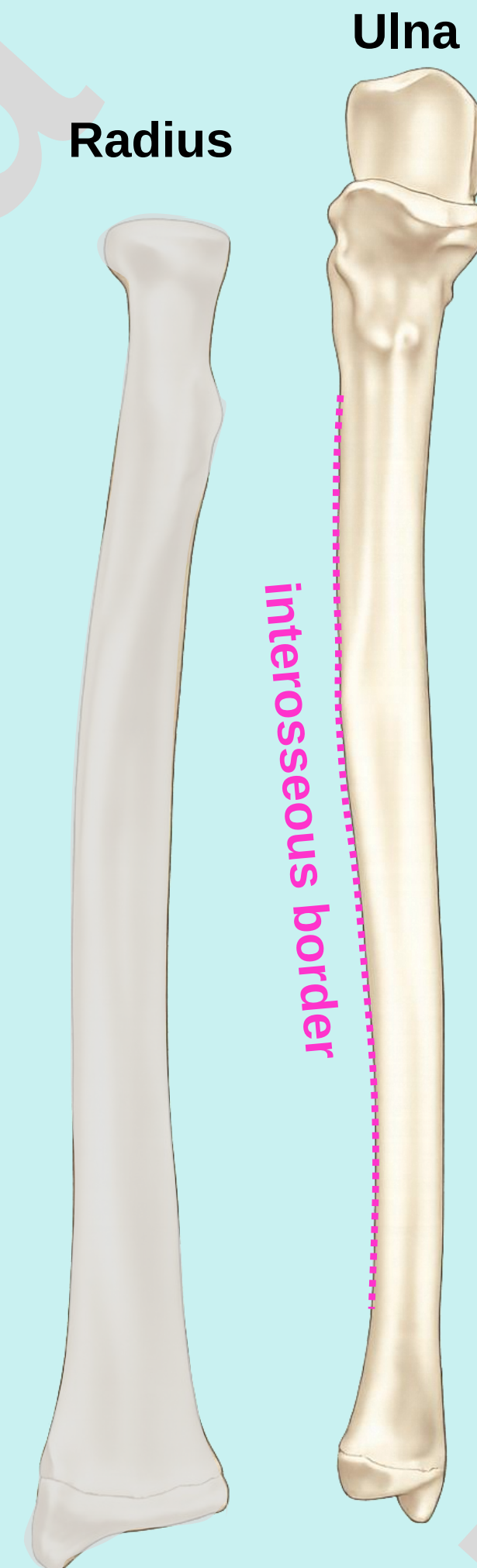
Practical Lab-4

3. Ulna

✓ Outline the major parts of the ulna:

2. Shaft:

- Extends between the proximal and distal ends
- Possesses a sharp lateral border called the interosseous border



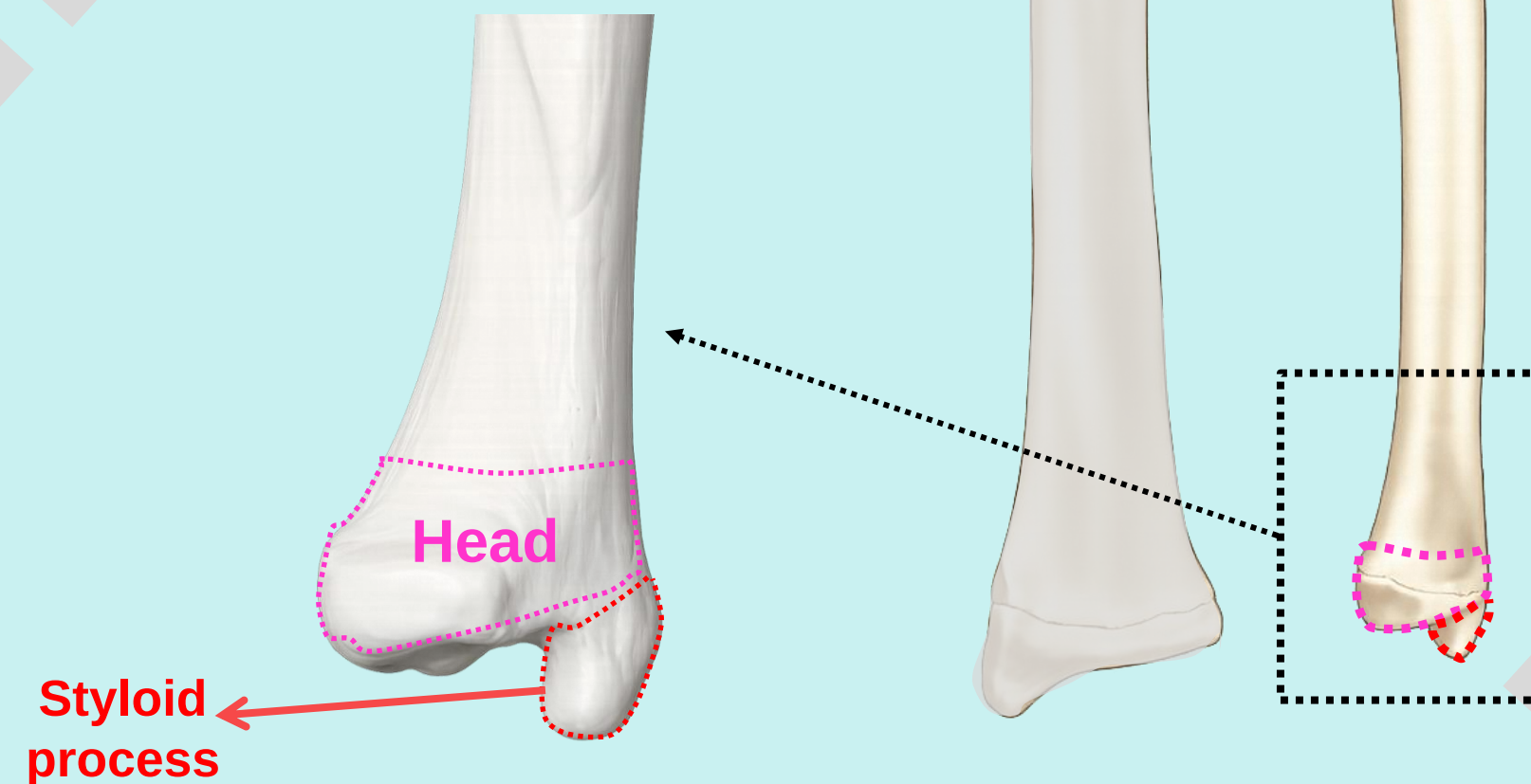
Check List:

3. Ulna

✓ Outline the major parts of the ulna:

3. **Distal (lower) end:** Identify the following features of the distal end:

- **Head of Ulna:**
 - Articulates laterally with the ulnar notch of the radius to form the distal radioulnar joint.
- **Styloid process:**
 - Projects downward from the posteromedial aspect of the head.



Check List:

Practical Lab-4

3. Ulna

- ✓ **Determine the side and anatomical position by holding it vertically in such a way that:**
 - 1. The hook-like proximal end faces upwards and anteriorly.**
 - 2. The interosseous border faces laterally.**

Check List:

Practical Lab-4

Radius and Ulna

✓ Outline the Joints between the Radius and Ulna:

1. Proximal radioulnar joint

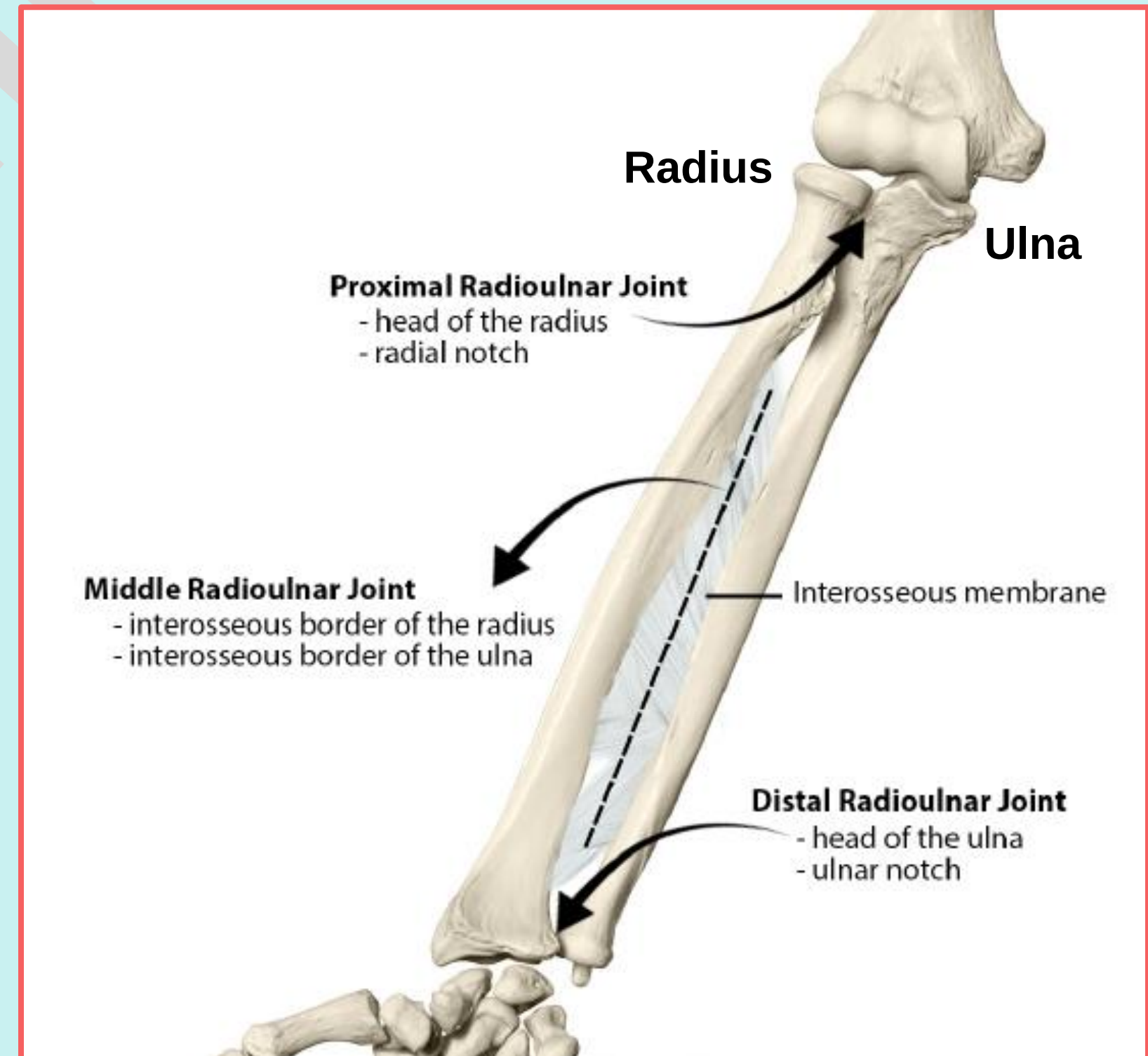
- Located between the head of the radius and the radial notch of the ulna at the proximal forearm.
- Type of joint: Synovial pivot joint; allows pronation and supination of the forearm.

2. Distal radioulnar joint

- Located between the head of the ulna and the ulnar notch of the radius at the distal forearm.
- Type of joint: Synovial pivot joint; allows pronation and supination of the forearm.

3. Middle radioulnar joint

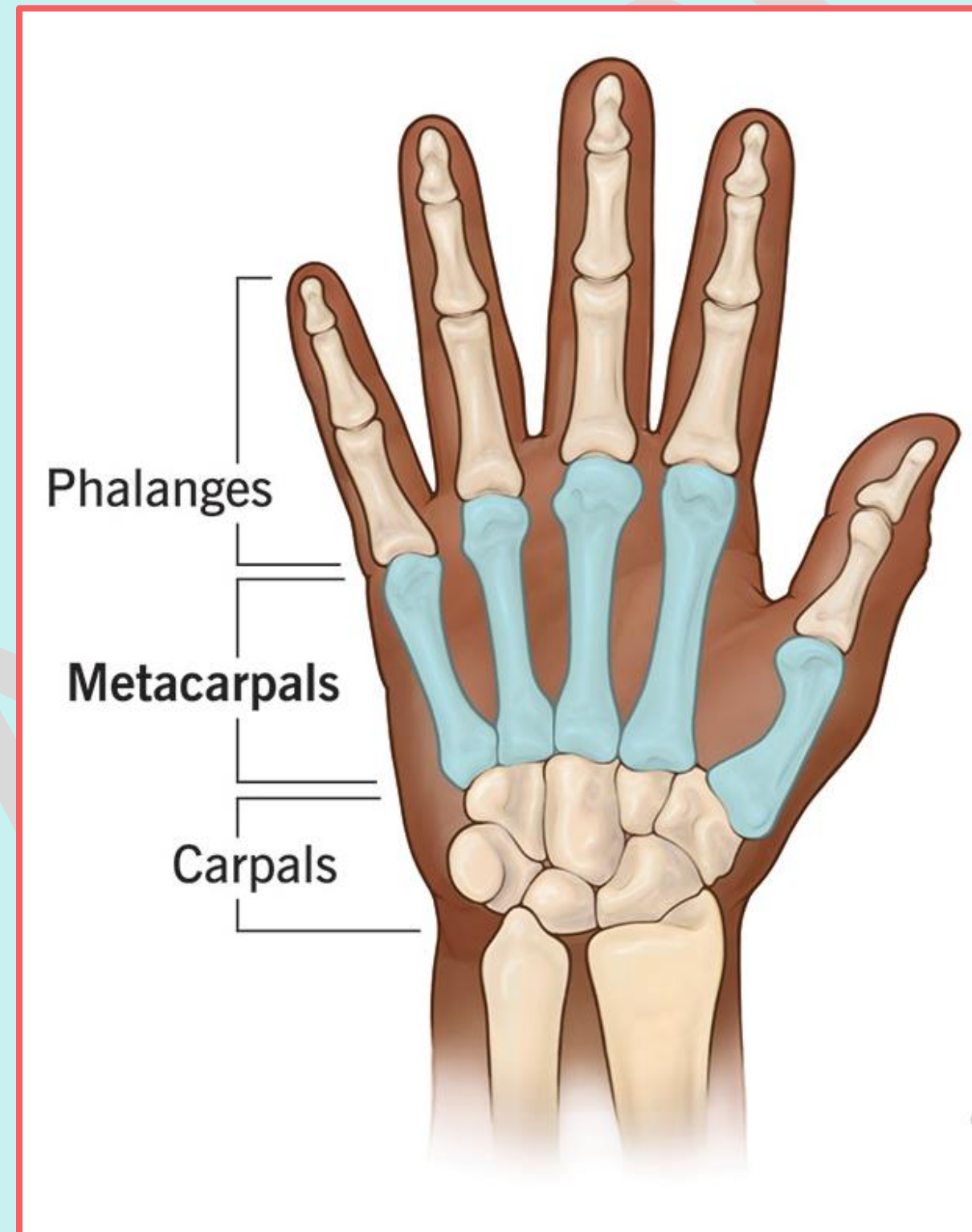
- Located between the interosseous borders of the shafts of the radius and ulna.
- Type of joint: Fibrous syndesmosis joint; helps stabilize the forearm and maintain the relationship between the two bones.



Check List:

4. Hand Bones

✓ Outline the major parts of the hand: wrist or carpus, hand proper (or metacarpus), and digits (thumb and fingers).



Check List:

4. Hand Bones

4.1 Carpal bones

- The carpus (wrist) is the proximal region of the hand and consists of eight small bones arranged in two rows: proximal and distal.

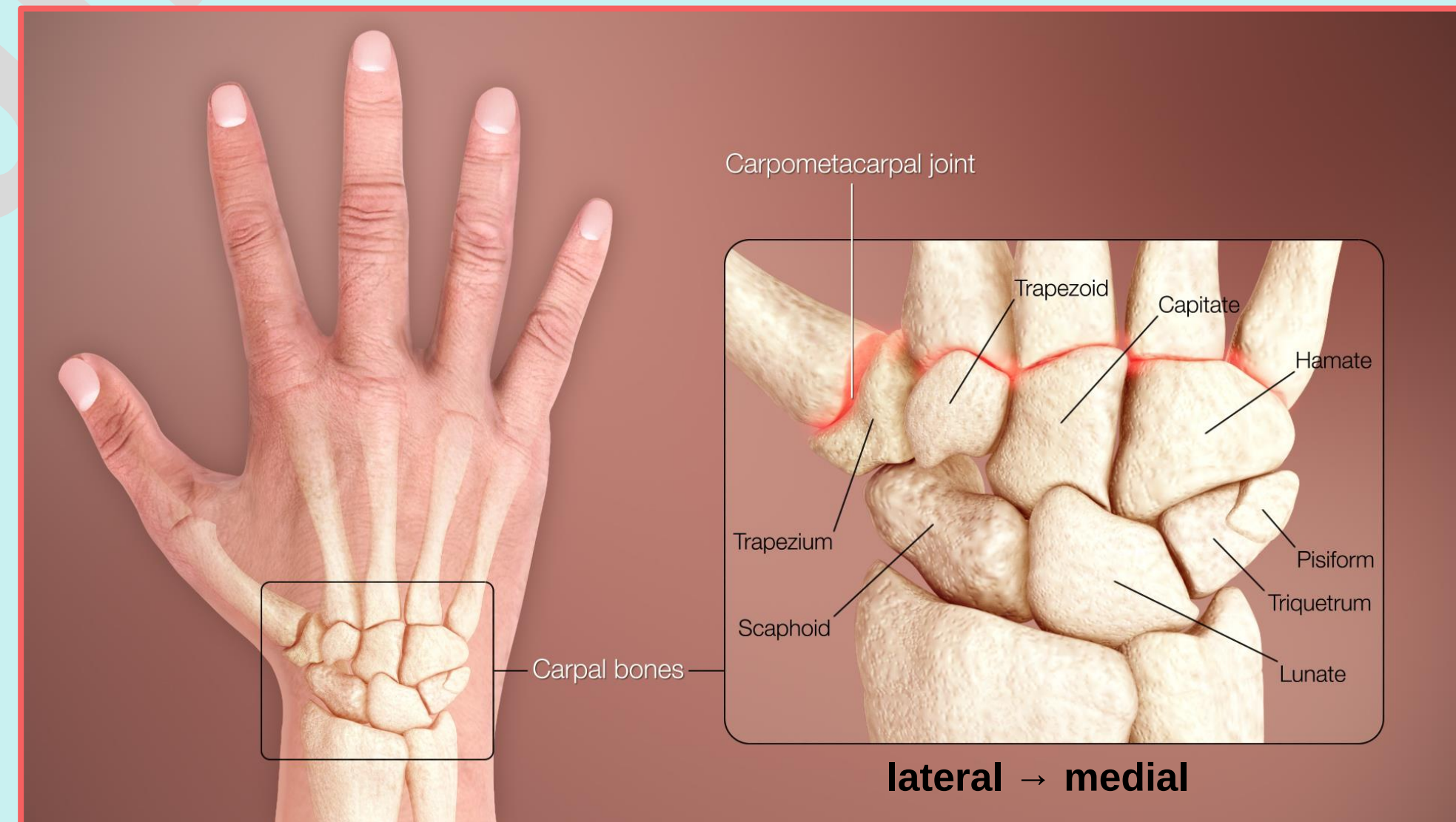
✓ Outline the names and type of the carpal bones.

- Proximal row (lateral → medial):

1. Scaphoid (boat-shaped)
2. Lunate (moon-shaped)
3. Triquetrum (triangular)
4. Pisiform (pea-shaped)

- Distal row (lateral → medial):

1. Trapezium (four-sided figure with no two sides parallel).
2. Trapezoid (four-sided figure with two sides parallel).
3. Capitate (head-shaped).
4. Hamate (hook-shaped)



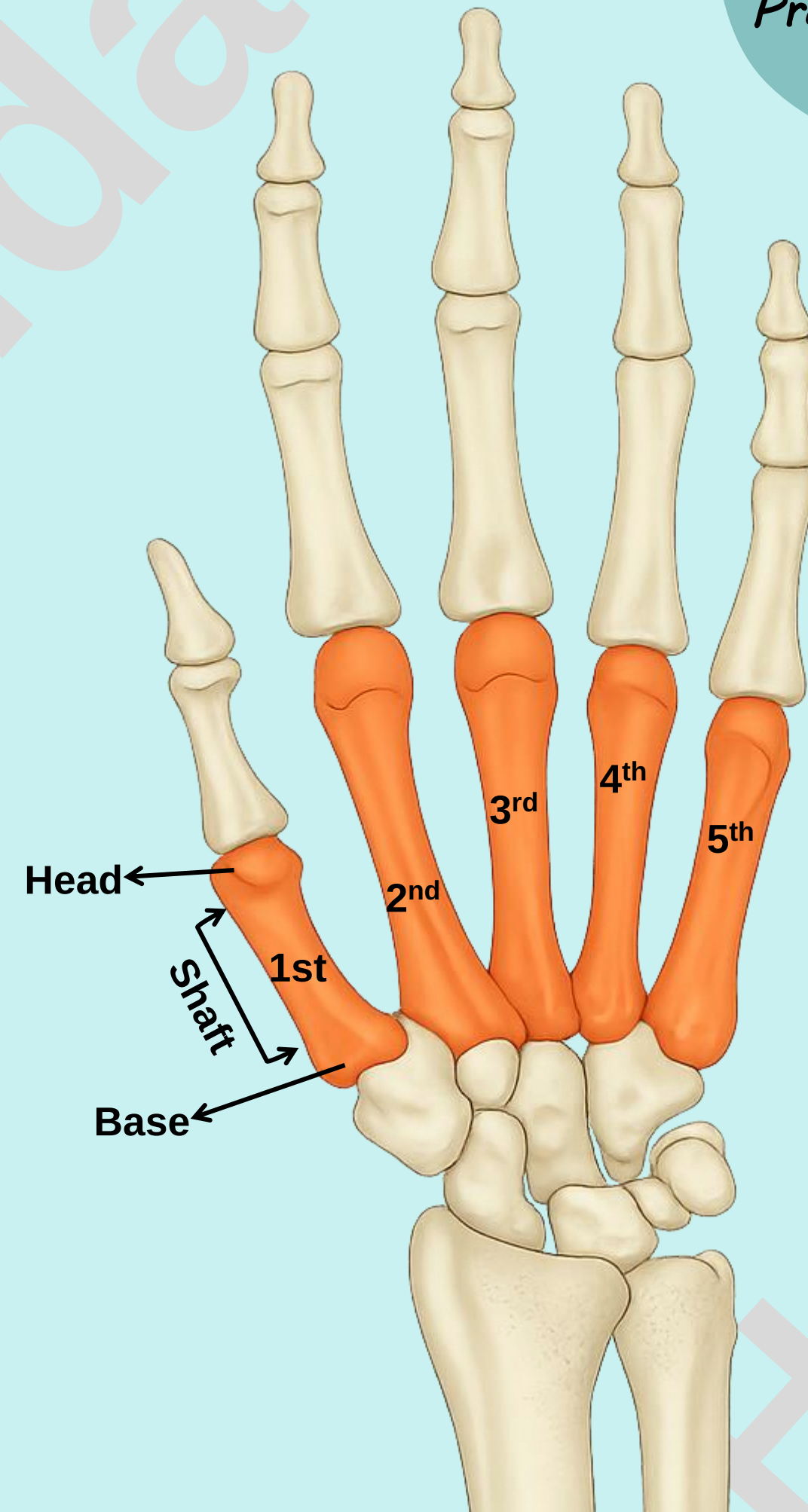
Check List:

Practical Lab-4

4. Hand Bones

4.2 Metacarpal bones

- The metacarpus (palm) consists of five metacarpal bones.
- Numbered I–V from lateral to medial, starting with the thumb.
- Each metacarpal is a short long bone consists of:
 - **Base** – proximal end
 - **Shaft** – body of the bone
 - **Head** – distal rounded end

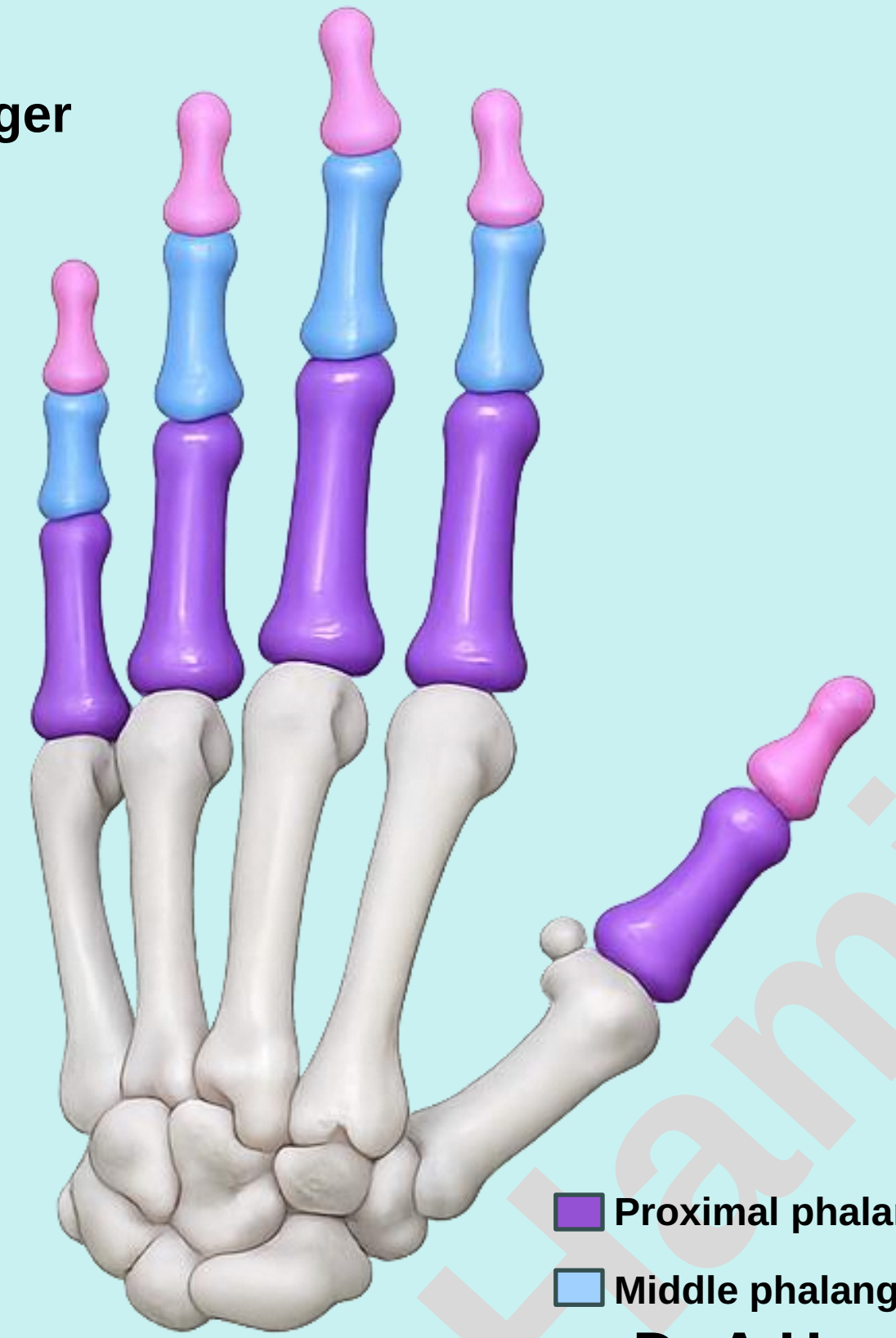
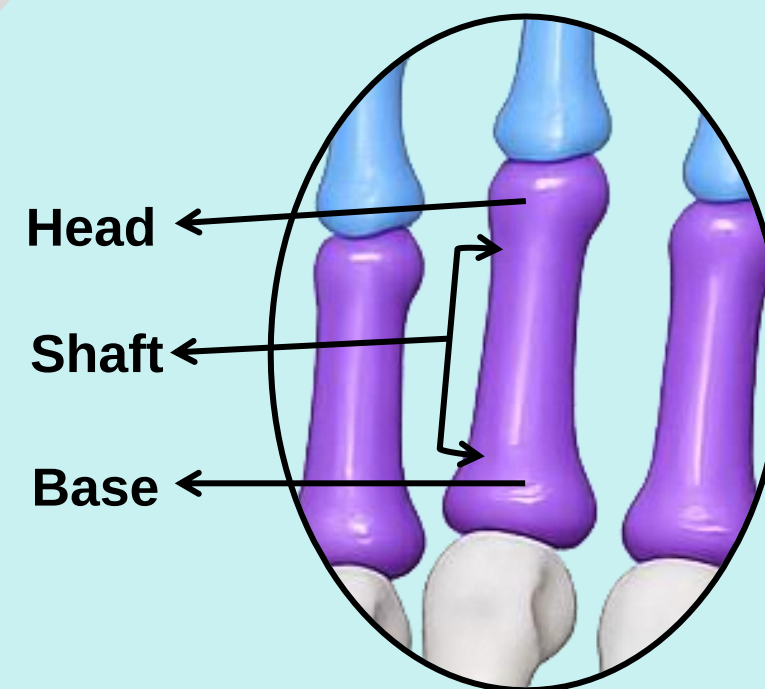


Check List:

4. Hand Bones

4.3 Digits bones

- The digits are Thumb, Index finger, Middle finger, Ring finger, and Little finger
- Each digit consist of phalanges:
 - The thumb has two phalanges called proximal and distal phalanges.
 - The other four digits have three phalanges called proximal, middle, and distal phalanges
- Each phalanx is a short, long bone consists of:
 - **Base – proximal end**
 - **Shaft – body**
 - **Head – distal end**



- Proximal phalanges
- Middle phalanges
- Distal phalanges