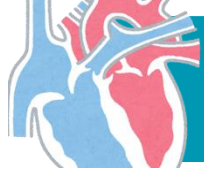


بِسْمِ اللَّهِ الرَّحْمَنِ الرَّحِيمِ



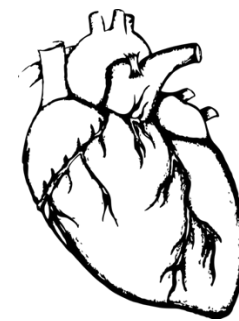
ANATOMY

MID | Lecture 5

# Skeletal System 4 - Joints

وَلَقَدْ خَلَقْنَا الْإِنْسَانَ وَنَعَلَهُمَّا تَوْسُوسًا بِهِ نَفْسُهُ وَنَحْنُ أَقْرَبُ إِلَيْهِ مِنْ حَبْلِ الْوَرِيدِ

**Written by :** Darren Alhababseh  
Joud Alsafadi  
Khaled Abdalla



**Reviewed by :** Ahmad Mohy  
Abdullah Saffarini

# Introduction to Anatomy

1<sup>st</sup> Year Medical Students

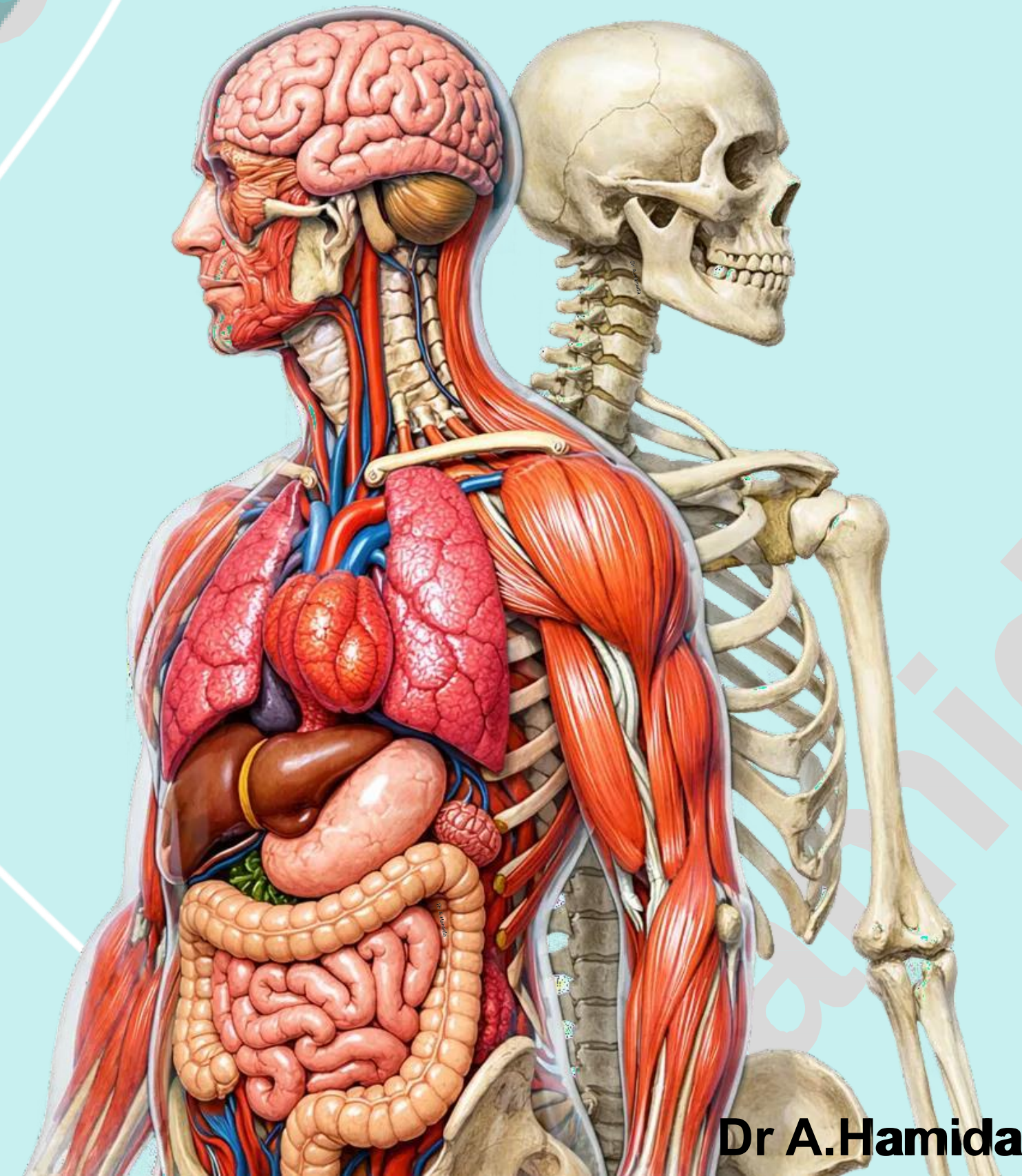
2025-2026  
Second Semester

Dr. Abedallah Hamida, MBBS, PhD

Department of Anatomy and Histology

School of Medicine-The University of Jordan

[a\\_hamida@ju.edu.jo](mailto:a_hamida@ju.edu.jo)



Dr A.Hamida

# Course Outline:

1 Introduction and Terminology

2 Skeletal System

3 Cardiovascular System

4 Lymphatic System

5 Nervous System

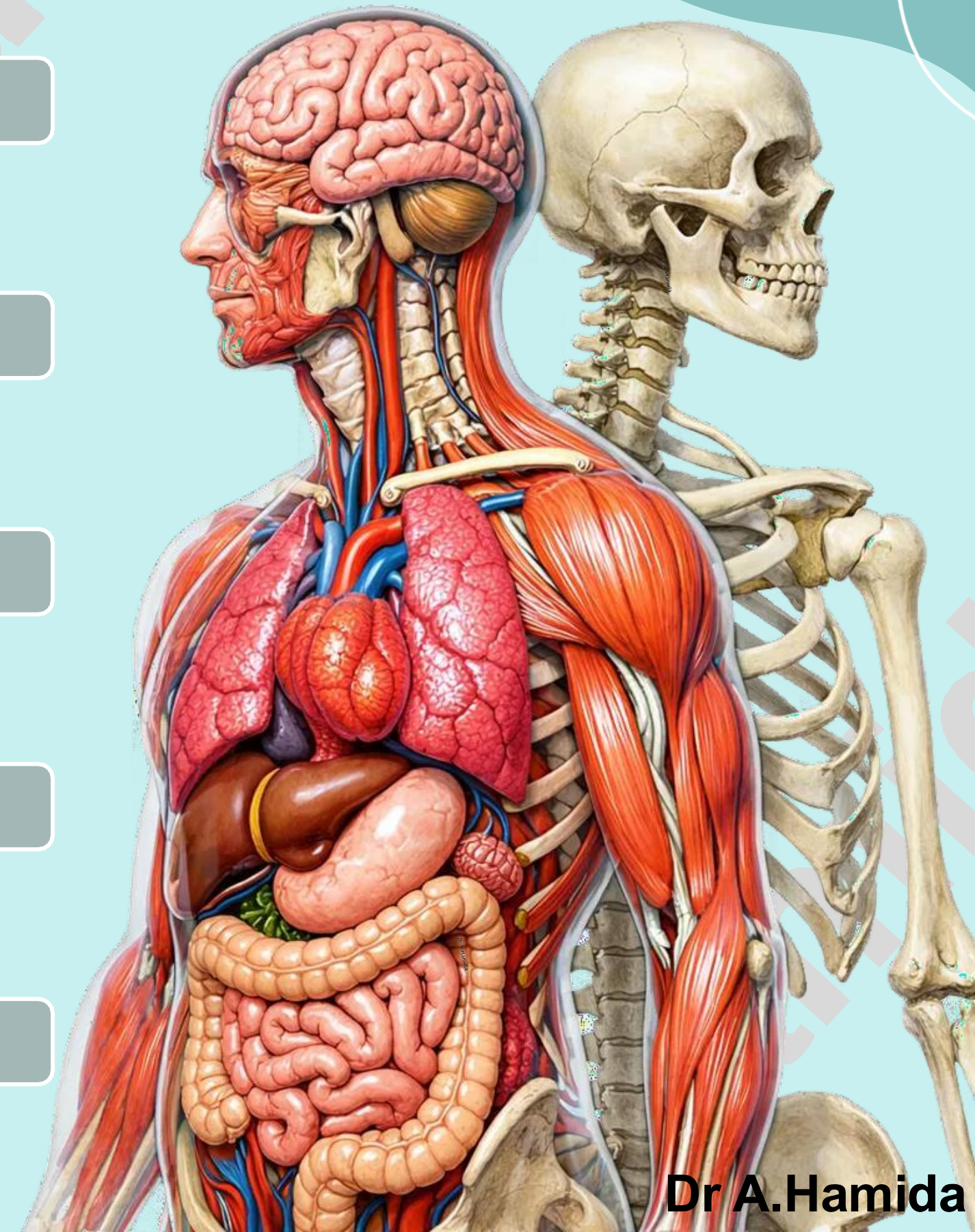
6 Muscular System

7 Respiratory System

8 Digestive System

9 Urinary System

10 Endocrine System



# 2

## Skeletal System

### System Outline:

2.1

Axial Skeleton

2.2

Appendicular Skeleton

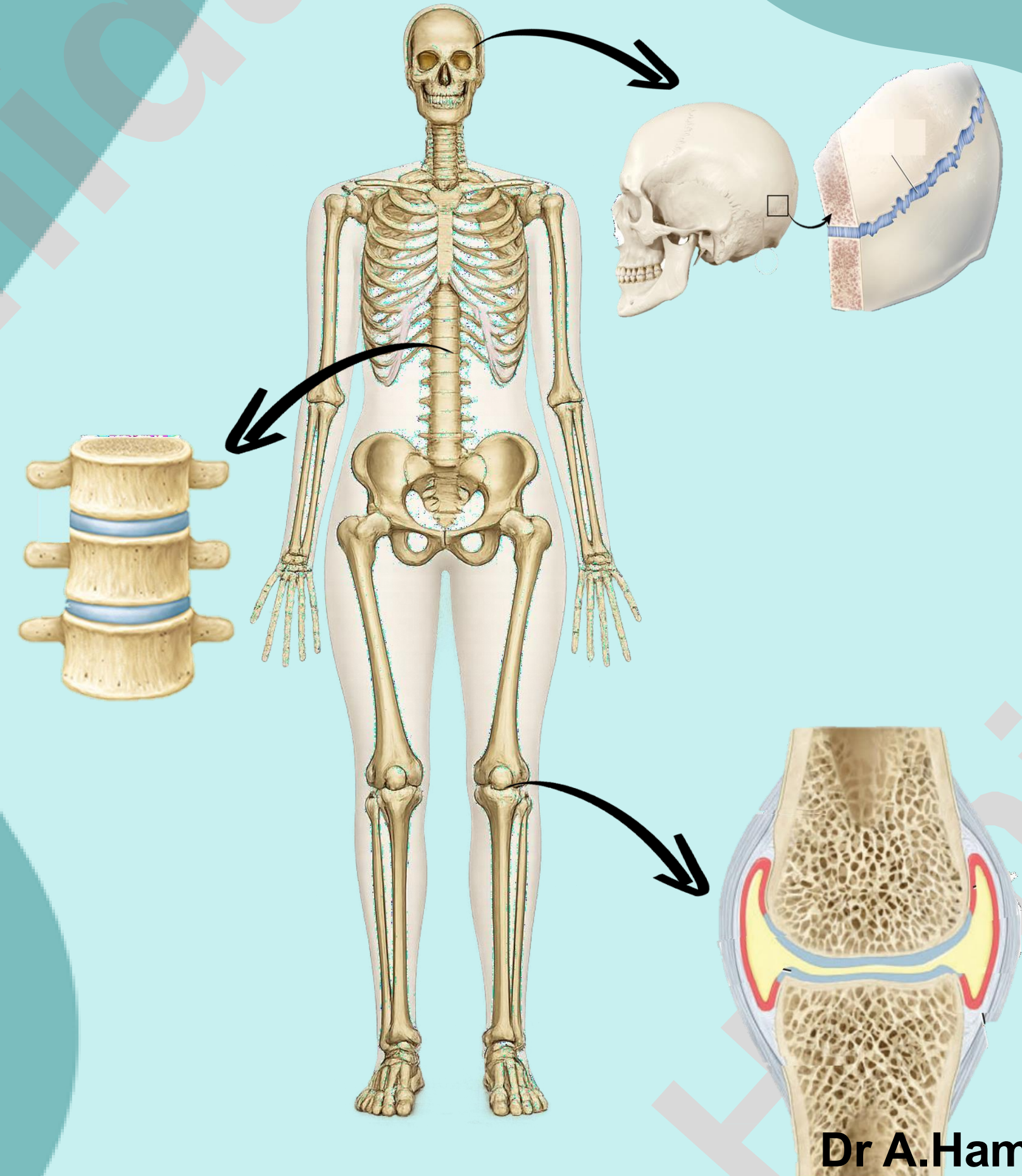
2.3

Joints

2

# Skeletal system

## 3. Joints



# 2.3 Skeletal System—Joints

## ➤ Joints

- It is a junction between two or more bones that allow movement between them.
- Joints is classified structurally based upon the type of connecting tissue and the presence or absence of a joint cavity, into three types:

1. **Fibrous Joint.**

2. **Cartilaginous Joint.**

3. **Synovial Joint.** The only joint that has a cavity

The synovial joint is the only joint that is diarthrosis because it has a cavity, and this cavity gives a space that allows wide movement.

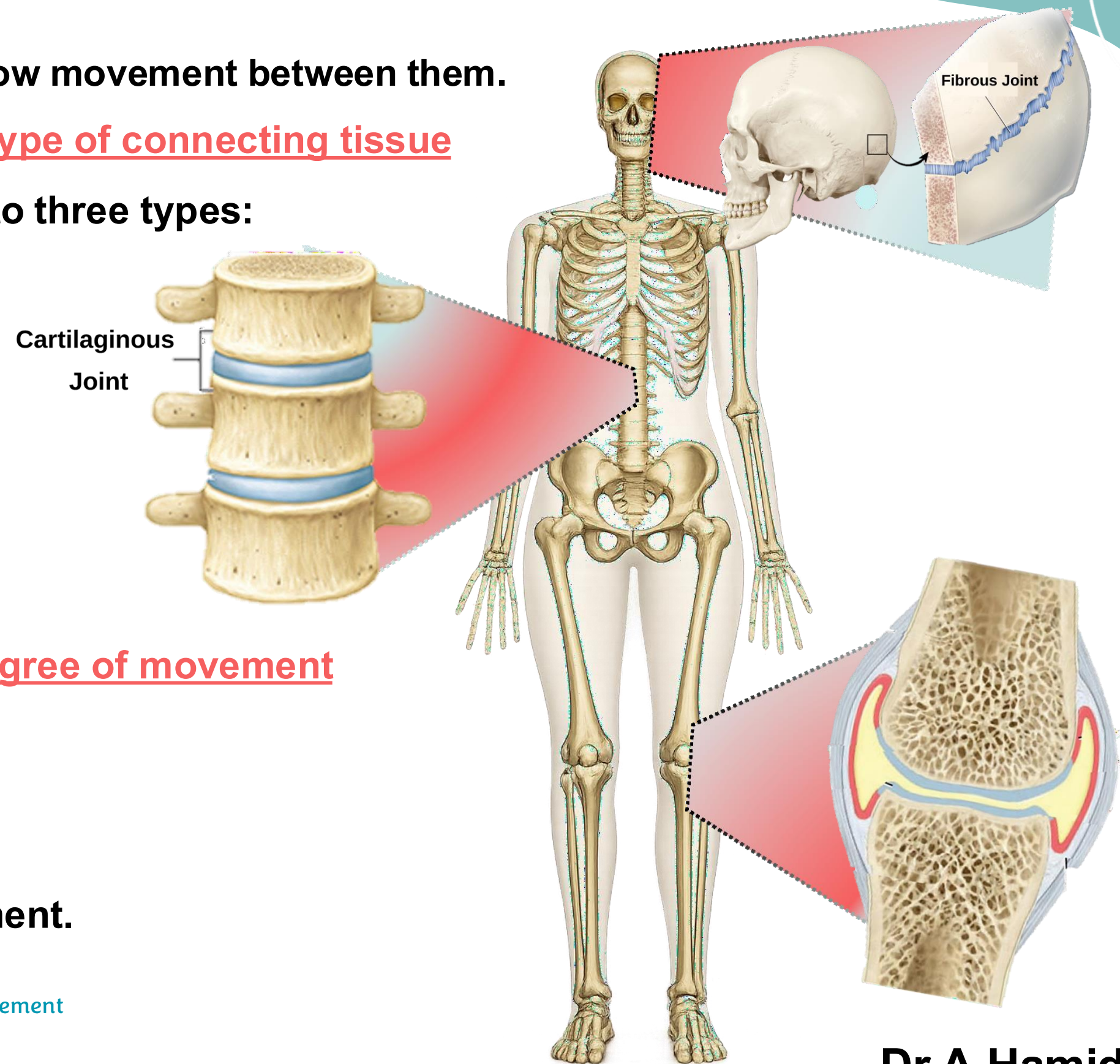
} These may have slight movement or be immovable.

- Joints can also be classified according to the degree of movement they provide, into:

1. **Synarthrosis:** immovable joints.

2. **Amphiarthrosis:** joints allowing slight movement.

3. **Diarthrosis:** freely movable joints. Wide range of movement



## 2.3 Skeletal System–Joints

### Lecture Outline:

2.3.1 Fibrous Joints

2.3.2 Cartilaginous Joints

2.3.3 Synovial Joints

<b>Description</b>	<b>Tissue between bones</b>	The two bones are connected by <u>dense fibrous connective tissue</u> .
	<b>Cavity</b>	No cavity
	<b>Movement</b>	Can be either synarthrotic ( <b>immovable</b> ) or amphiarthrotic ( <b>slightly movable</b> ).
<b>Types</b>	<ol style="list-style-type: none"><li>1. Suture</li><li>2. Gomphosis</li><li>3. Syndesmosis</li></ol>	

# Fibrous Joints

## ➤ Types of Fibrous Joint:

### 1. Suture

#### Description

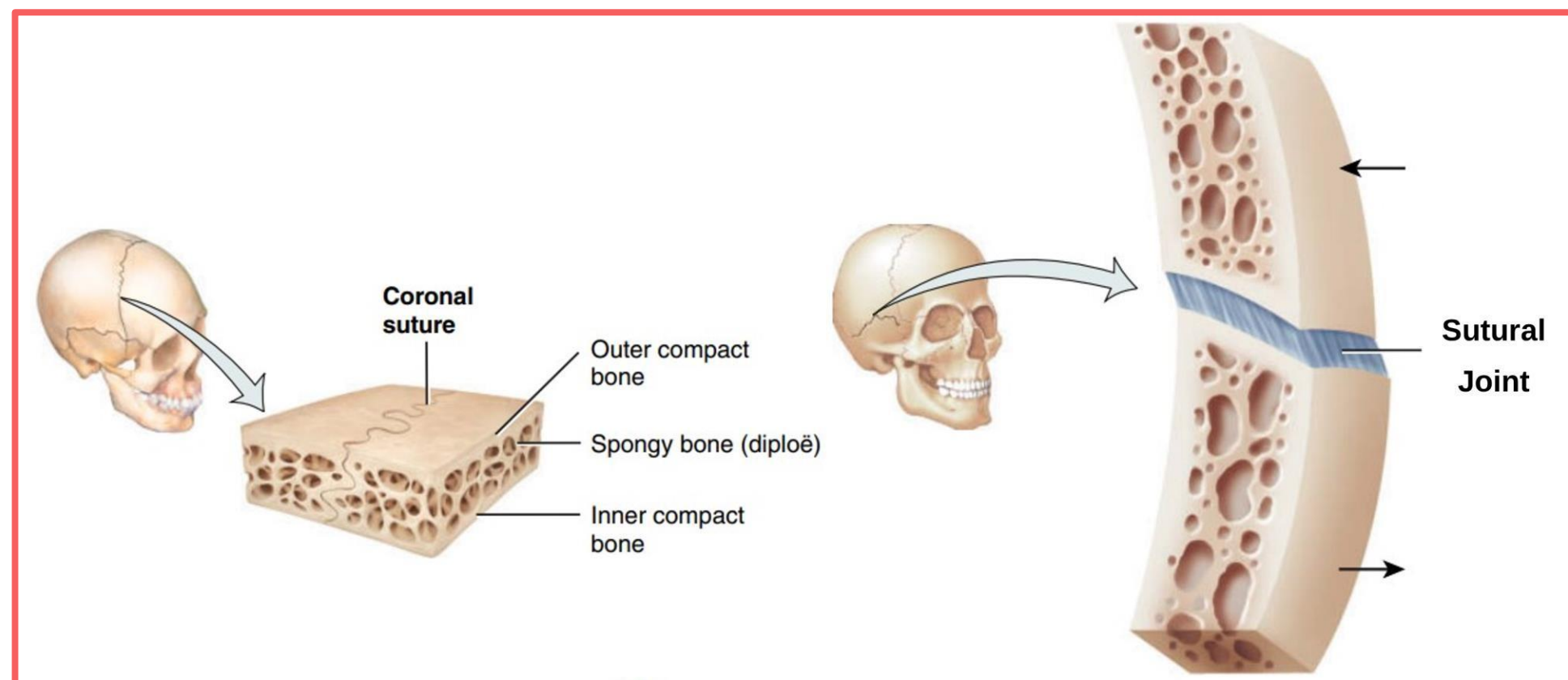
- A fibrous joint composed of a thin layer of dense irregular connective tissue that unites the bones.

#### Movement

- Immovable (synarthrosis) in adults, but slightly movable (amphiarthrosis) in infants and children. *To allow the brain to grow in childhood , and crucial in baby delivery (letting the head pass through the birth canal )*

#### Example

- Found only between the bones of the skull, e.g., **coronal suture between the parietal and frontal bones.** , **the sagittal suture** between the two parietal bones , **the lambdoid suture** between the parietal bones and the occipital bone at the back of the skull.



# Fibrous Joints

## ➤ Types of Fibrous Joint:

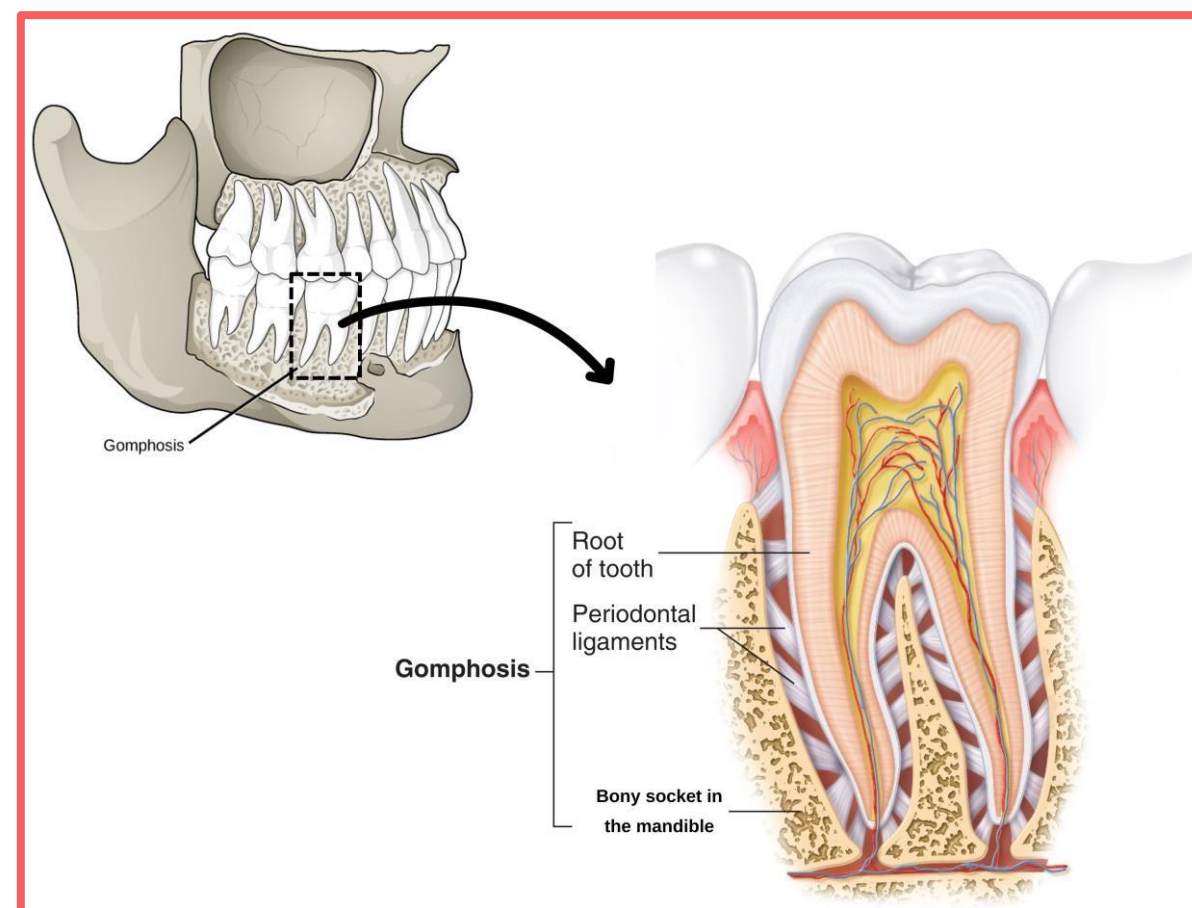
### 2. Gomphosis

<b>Description</b>	<ul style="list-style-type: none"> <li>A fibrous joint that anchors a tooth root into its bony socket in the maxilla or mandible via the <u>periodontal ligament</u>.</li> </ul>
<b>Movement</b>	<ul style="list-style-type: none"> <li>Immovable (synarthrosis).</li> </ul>
<b>Example</b>	<ul style="list-style-type: none"> <li>Between the teeth and their sockets in the maxilla and mandible.</li> </ul>

Gomphosis is the joint between a tooth and the bony socket in which it sits.

\*In the mandible and maxilla, there is a bony socket (اللي هو عبارة عن تجويف عظمي) بييجي داخل فيها السن

The articulation between a tooth and its bony socket (bone with bone) forms a joint. Between the tooth and the bony socket, there are a ligaments, which is a fibrous ligaments called the periodontal ligaments. Together, the tooth, the bony socket, and this ligaments form a gomphosis, which is a type of fibrous joint.



# Fibrous Joints

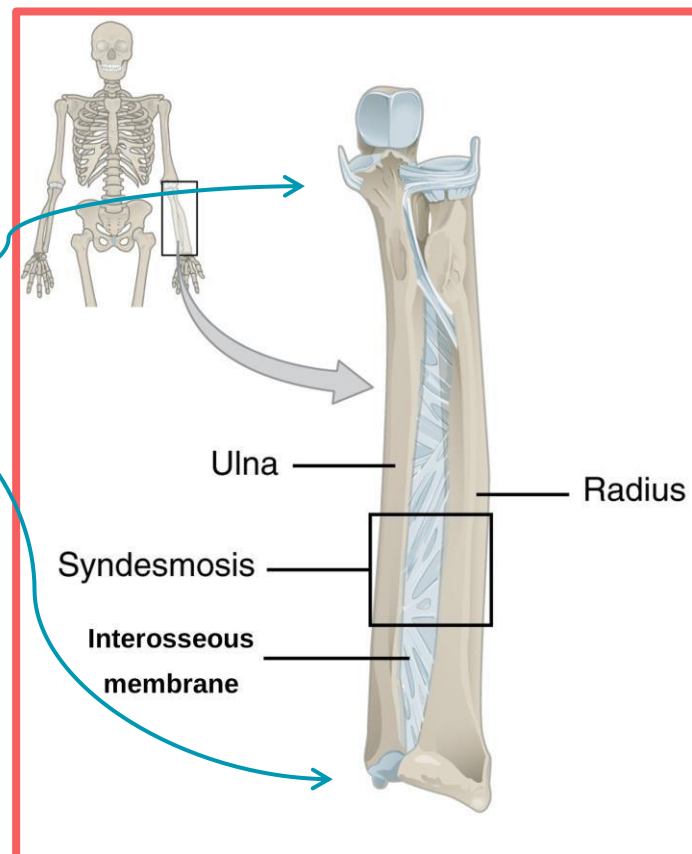
Syndesmosis is the joint between two long bones, specifically between their shafts. When there is a relatively large distance between the two shafts, a membrane can connect them. This membrane, together with the two shafts, forms a joint called a syndesmosis.

## ➤ Types of Fibrous Joint:

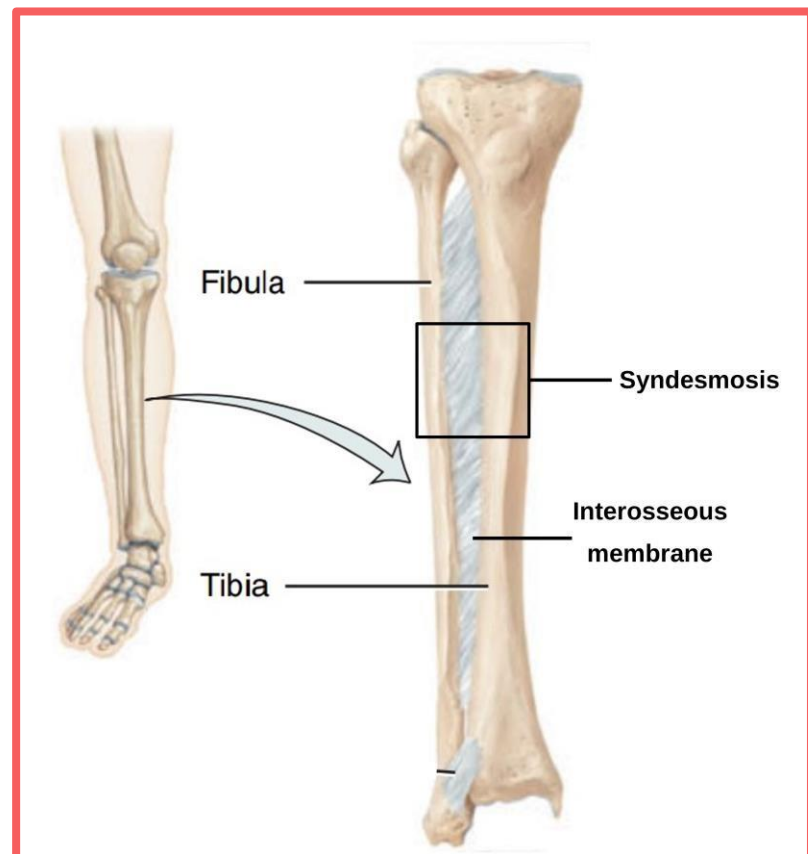
### 3. Syndesmosis

<b>Description</b>	<ul style="list-style-type: none"> <li>A fibrous joint where there is a greater distance between two adjacent bones, connected by dense irregular connective tissue arranged as a membrane known as <u>interosseous membrane</u>. Is found only between the fibula and tibia, and between the ulna and radius.</li> </ul>
<b>Movement</b>	<ul style="list-style-type: none"> <li>Slightly movable (amphiarthrosis).</li> </ul>
<b>Example</b>	<ul style="list-style-type: none"> <li>Interosseous membrane between the radius and ulna.</li> <li>Interosseous membrane between the tibia and fibula</li> </ul>

Here in the ulna and radius, the two proximal ends articulate with each other, and the two distal ends also articulate with each other. However, along the shafts, there is a membrane between them, called the interosseous membrane.



And the same thing here between the fibula and tibia



<b>Description</b>	<b>Tissue between bones</b>	The two bones are connected by cartilage ( <u>hyaline cartilage</u> or <u>fibrocartilage</u> ).
	<b>Cavity</b>	No cavity we just have a connective tissue
	<b>Movement</b>	Can be either synarthrotic ( <b>immovable</b> ) or amphiarthrotic ( <b>slightly movable</b> ).
<b>Types</b>	<ol style="list-style-type: none"> <li>1. Primary cartilaginous joints (synchondroses)</li> <li>2. Secondary cartilaginous joints (symphyses)</li> </ol>	

# Cartilaginous Joints

## ➤ Types of Cartilaginous Joint:

### 1. Primary cartilaginous joints (synchondroses)

#### Description

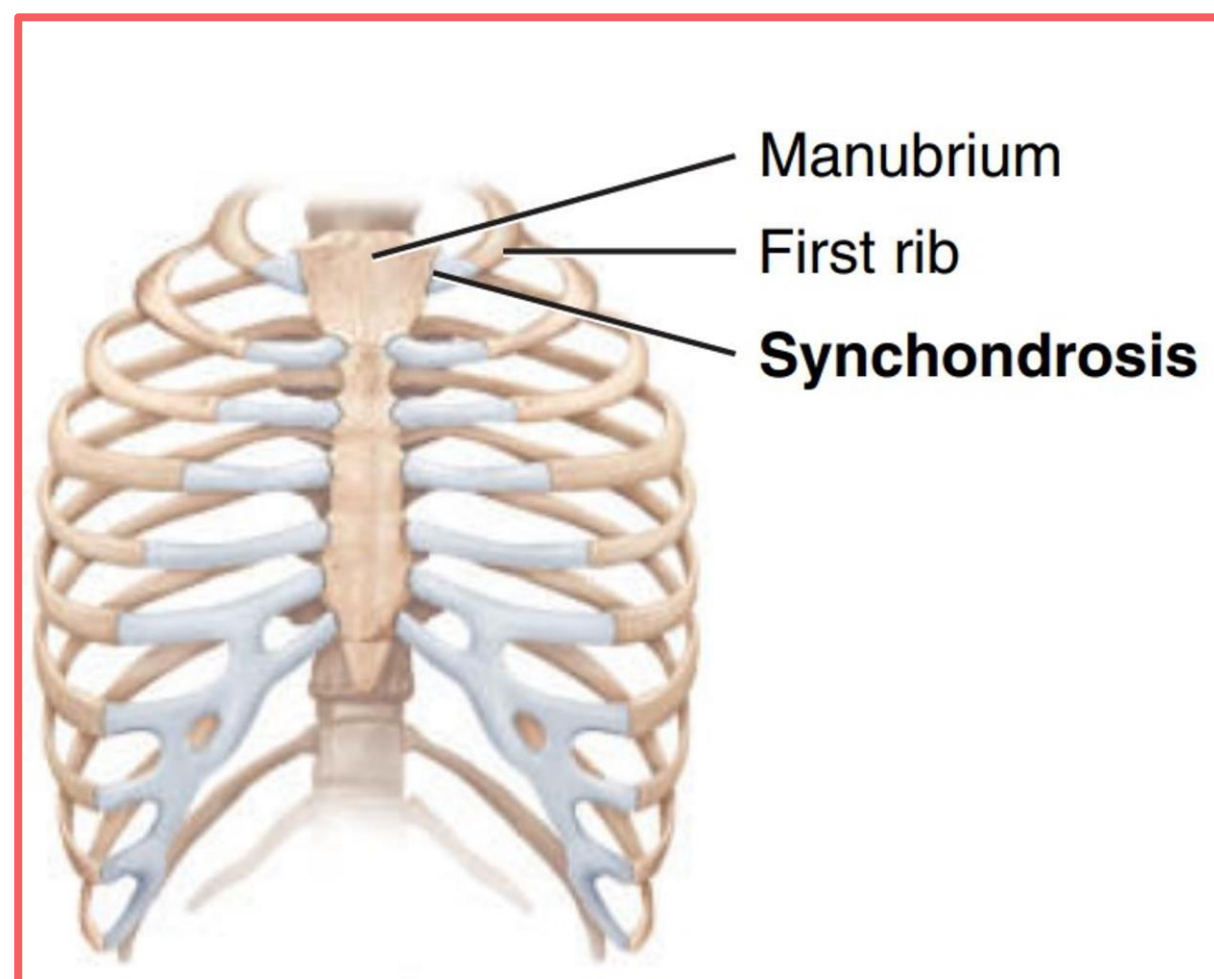
- Bones are joined by a plate of hyaline cartilage.

#### Movement

- Immovable (synarthrosis)

#### Example

- The first costosternal joint (**between the first rib and the manubrium of the sternum**).

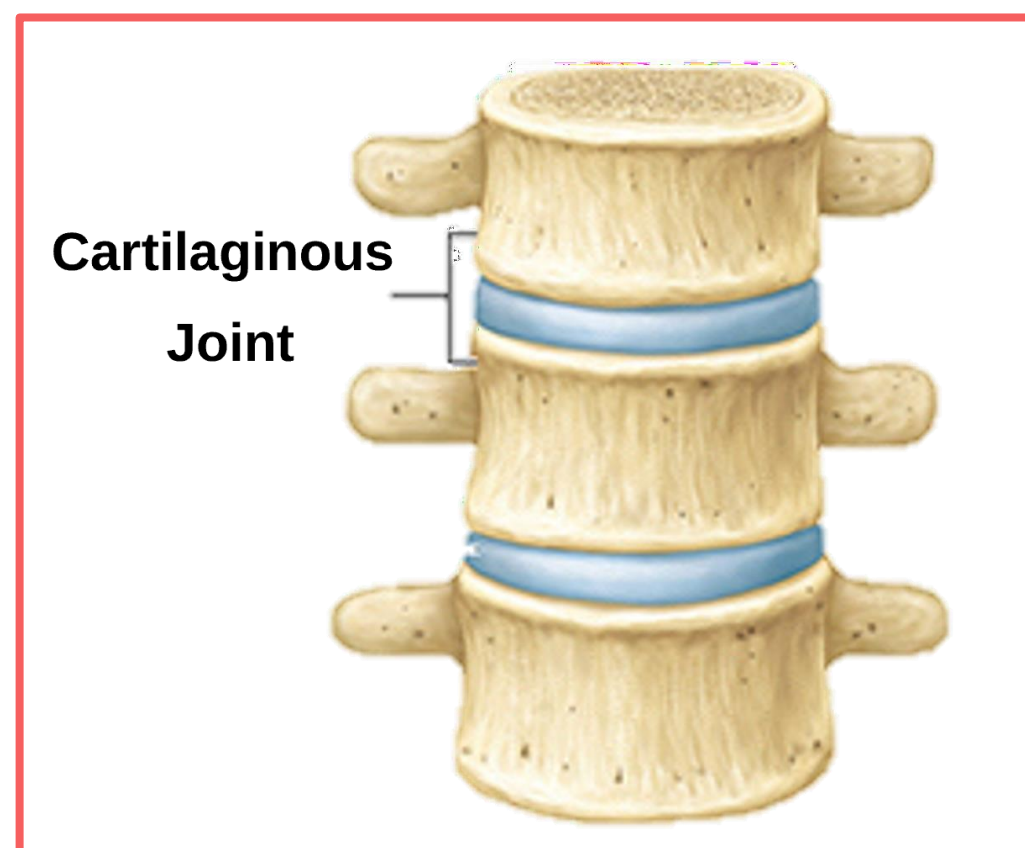
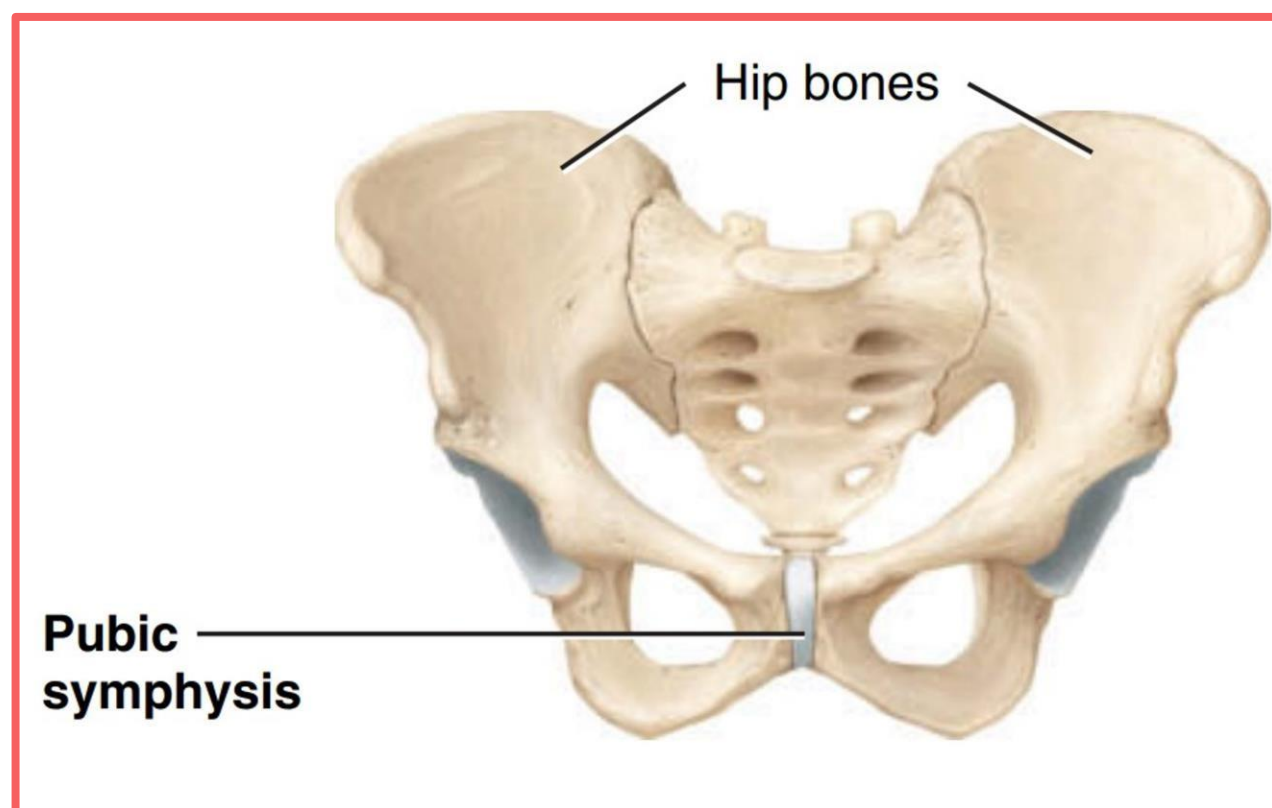


# Cartilaginous Joints

## ➤ Types of Cartilaginous Joint:

### 2. Secondary cartilaginous joints (symphyses)

<b>Description</b>	<ul style="list-style-type: none"> <li>Bones are joined by fibrocartilage</li> </ul>
<b>Movement</b>	<ul style="list-style-type: none"> <li>Slightly movable (amphiarthrosis). <i>Their movement is not like that of a diarthrosis, yet at the same time, they are not completely immovable.</i></li> </ul>
<b>Example</b>	<ul style="list-style-type: none"> <li>Pubic symphysis (<b>between the two pubic bones</b>).</li> <li>Intervertebral discs (<b>between the bodies of adjacent vertebrae</b>). <i>(The fibrocartilaginous discs between two vertebrae.)</i></li> </ul>

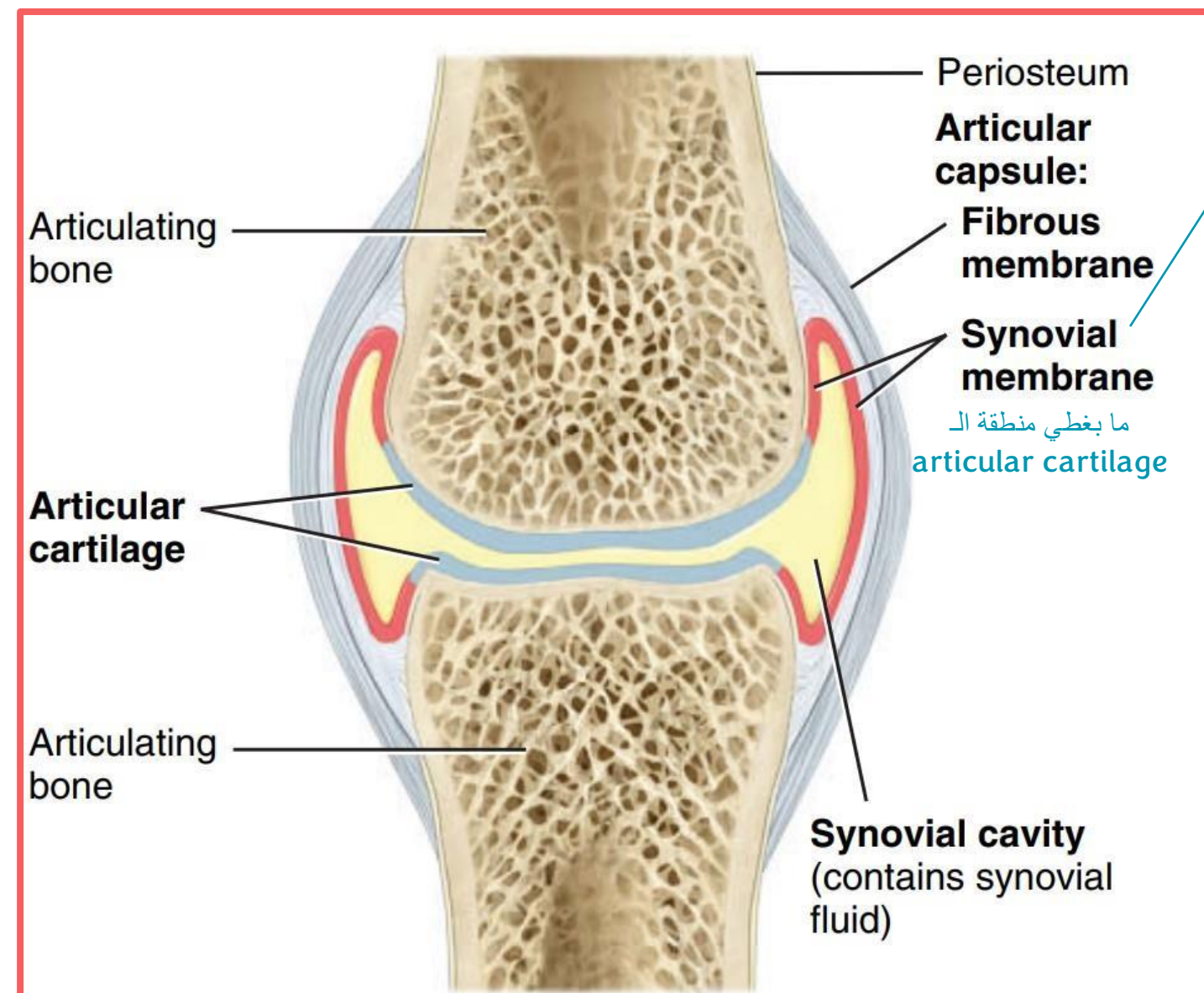


# Synovial Joints

A joint between two bones in which there is a cavity filled with synovial fluid.

**\*\*The most important**

<b>Description</b>	<b>Tissue between bones</b>	<ul style="list-style-type: none"> <li>• There is a space between the articulating bones.</li> <li>• The articulating surfaces are covered with <b>hyaline cartilage</b>.</li> </ul>
	<b>Cavity</b>	<ul style="list-style-type: none"> <li>• The bones forming the joint have a <b>synovial cavity</b>, filled with a fluid called <b>synovial fluid</b>.</li> </ul>
	<b>Movement</b>	<ul style="list-style-type: none"> <li>• These joints are diarthrotic, allowing a wide range of movements.</li> </ul>



Secretes synovial fluid and lines the synovial cavity, except the region of the articulated surfaces of the bones.

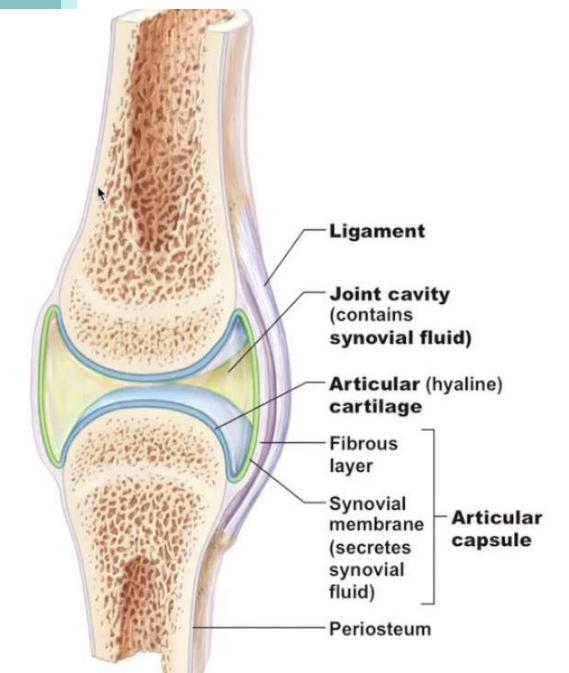
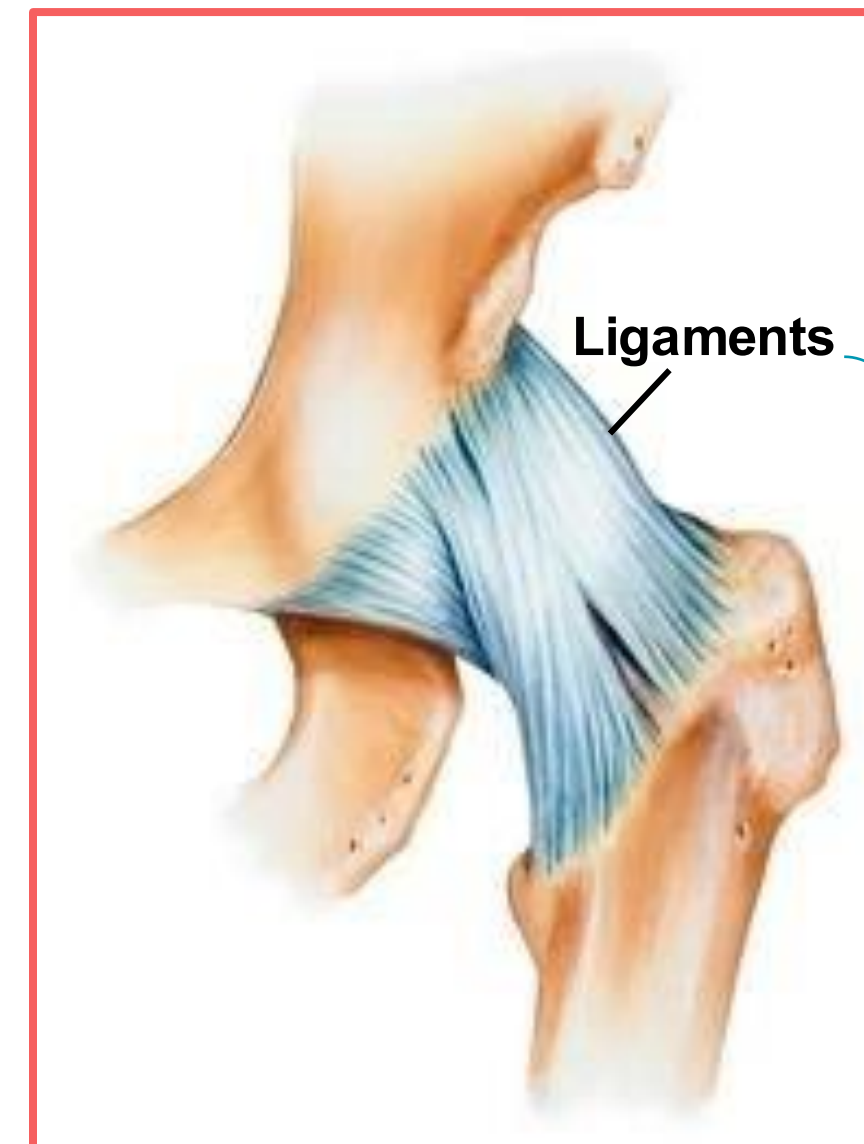
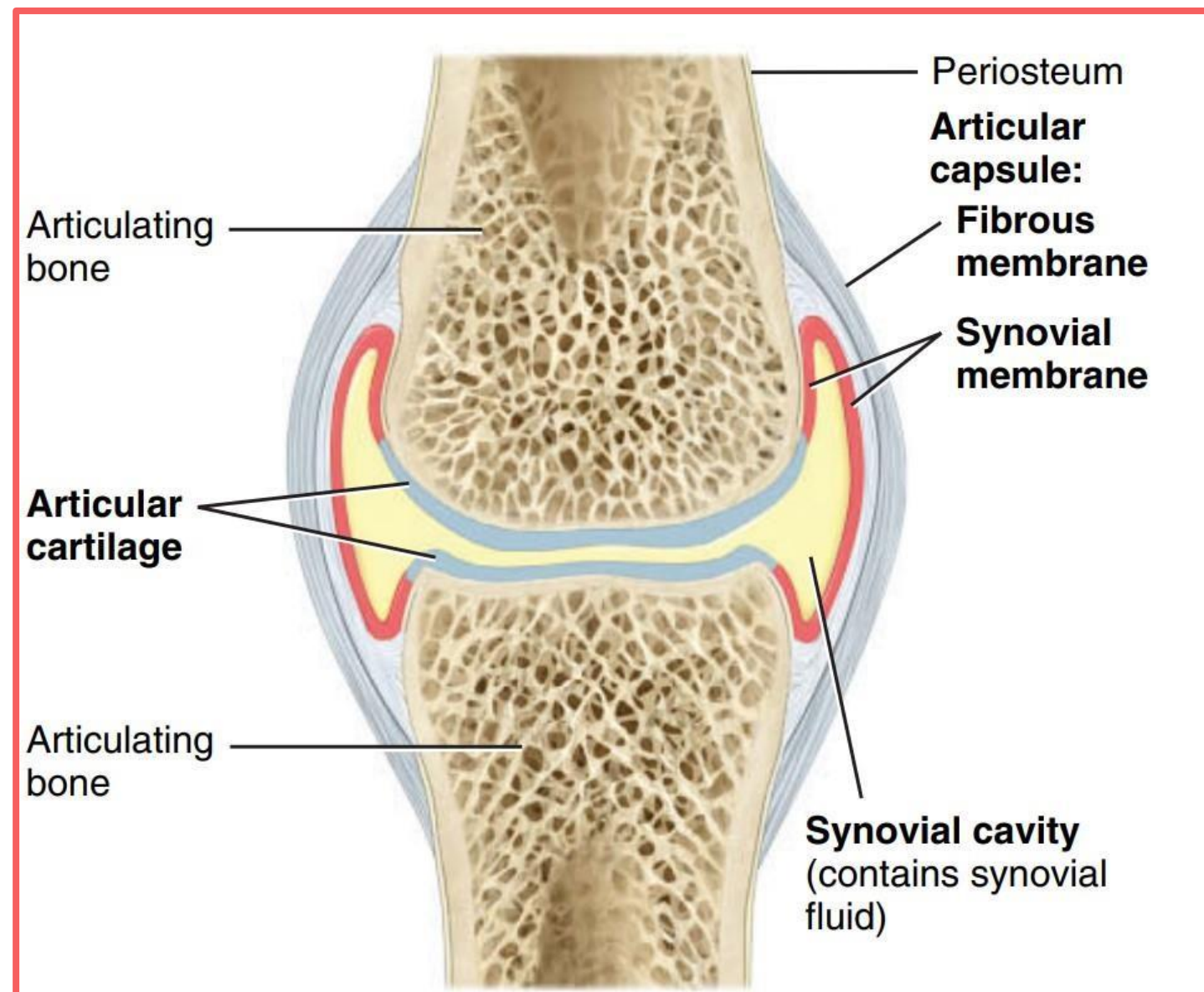
The articulated surfaces of the two bones are not supposed to touch each other, but during movement, the bones may come into contact. To prevent friction between them, these surfaces are covered with cartilage, which protects the articulated bones.

The synovial membrane lines the bones and the inner surface of the joint except the articulation area, and the fibrous capsule covering the joint from the outside, encloses all the joints. This closure maintains joint stability, because the joints move frequently and need to be stabilized.

## Special Features

1. **Joint capsule:** an external fibrous capsule enclosing the joint cavity.
2. **Synovial membrane:** lines the inner surface of the joint capsule and secretes **synovial fluid** for lubrication.
3. **Articular cartilage:** the articulating surfaces of the bones are covered with hyaline cartilage.
4. **Ligaments:** strengthen and support the joint; may be extracapsular or intracapsular.

Additional picture for more understanding

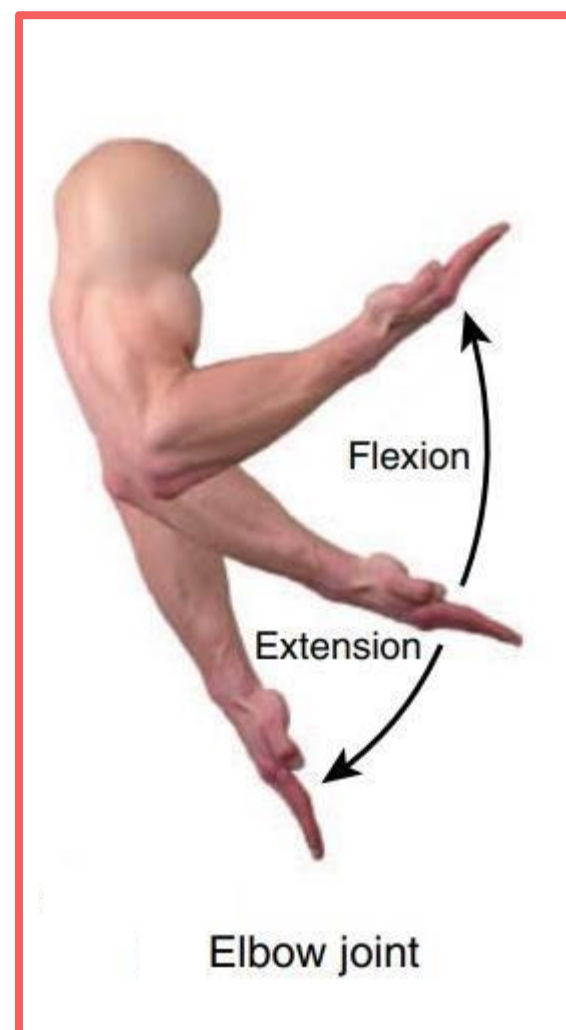


Covers the fibrous capsule from the outside to increase the stabilisation of the synovial joint

## Types of Movements at Synovial Joints:

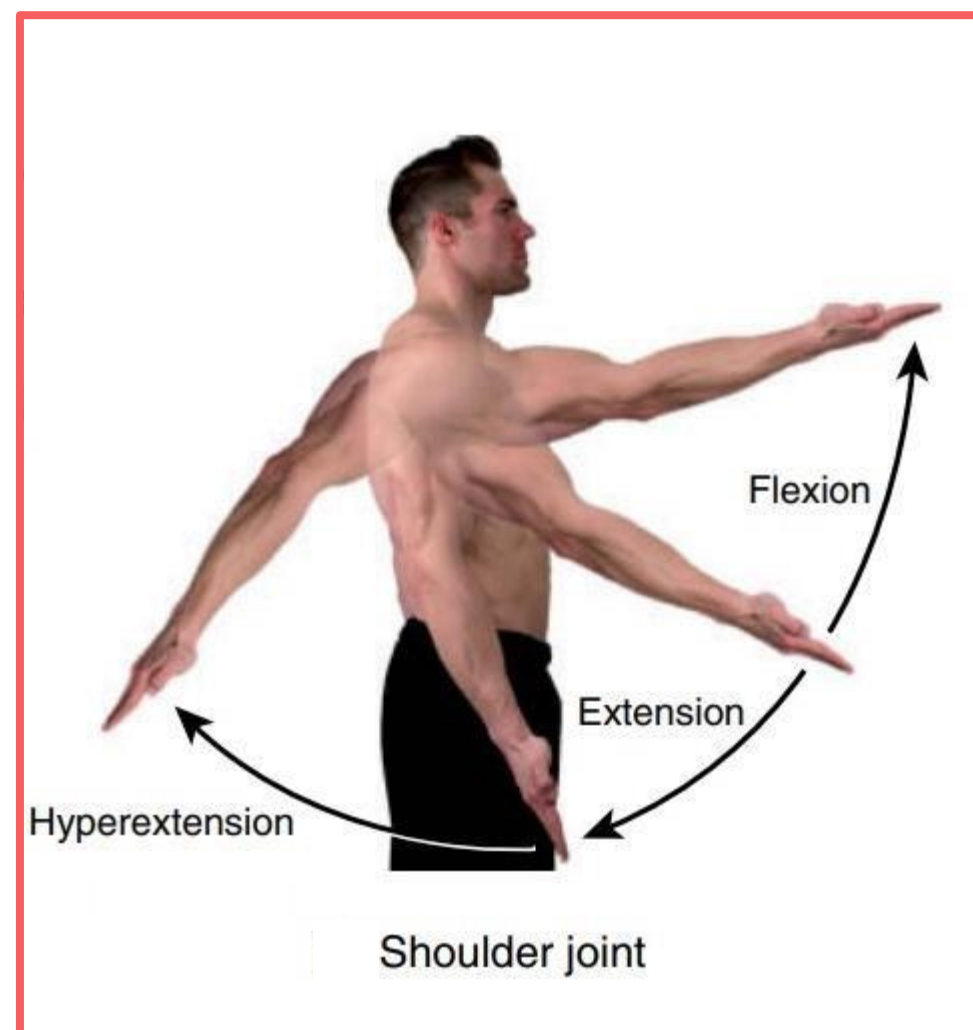
<b>Flexion</b>	A movement that decreases the angle between two body parts at a joint.
<b>Extension</b>	A movement that increases the angle between two body parts at a joint.

Flexion and extension movements can be observed at the elbow joint between the arm and the forearm. When the upper limb is fully extended, the angle between the arm and the forearm is approximately  $180^\circ$ . As this angle decreases from  $180^\circ$  to smaller angles such as  $90^\circ$  or  $50^\circ$ , this movement is termed flexion.



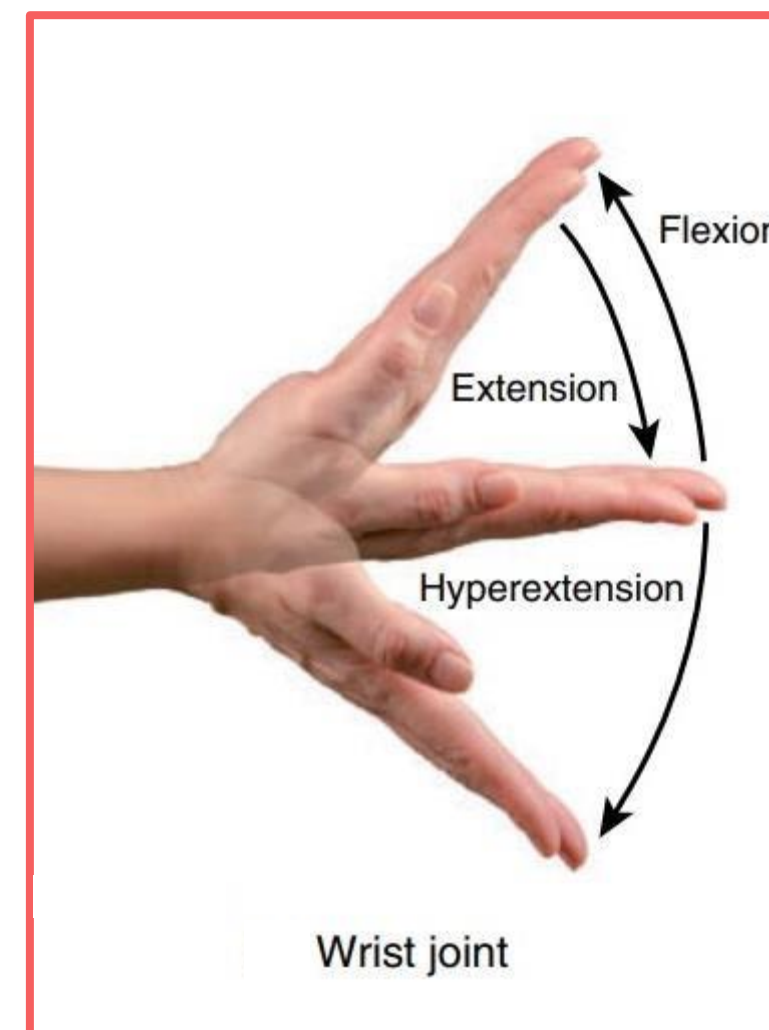
Elbow joint

Between arm and forearm



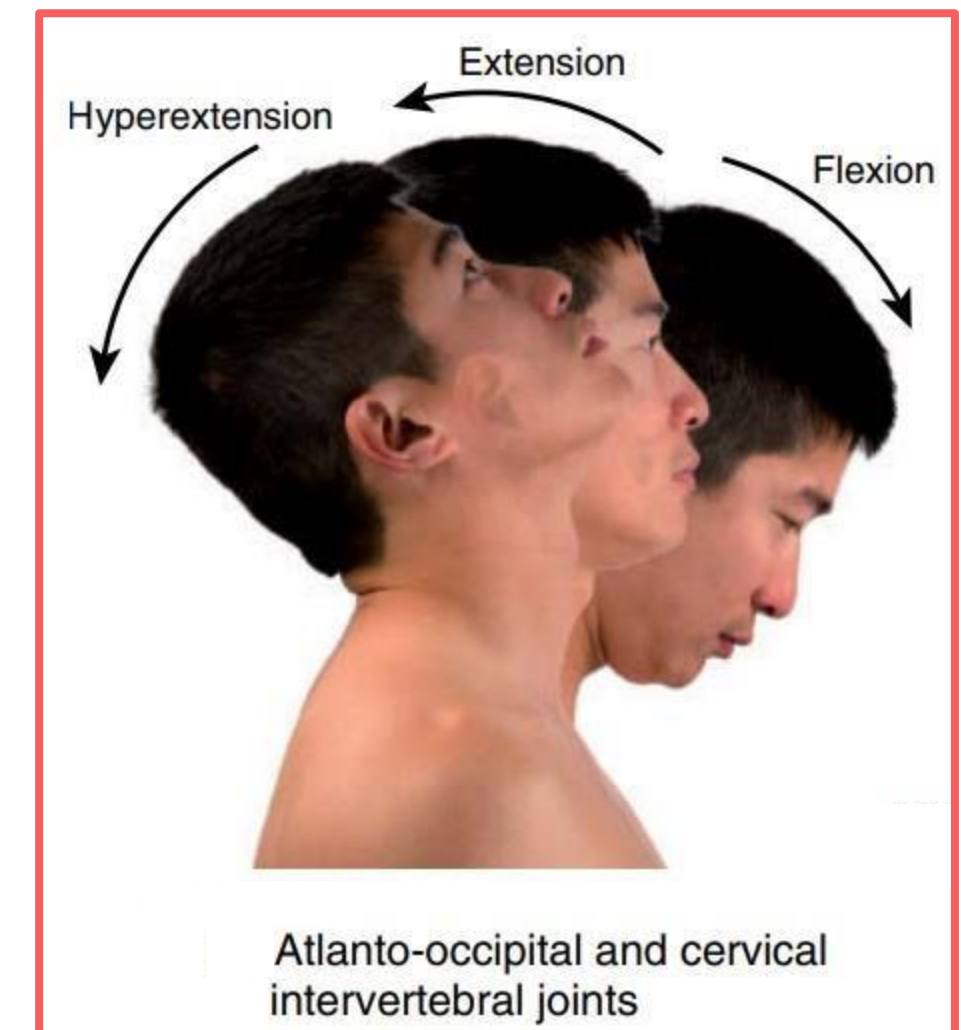
Shoulder joint

Between arm and trunk or shoulder girdle



Wrist joint

Between hand and forearm



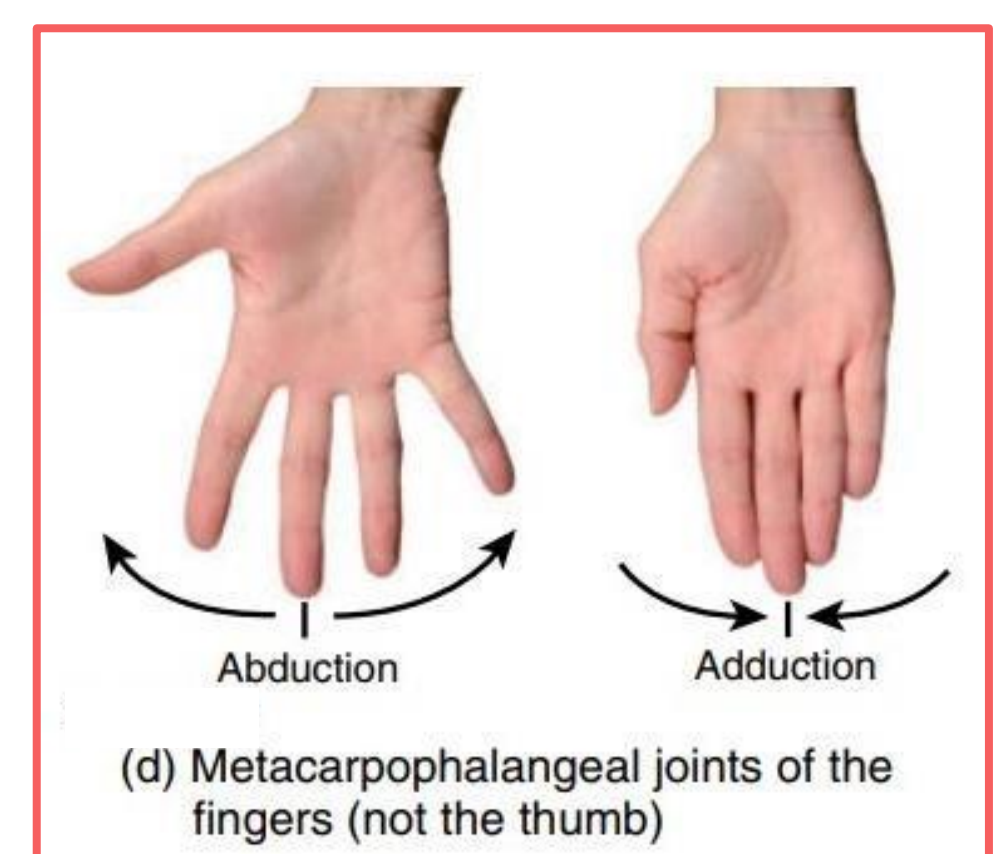
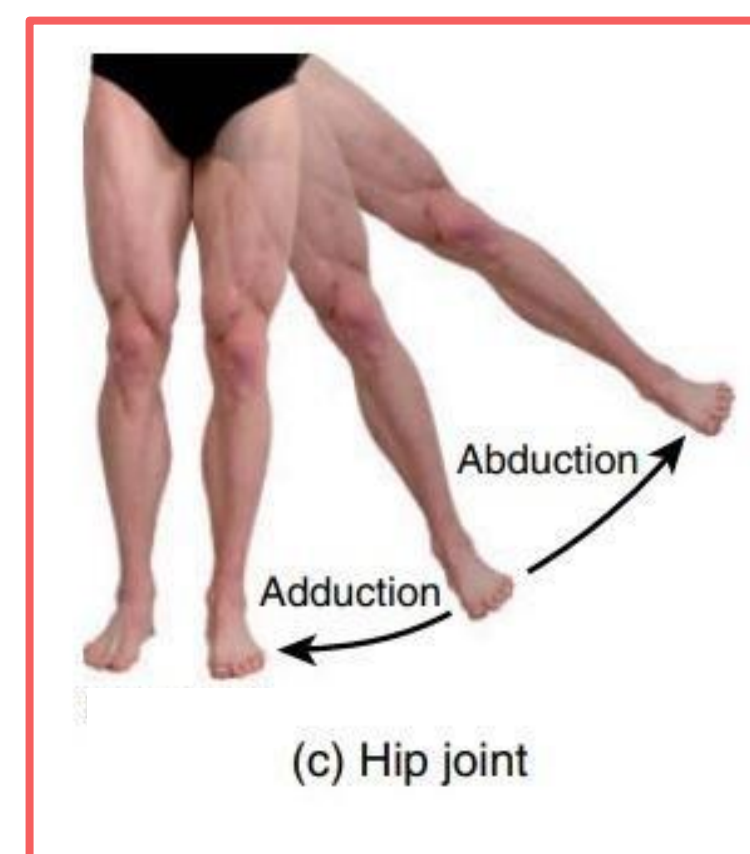
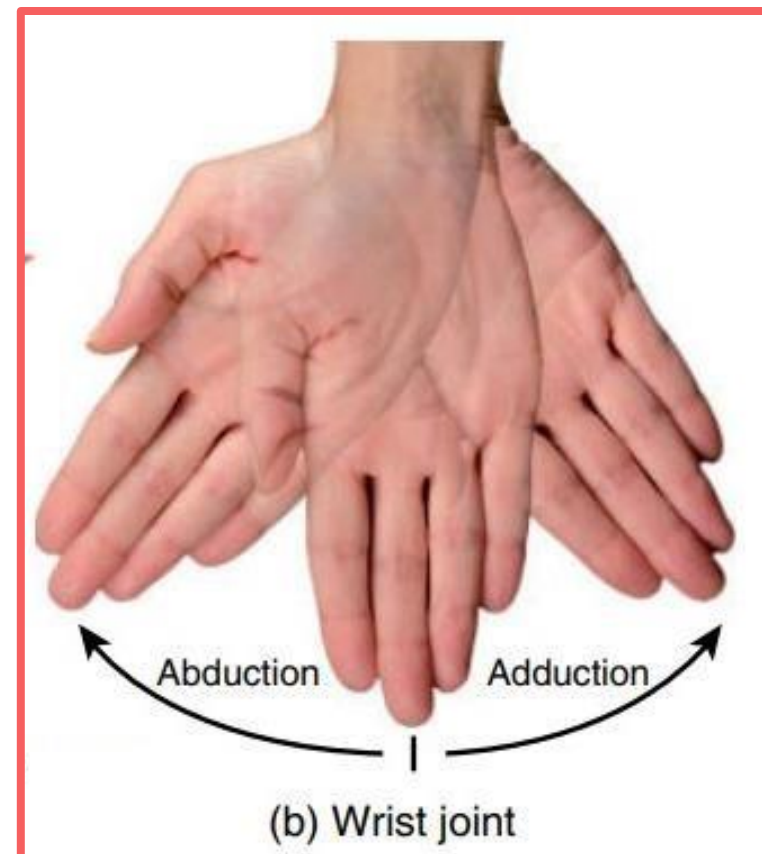
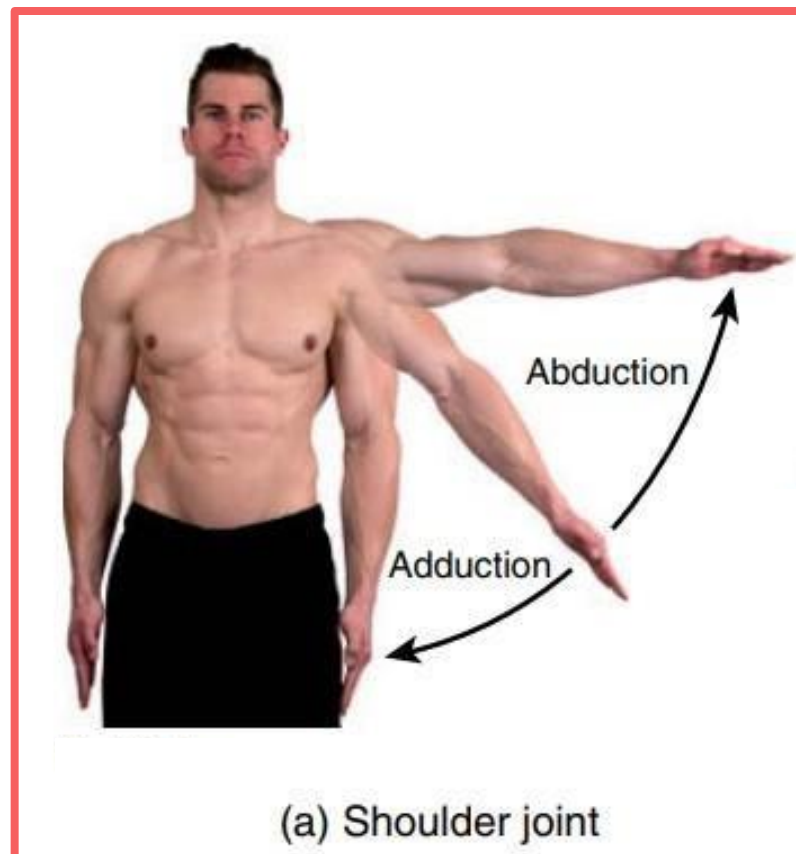
Atlanto-occipital and cervical intervertebral joints

Between head and neck

## ➤ Types of Movements at Synovial Joints:

**Abduction** A movement away from the midline of the body or from the axis of a limb.(The midline of the limb)

**Adduction** A movement toward the midline of the body or toward the axis of a limb.



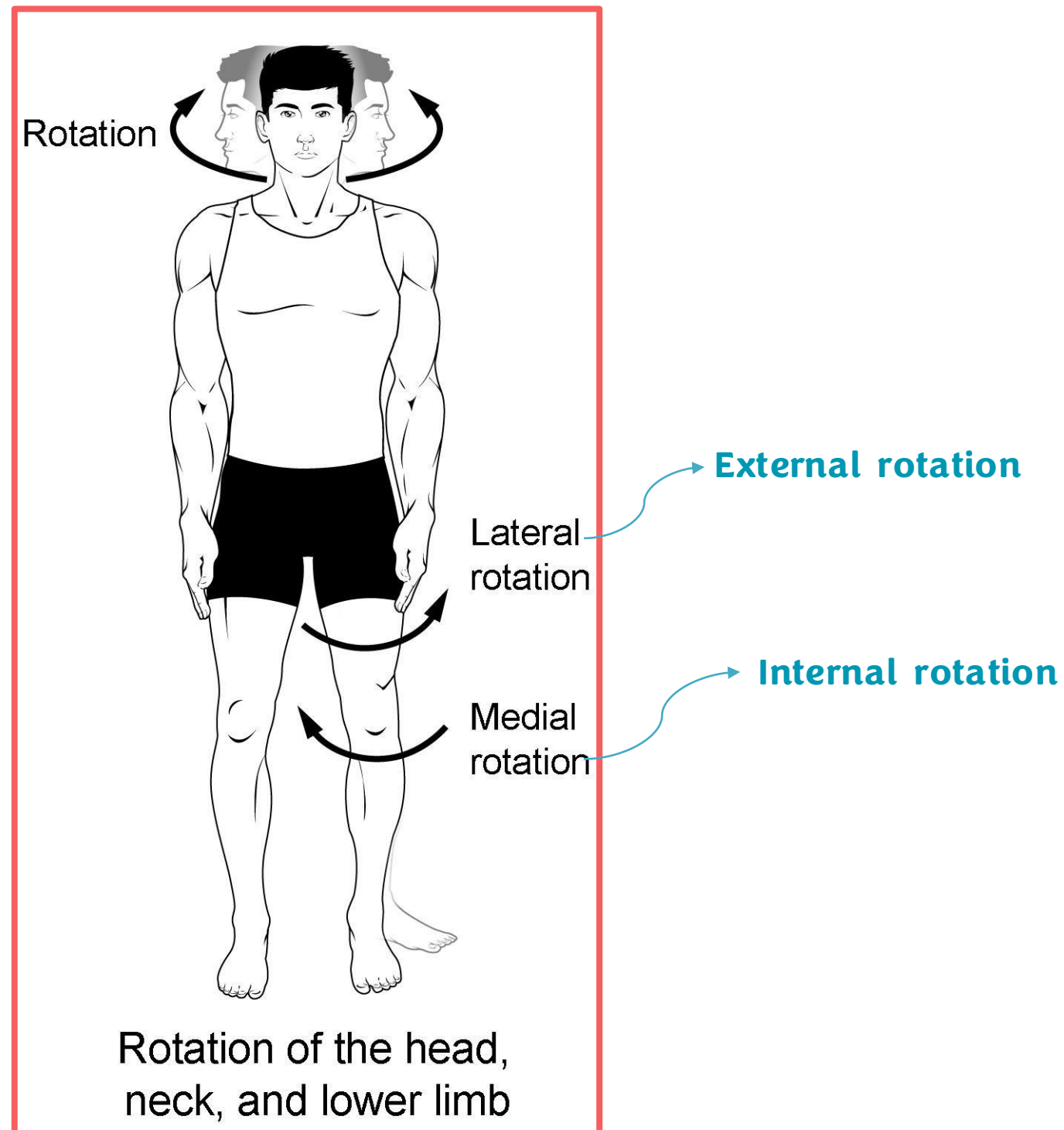
As if we draw an imaginary midline that passes through the middle finger

## ➤ Types of Movements at Synovial Joints:

### Rotation

A movement in which a bone or entire limb turns around its own longitudinal axis.

In the head there are right  
and left rotation



The joints that can make this movement:

1. Shoulder joint
2. Hip joint

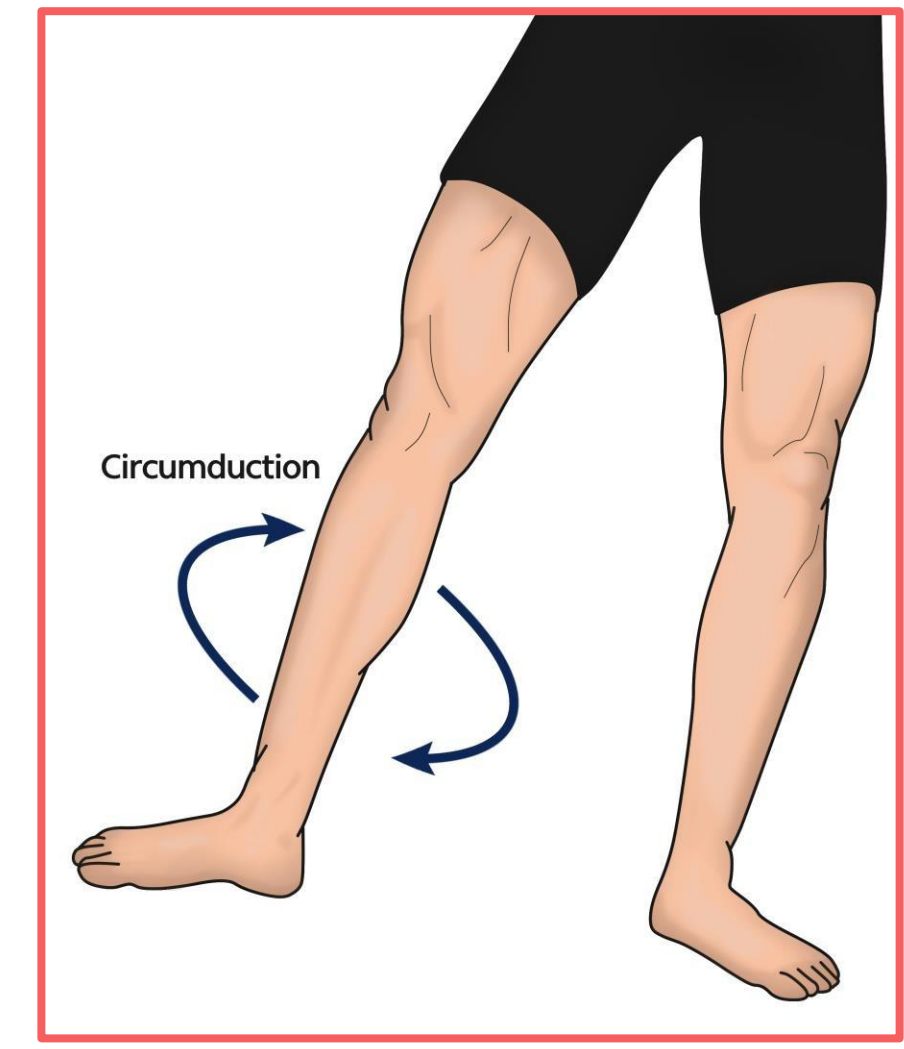
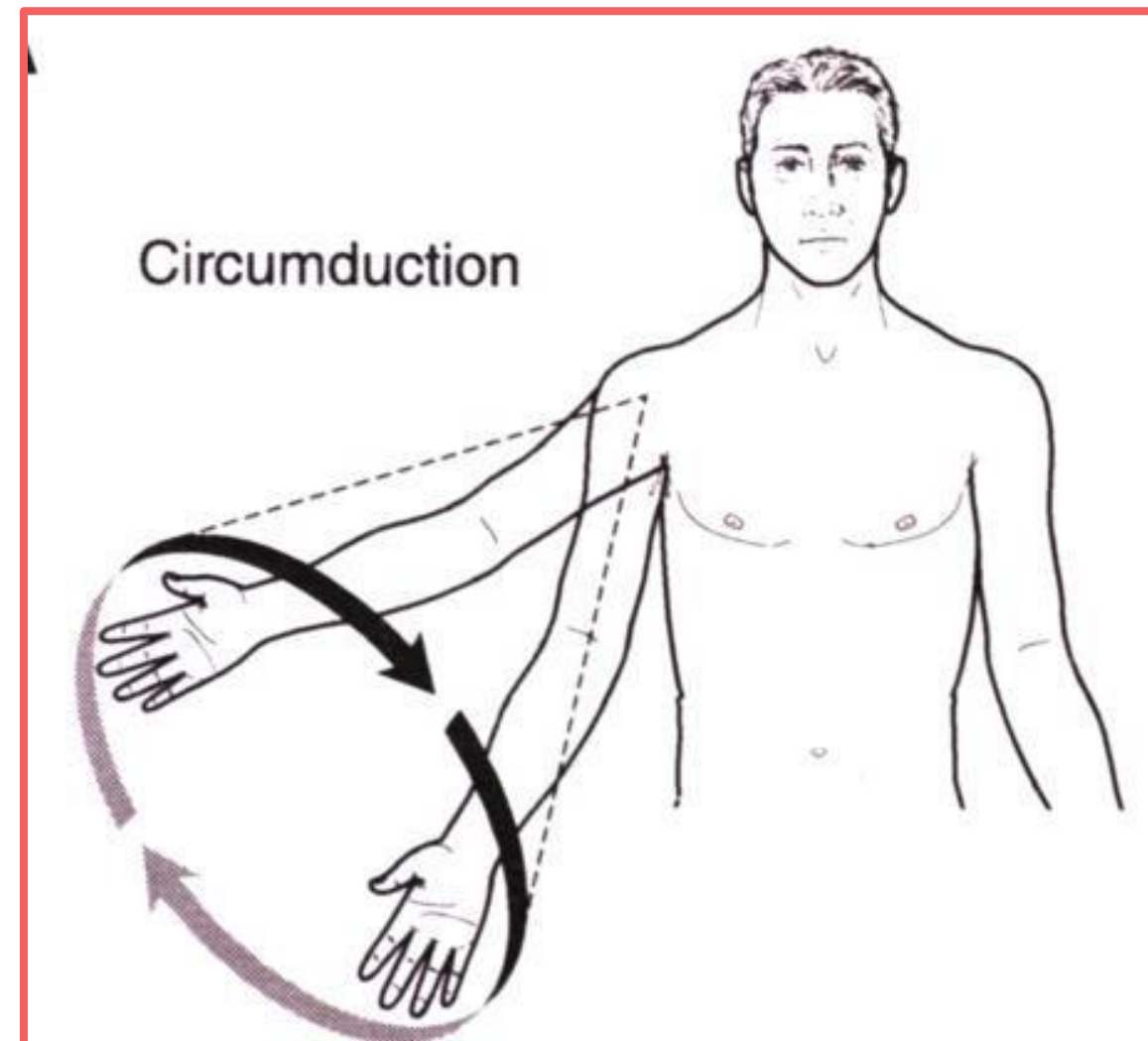
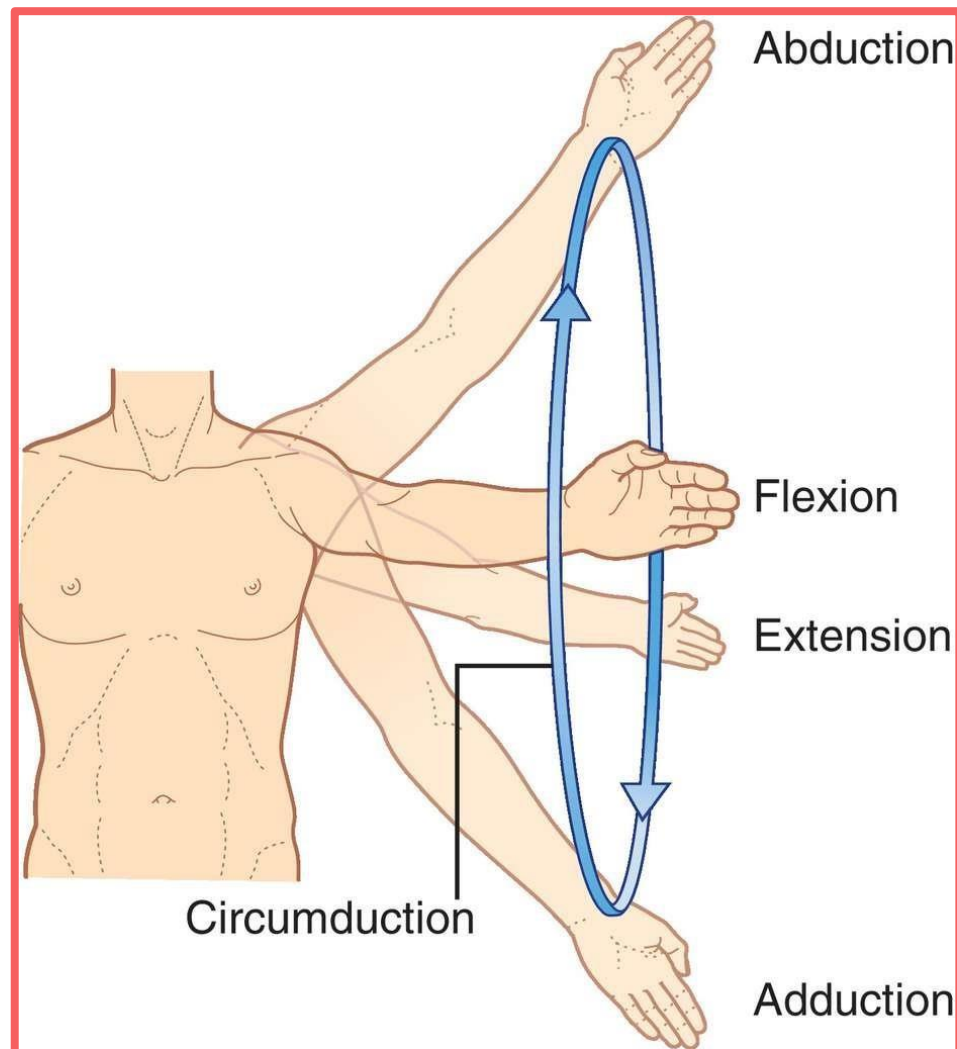
## ➤ Types of Movements at Synovial Joints:

### Circumduction

A circular, cone-like movement of a body part, involving a combination of flexion, abduction, extension, and adduction in successive order.

Circumduction is a combined sequential movement that occurs in the following order: flexion, followed by abduction, then extension, and finally adduction, resulting in a circular motion.

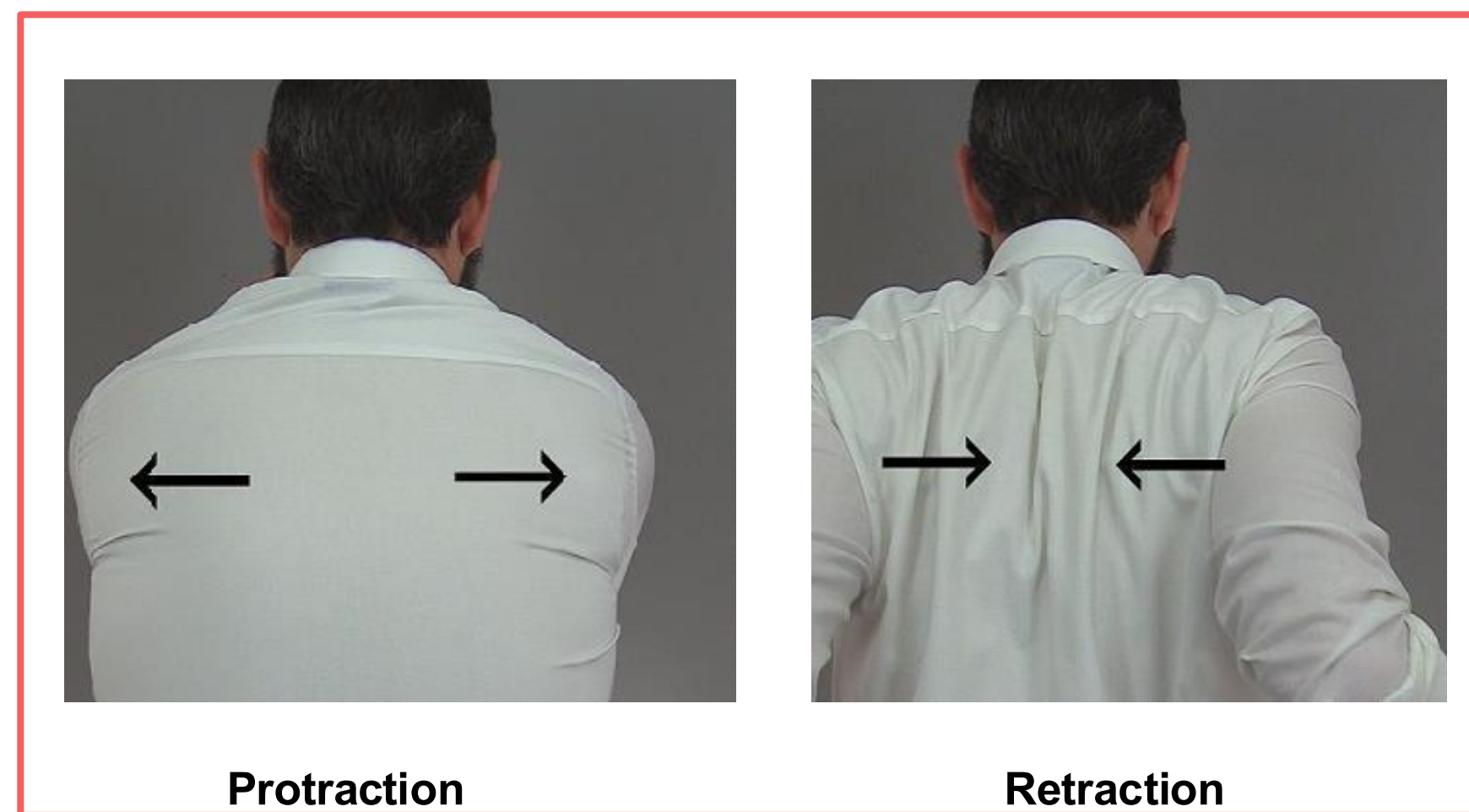
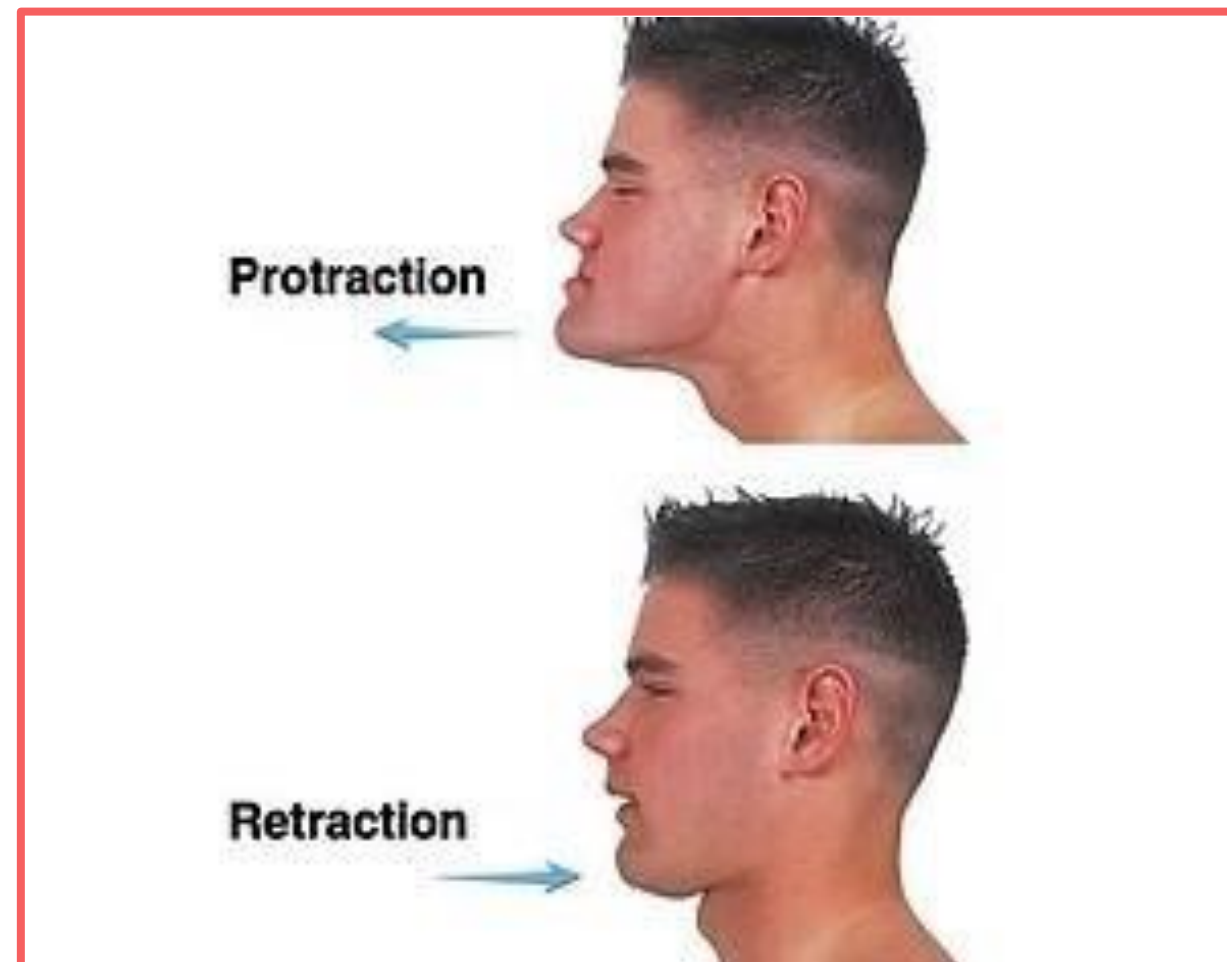
**Flexion → Abduction → Extension → Adduction.**



# Synovial Joints

## ➤ Types of Movements at Synovial Joints:

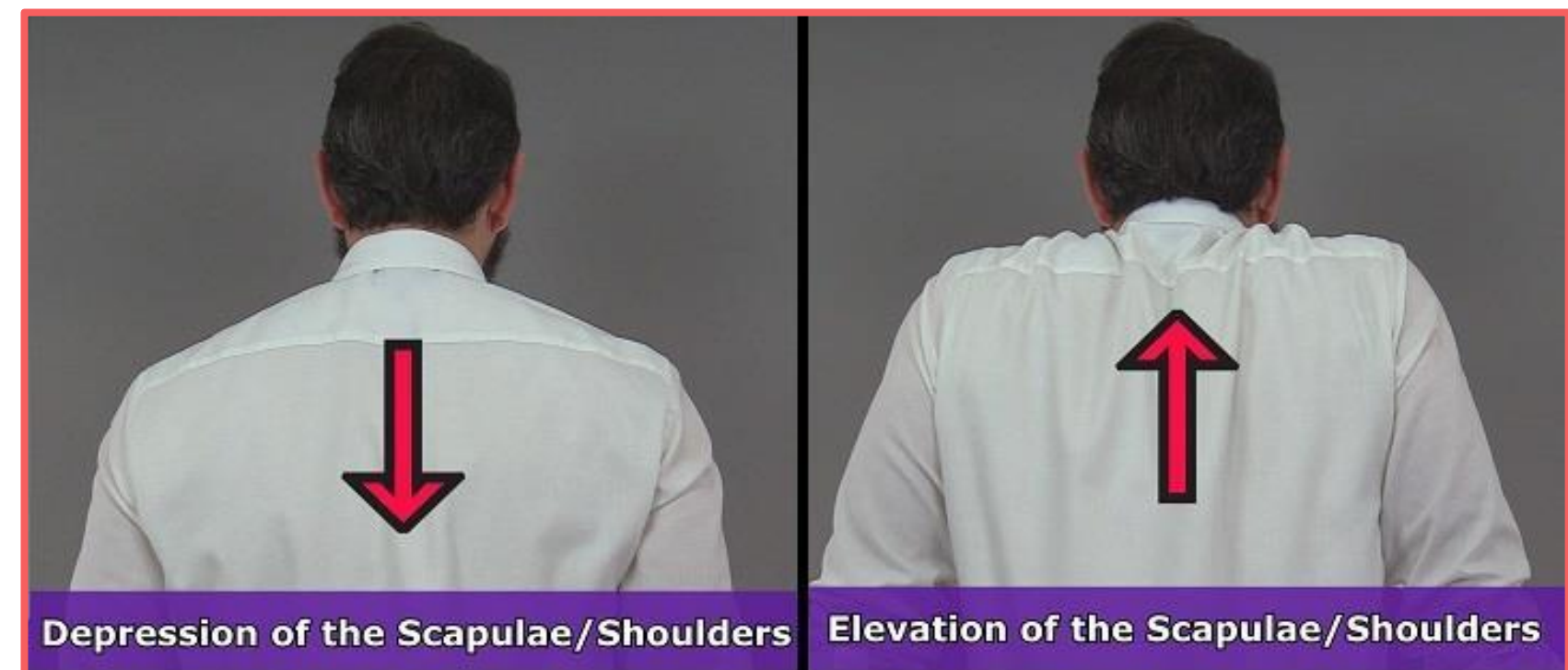
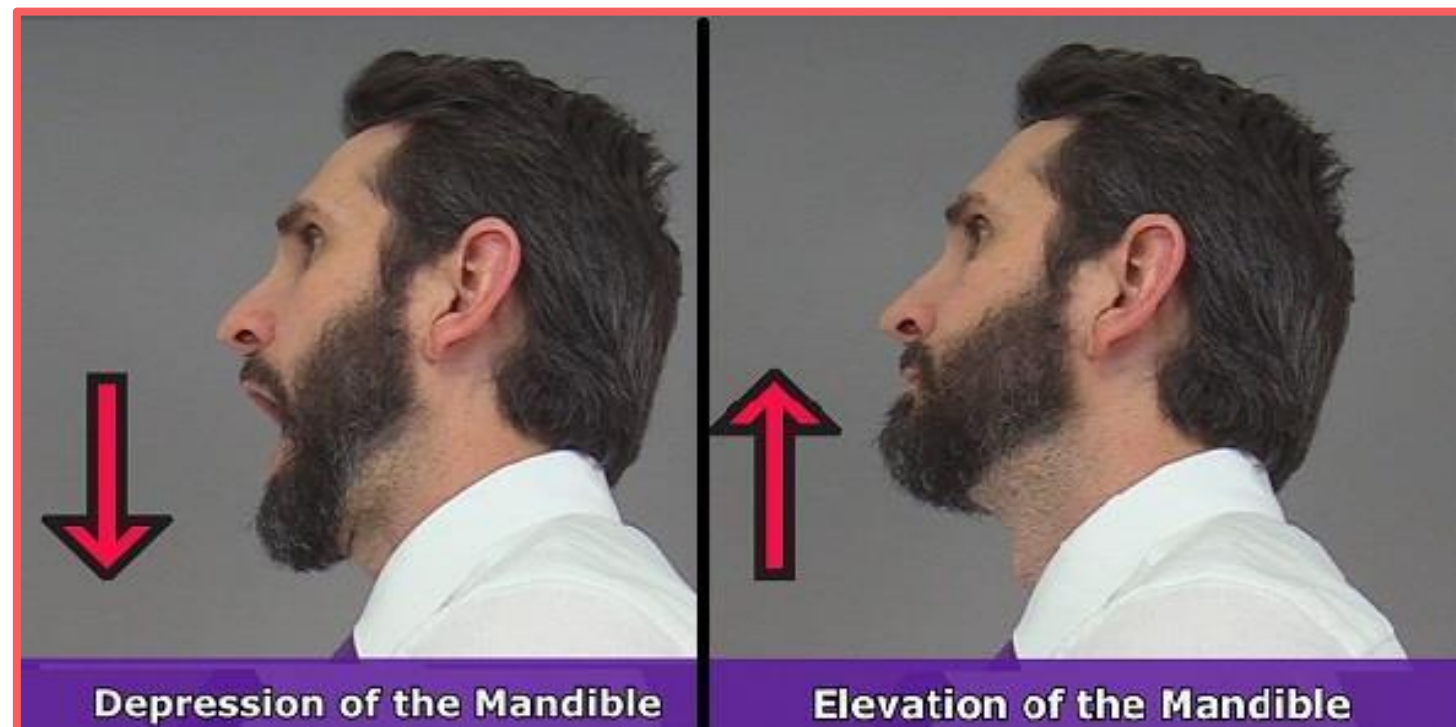
<b>Protraction</b>	A forward movement of a body part on a plane parallel to the ground, e.g., <b>protraction of the mandible and scapula.</b>
<b>Retraction</b>	A backward movement of a previously protracted body part on a plane parallel to the ground, e.g., <b>retraction of the mandible and scapula.</b>



# Synovial Joints

## ➤ Types of Movements at Synovial Joints:

<b>Elevation</b>	An upward movement of a body part, e.g., <b>elevation of the mandible to close the mouth</b> , or <b>lifting of the scapula to shrug the shoulder</b> .
<b>Depression</b>	A downward movement of a body part. e.g., <b>depression of mandible to open the mouth</b> , or <b>depression of the scapula to lower the shoulders</b> .



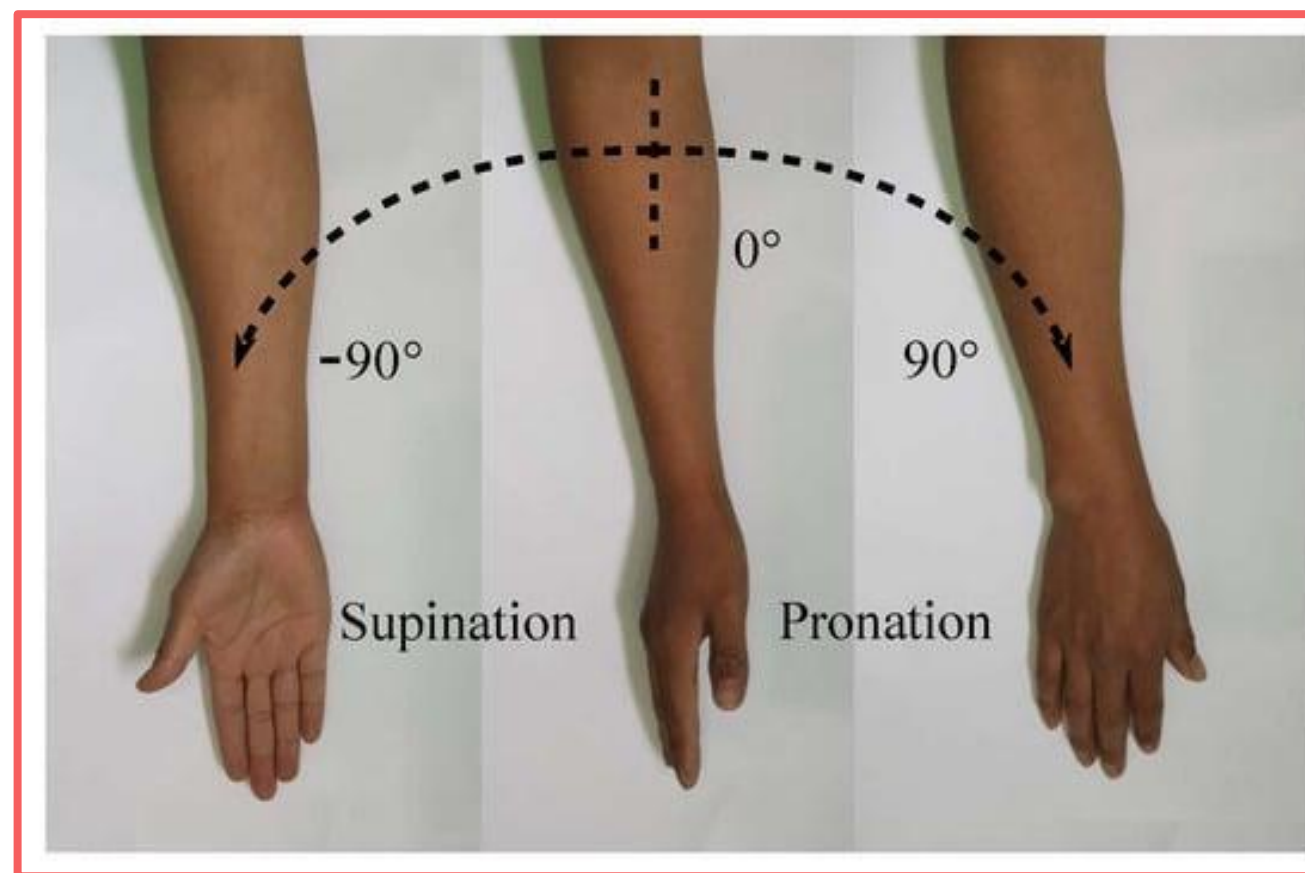
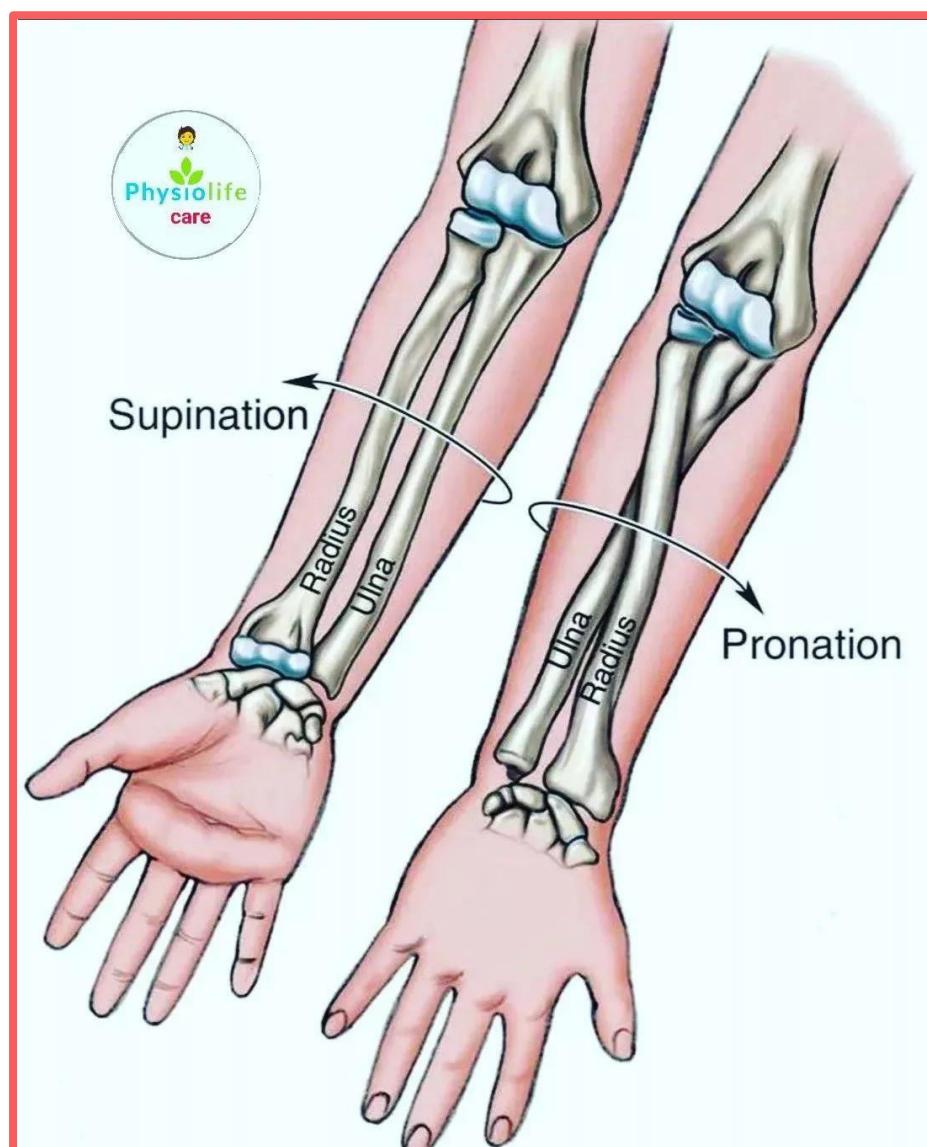
# Synovial Joints

Supination and pronation are specialized rotational movements that occur only at the forearm and hand, involving the radius and ulna, and allow rotation of the hand around its longitudinal axis.

## ➤ Types of Movements at Synovial Joints:

<b>Pronation</b>	A rotational movement of the forearm in which the palm faces downward (inward rotation)
<b>Supination</b>	A rotational movement of the forearm in which the palm faces upward (outward rotation).

When you use your hand to tighten or loosen a screw while holding a screwdriver, the movement is similar to supination and pronation, as it involves rotational movement of the forearm and hand around their longitudinal axis.



➤ Types of Movements at Synovial Joints:

**Opposition**

A movement of the thumb across the palm to touch the tips of the fingers on the same hand.

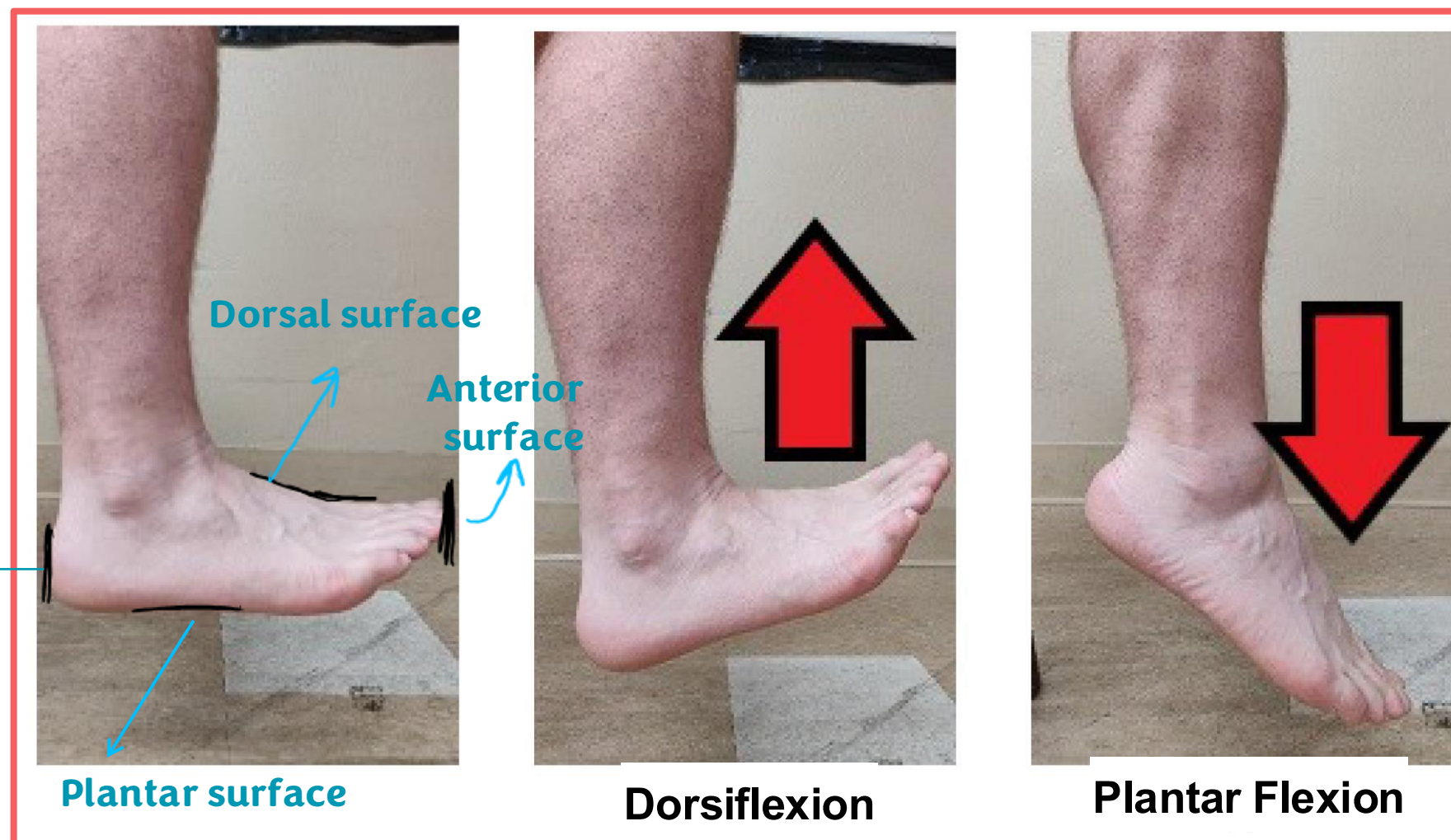


# Synovial Joints

## ➤ Types of Movements at Synovial Joints:

<b>Dorsiflexion</b>	A movement at the ankle joint in which the dorsum (top) of the foot moves upward toward the leg.
<b>Plantar Flexion</b>	A movement at the ankle joint in which the sole of the foot moves downward, as in pointing the toes.

Dorsiflexion is named as such because the term “dorsal” is associated with the anterior surface of the foot, and during this movement the foot is moved upward, resulting in a decrease in the angle between the foot and the leg, which is considered a type of flexion.

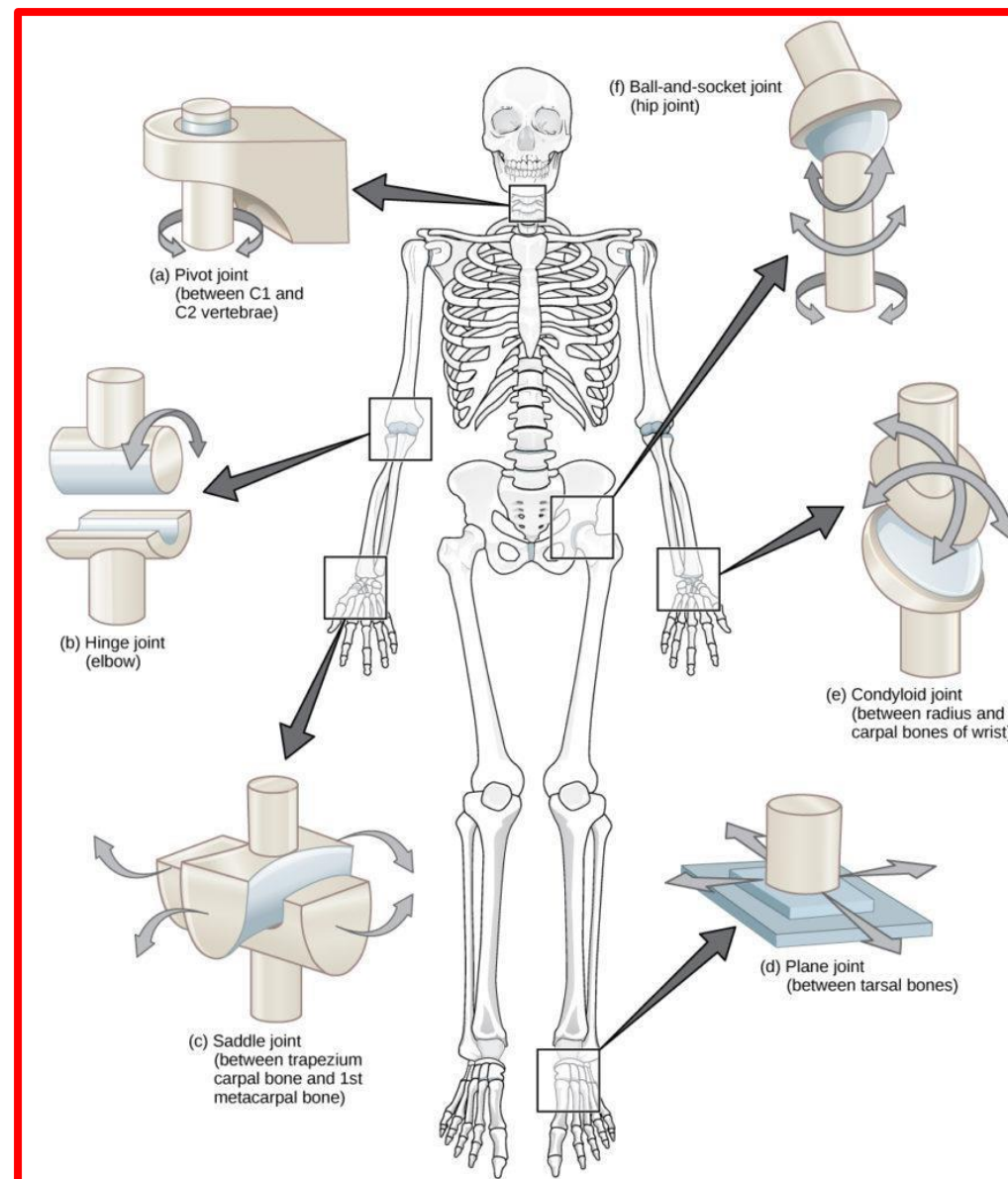


Plantar flexion is named because the term “plantar” is associated with the posterior surface of the foot, and during this movement the foot moves downward, resulting in a decrease in the angle between the foot and the leg, which is considered a flexion-type movement.

When we talk about planter flexion, the angle between the planter surface and the leg (posterior surface) is 270, so after doing this movement the angle is reduced.

## Types of Synovial Joint (based on the shape of their articular surfaces)

1. Hinge Joint.
2. Ball and Socket Joint.
3. Gliding (plane) Joint.
4. Pivot Joint.
5. Ellipsoid (condyloid) Joint.
6. Saddle Joint.



## ➤ Types of Synovial Joint:

### 1. Hinge Joint Like the hinge of the door

#### Description

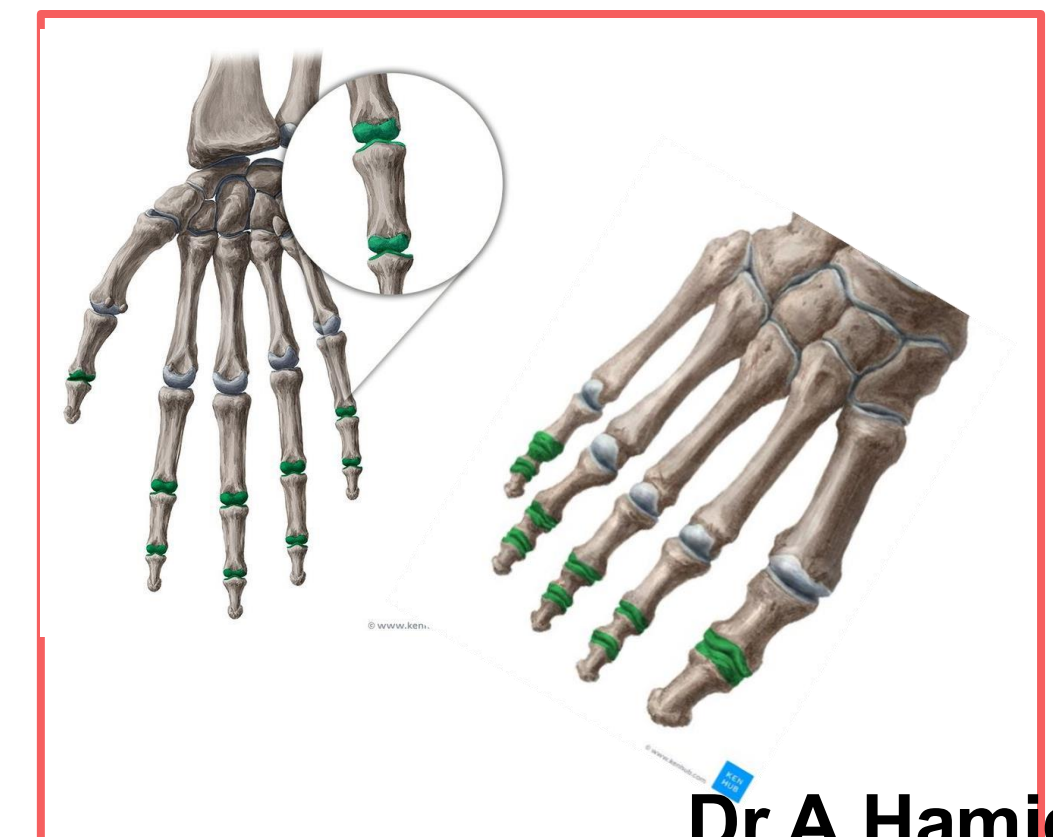
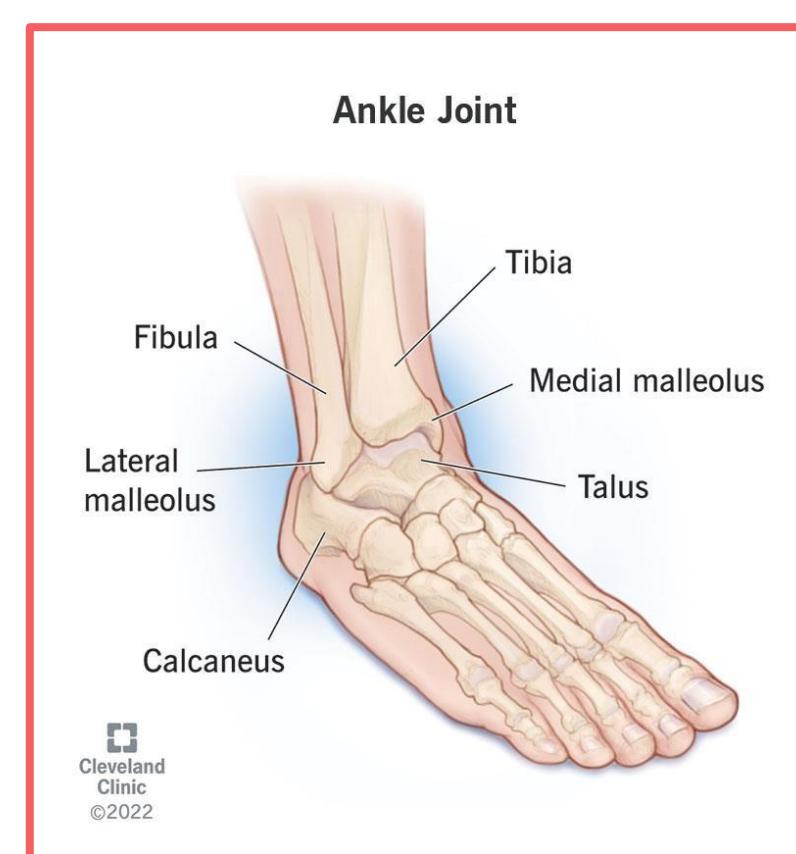
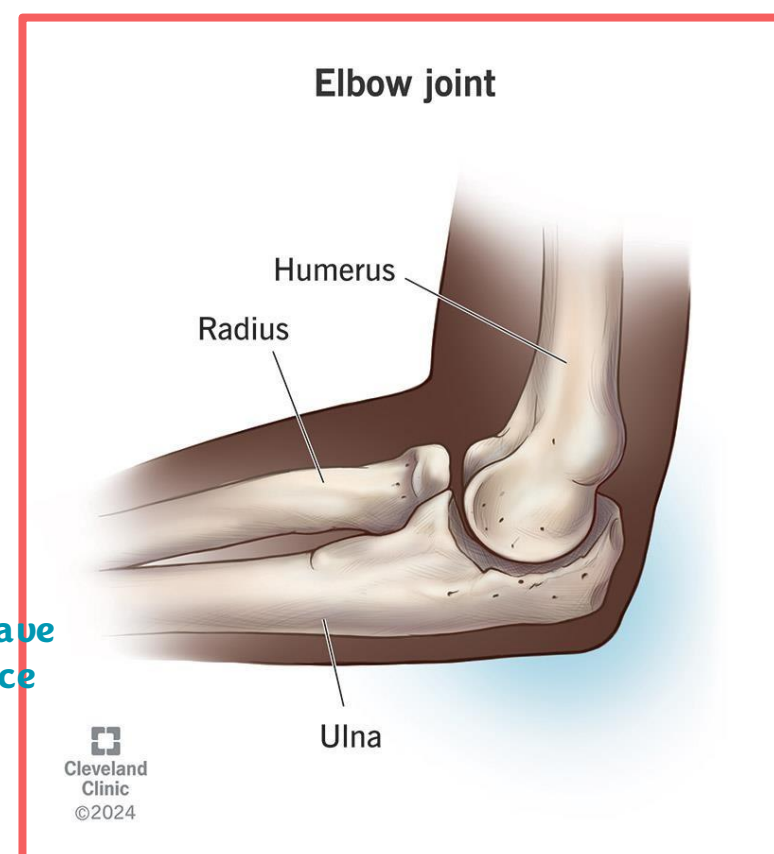
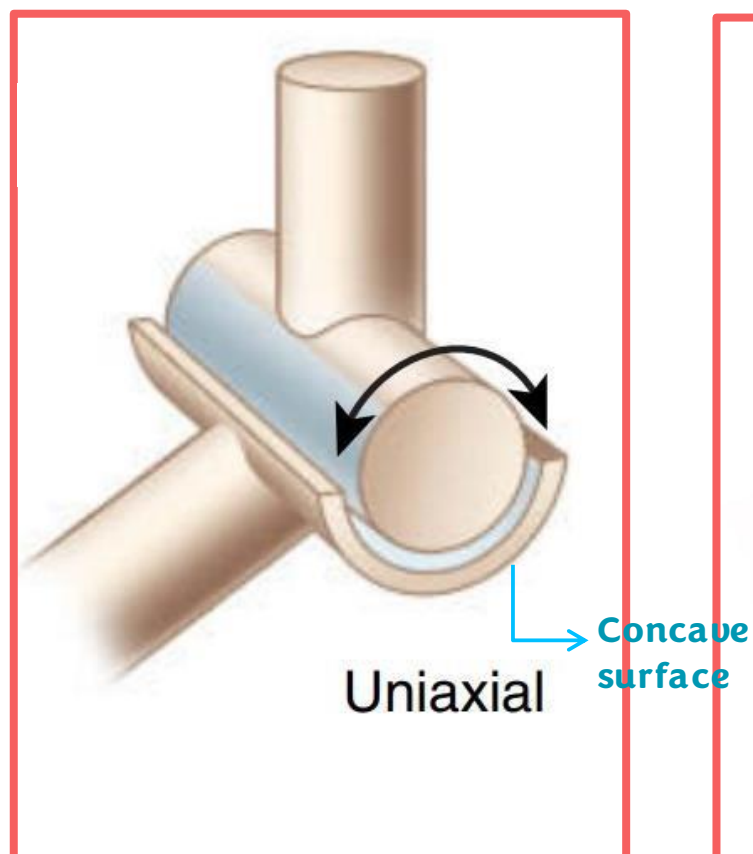
- The convex surface of one bone fits into the concave surface of another.

#### Movement

- As the name implies, allows movement primarily in one plane (uniaxial), flexion and extension, similar to the motion of a hinged door.

#### Example

- Elbow joint
- Ankle joint *Dorsal and plantar flexion*
- Interphalangeal joints *The interphalangeal joints are located between the phalanges of the fingers and toes, specifically between the proximal and middle phalanges and between the middle and distal phalanges*



# Synovial Joints

## ➤ Types of Synovial Joint:

### 2. Ball and Socket Joint

#### Description

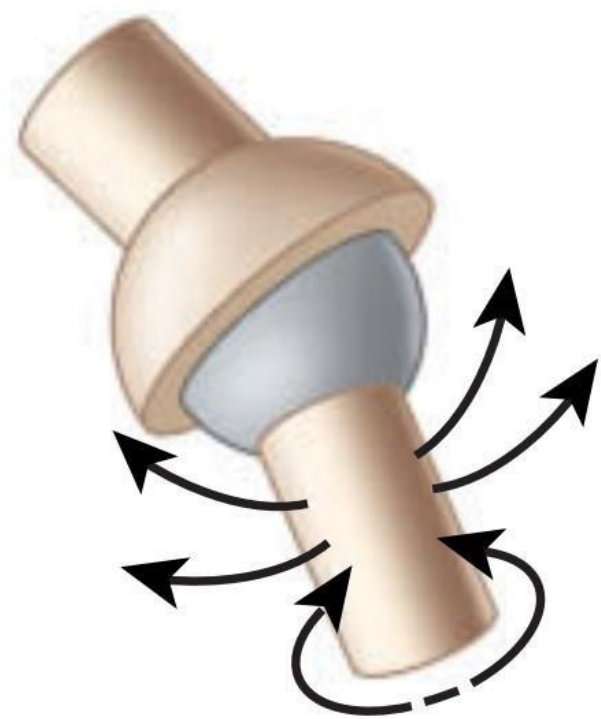
- A rounded, convex surface of one bone fits into the cup-like socket of another.

#### Movement

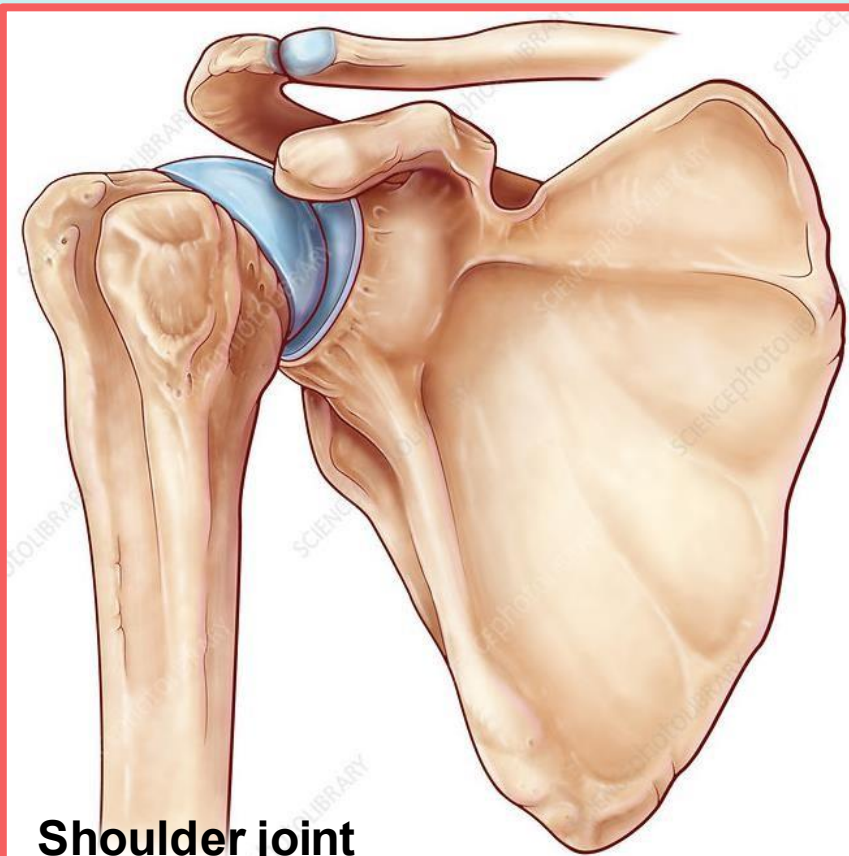
- Allows movement around three axes (triaxial): flexion–extension, abduction–adduction, and rotation. *It gives a wide range of movement*

#### Example

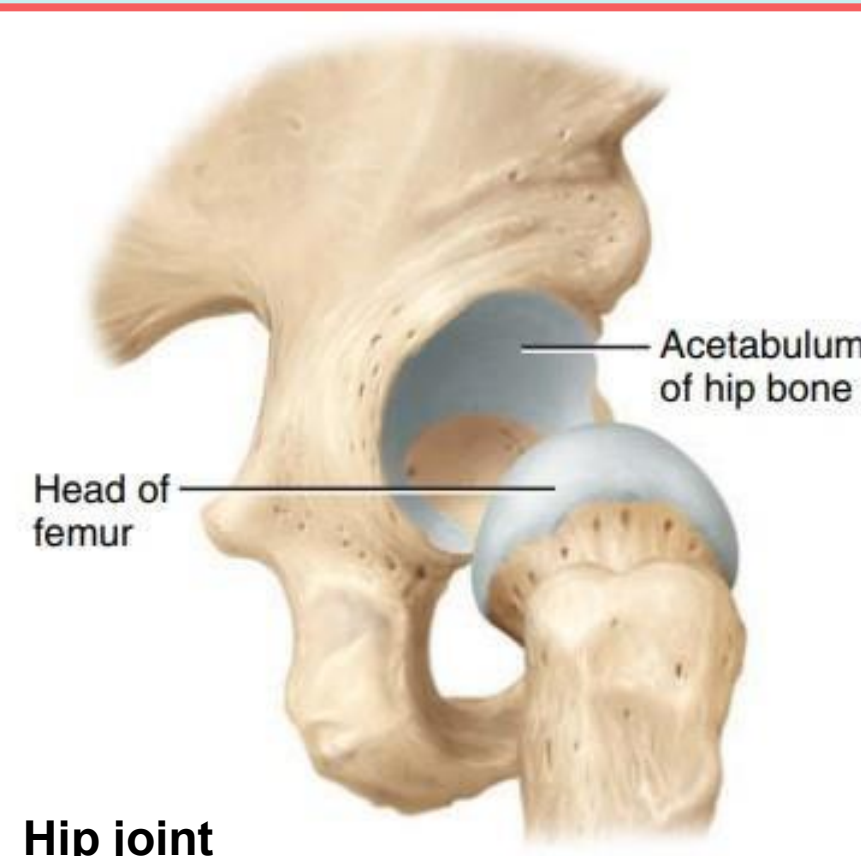
- **Shoulder joint.** *The head of the humerus articulates with the glenoid cavity of the scapula.*
- **Hip joint.** *The head of the femur articulates with the acetabulum of the hip bone*



Triaxial



Shoulder joint



Hip joint

## ➤ Types of Synovial Joint:

### 3. Gliding (plane) Joint *Between two flat surfaces (the flat surface of the bone).*

#### Description

- The articular surfaces are nearly flat, allowing bones to glide over one another.

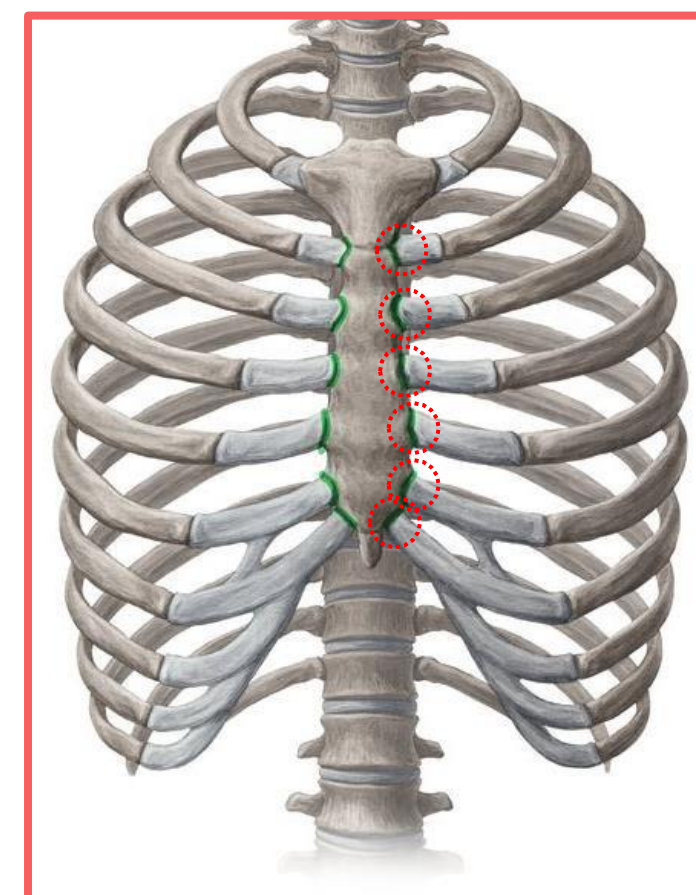
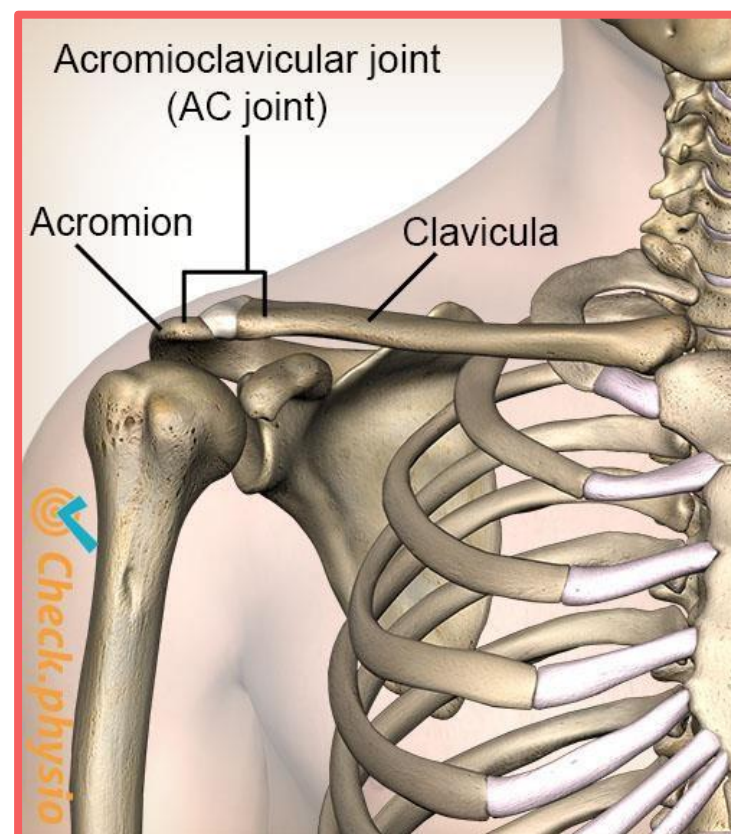
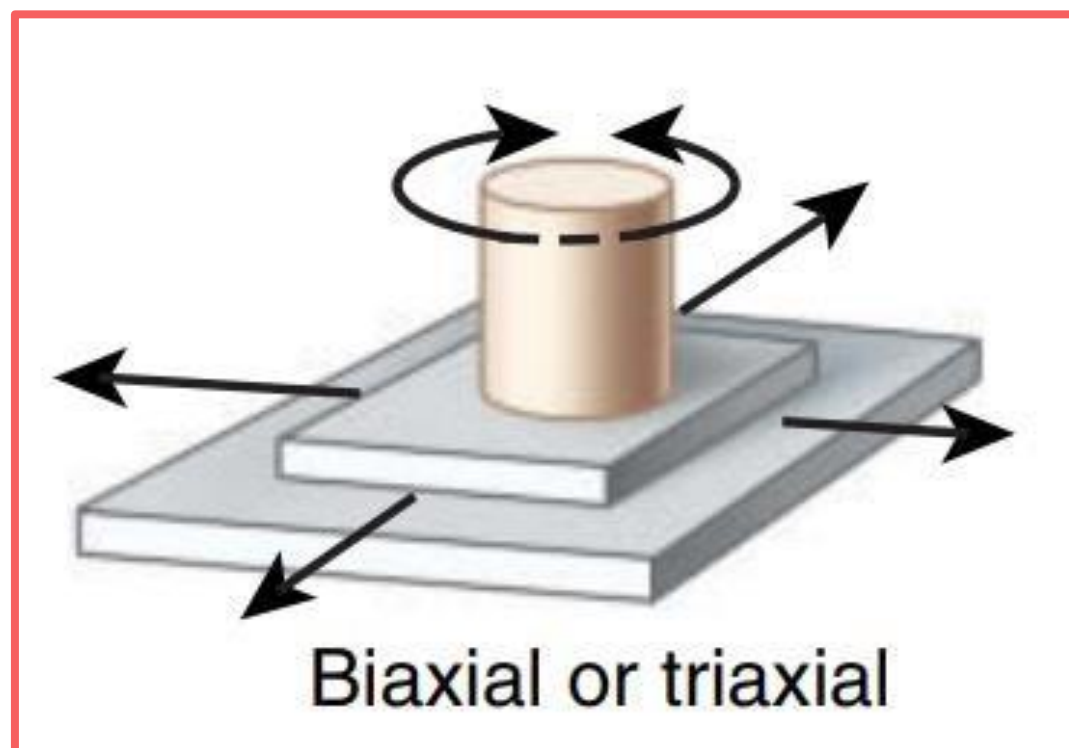
#### Movement

- Permits sliding or gliding movements in several directions, including side-to-side and back-and-forth, with slight rotation.

#### Example

- Acromioclavicular joints (between the acromion of the scapula and the clavicle)
- 2<sup>nd</sup> - 7<sup>th</sup> costosternal joints (between the 2<sup>nd</sup> - 7<sup>th</sup> costal cartilages and sternum)

Another example: Between carpal bones themselves



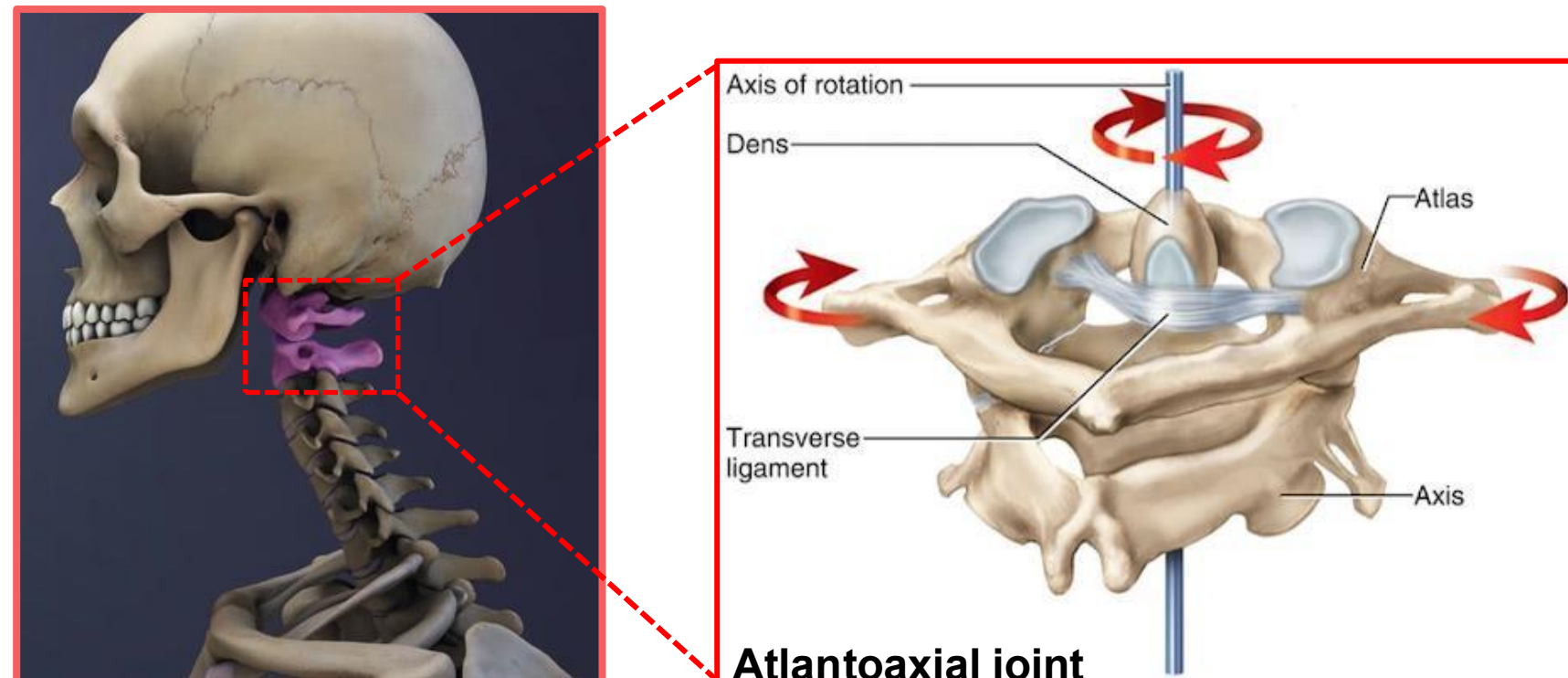
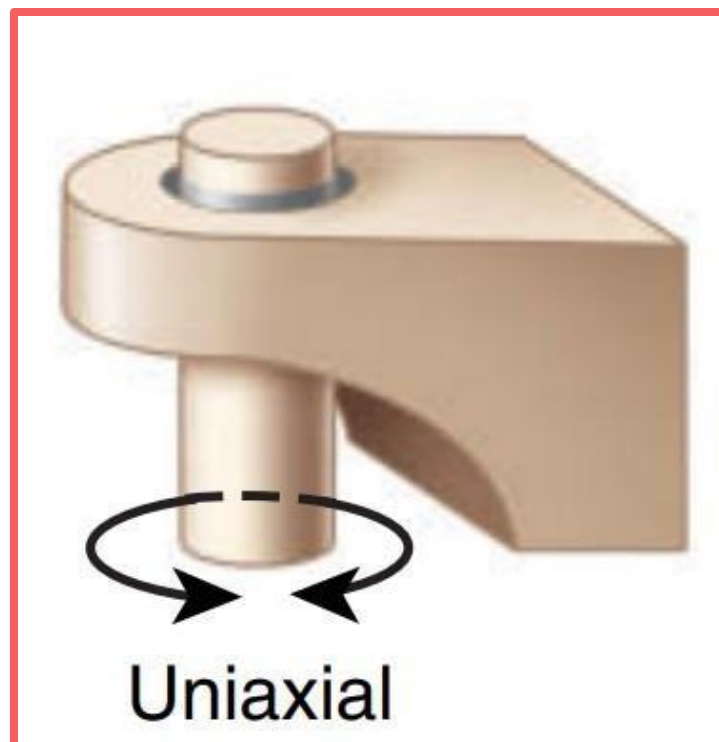
For the expansion of the chest in breathing

# Synovial Joints

## ➤ Types of Synovial Joint:

### 4. Pivot Joint

<b>Description</b>	<ul style="list-style-type: none"> <li>A rounded or pointed surface of one bone articulates with a ring formed by another bone and a ligament.</li> </ul>
<b>Movement</b>	<ul style="list-style-type: none"> <li>Allows rotation around its longitudinal axis (uniaxial).</li> </ul>
<b>Example</b>	<ul style="list-style-type: none"> <li>Atlantoaxial joint (<b>between the atlas and axis vertebrae</b>). (Since they both don't have body so there's no cartilage between them (cartilaginous joint) like other vertebrae).</li> </ul>



Notice the Transverse ligament

Similar to the Ball & Socket joint, here are the differences:

1) Ball & Socket joint has a spherical shape while condyloid has an oval shape

2) Ball & Socket joint is multiaxial while condyloid is biaxial

## ➤ Types of Synovial Joint:

### 5. Ellipsoid (condyloid) Joint

#### Description

- The oval (elliptical) convex surface of one bone fits into the elliptical concave surface of another.

#### Movement

- Permits movement in two planes (biaxial):
  - Flexion and extension around a transverse axis.
  - Abduction and adduction around an anteroposterior axis.

#### Example

- Wrist joint (radiocarpal joint)
- Metacarpophalangeal joints between the metacarpals and proximal phalanges of digits II–V.

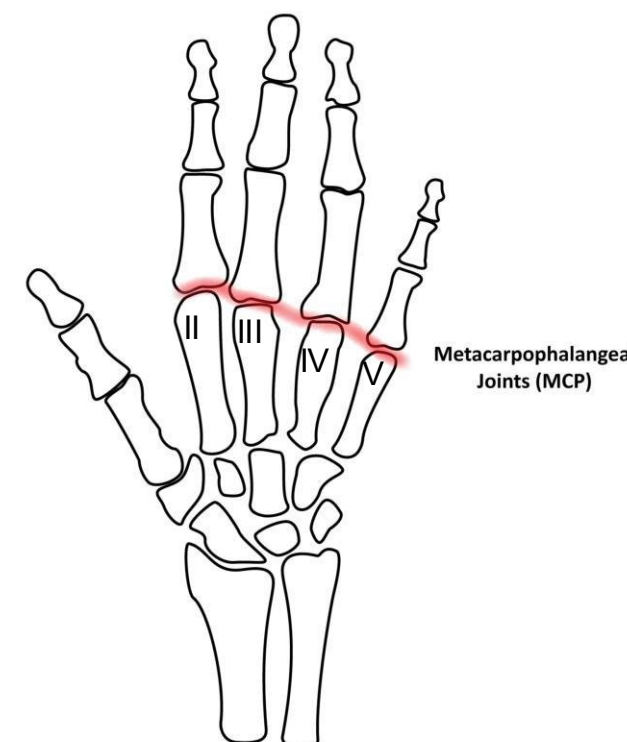
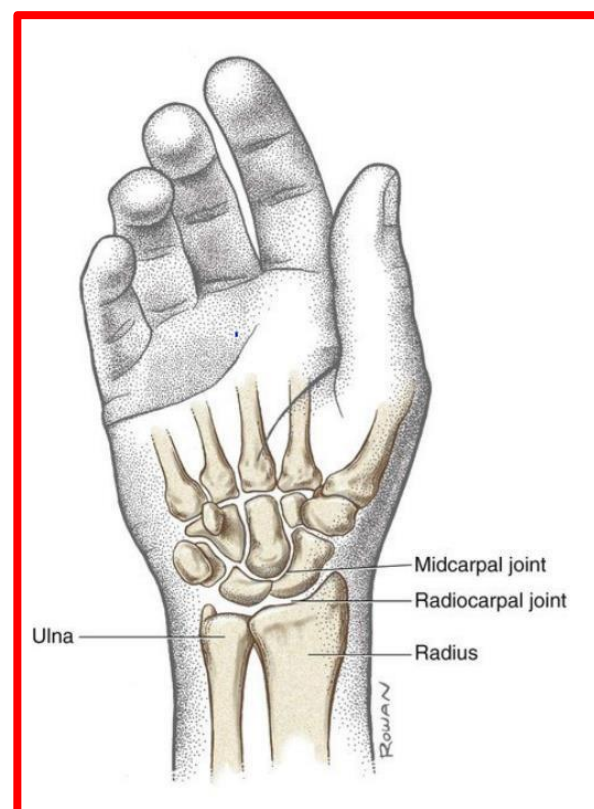
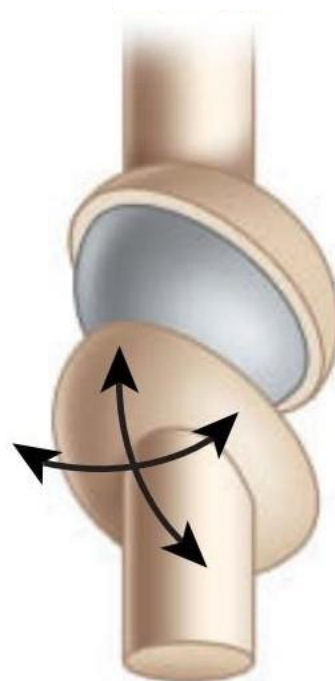
Multiaxial:  
1) Flexion & Extension  
2) Adduction & Abduction  
3) Rotation

Biaxial:  
1) Flexion & Extension  
2) Adduction & Abduction

Uniaxial:  
1) Flexion & Extension

- Condyloid is biaxial while Hinge joint is uniaxial

Biaxial



# Synovial Joints

الفارس الراكب على السرج "تشبيه"

## ➤ Types of Synovial Joint:

### 6. Saddle Joint

#### Description

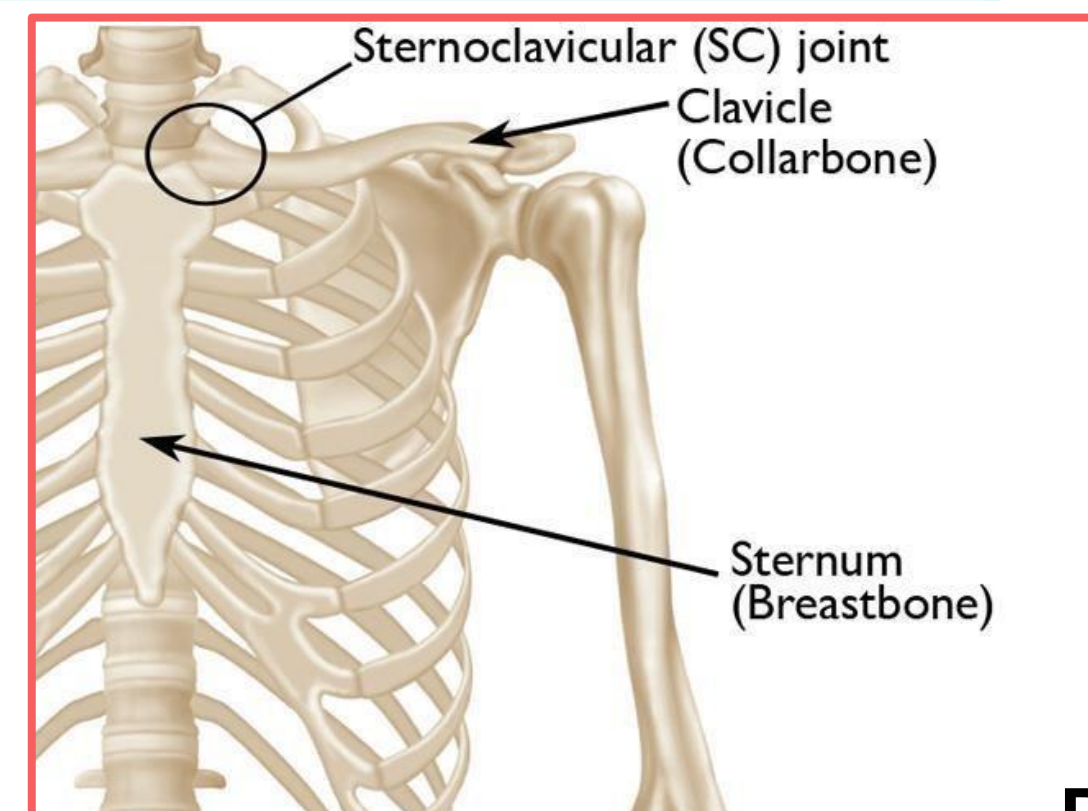
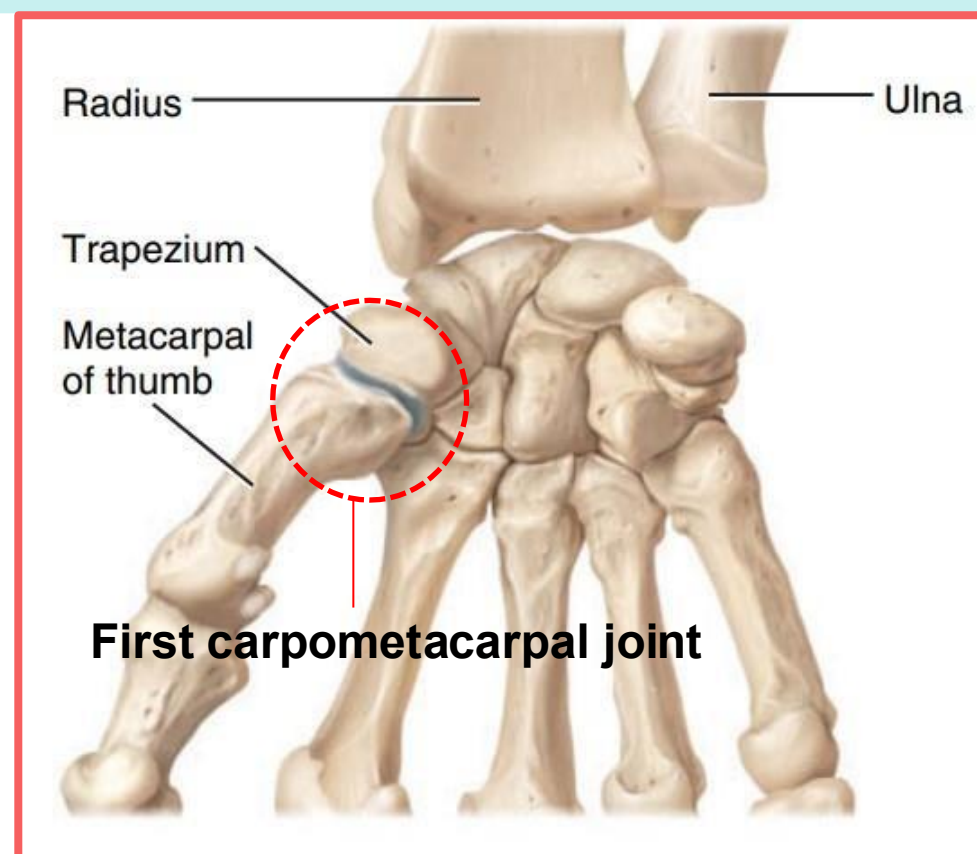
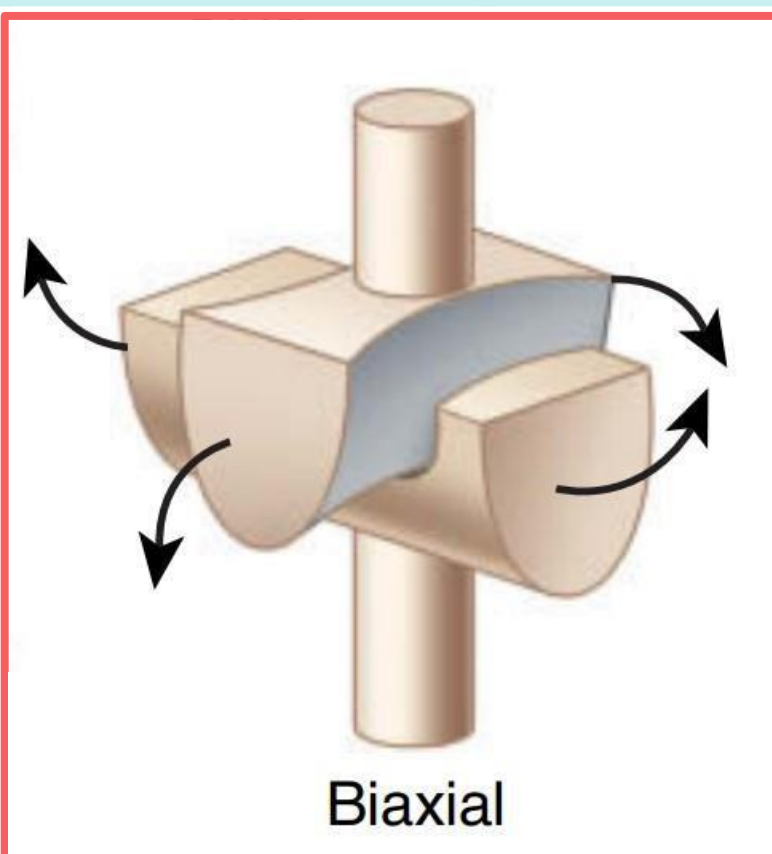
- The articular surface of one bone is saddle-shaped, while the surface of the other bone fits into it like a rider on a saddle.

#### Movement

- Biaxial (flexion–extension and abduction–adduction) with limited circumduction.

#### Example

- First carpometacarpal joint (at the thumb): between the trapezium of the carpus and metacarpal of the thumb
- Sternoclavicular joints (between the manubrium of the sternum and the clavicle)



# Synovial Joints

Temporo-Mandibular joint has 2 joints

1) Hinge joint: Flexion & Extension

Example: When you open your jaw, your jaw extends downwards (depression) then it elevates back to its original position (elevation)

2) Plane joint: When you open your mouth very widely (like yawning), The condyle bone slides against the mandibular fossa (temporal bone) and protracts

## ➤ Examples of Major Synovial Joints

### Temporo-Mandibular Joint (TMJ)

#### Articulation

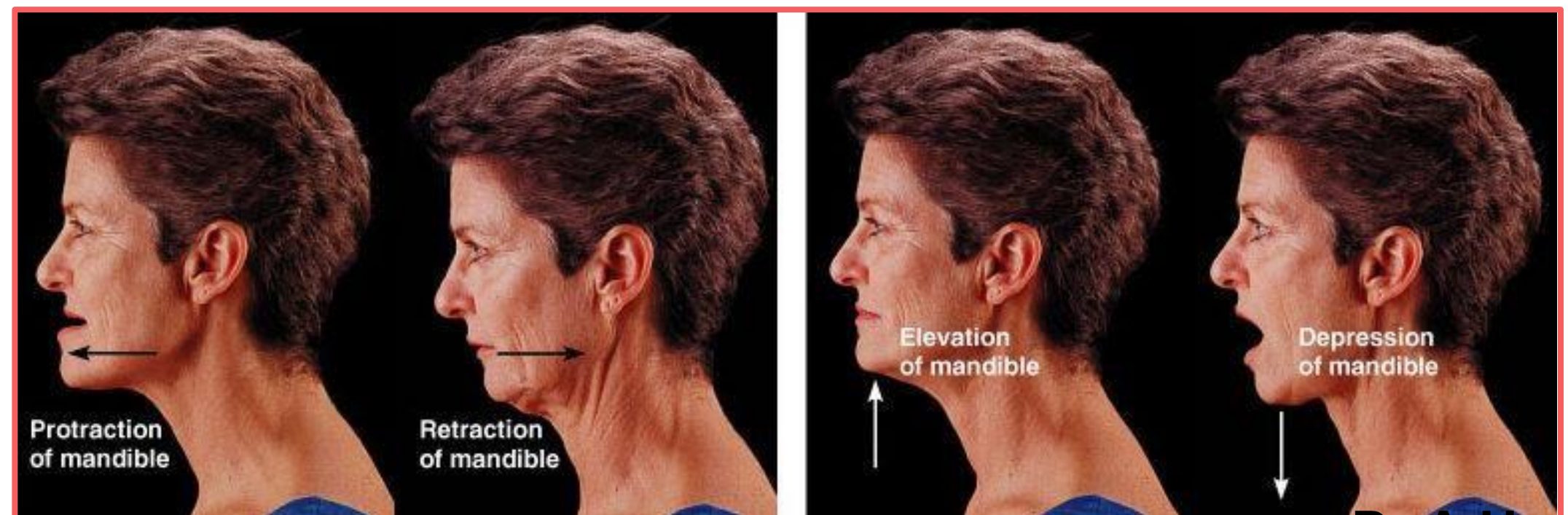
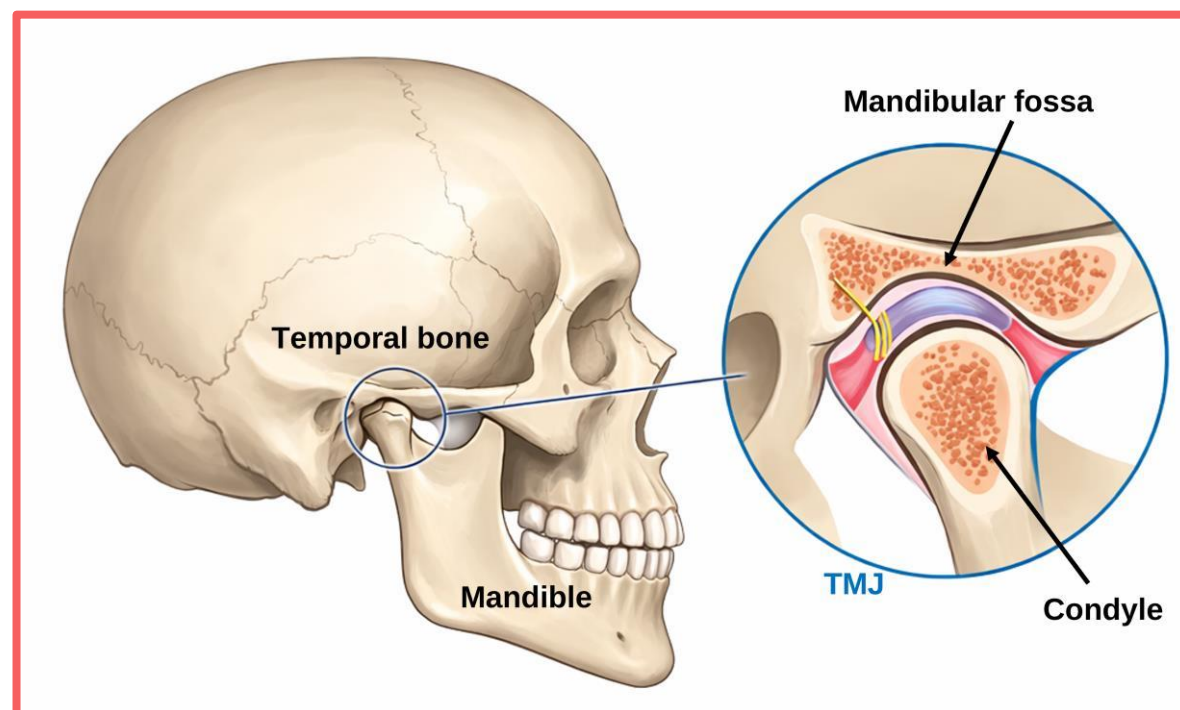
- Formed by the condylar process of the mandible and the mandibular fossa of temporal bone.

#### Type

- A combined hinge and plane joint.
- It is the only freely movable joint between skull bones.

#### Movements

- Depression (jaw opening) and elevation (jaw closing).
- Protraction (moving the mandible forward) and Retraction (moving the mandible backward).
- Lateral (side-to-side) movement – moving the jaw left and right



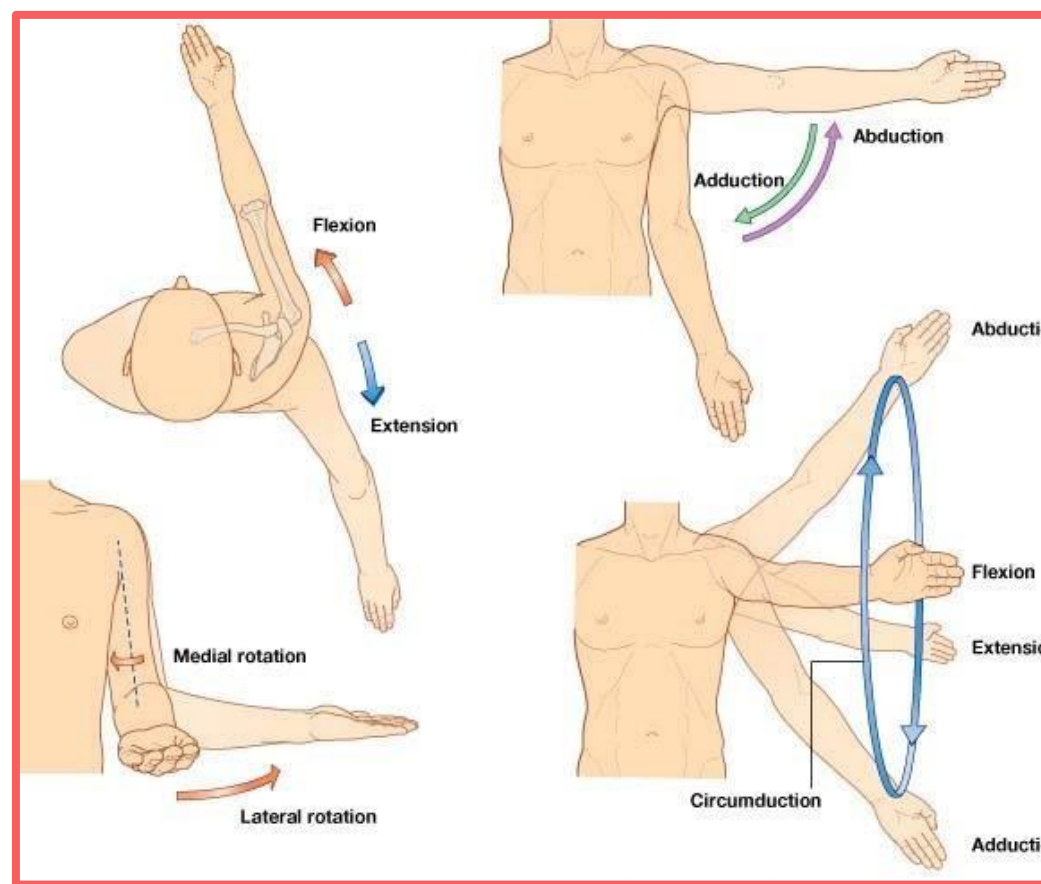
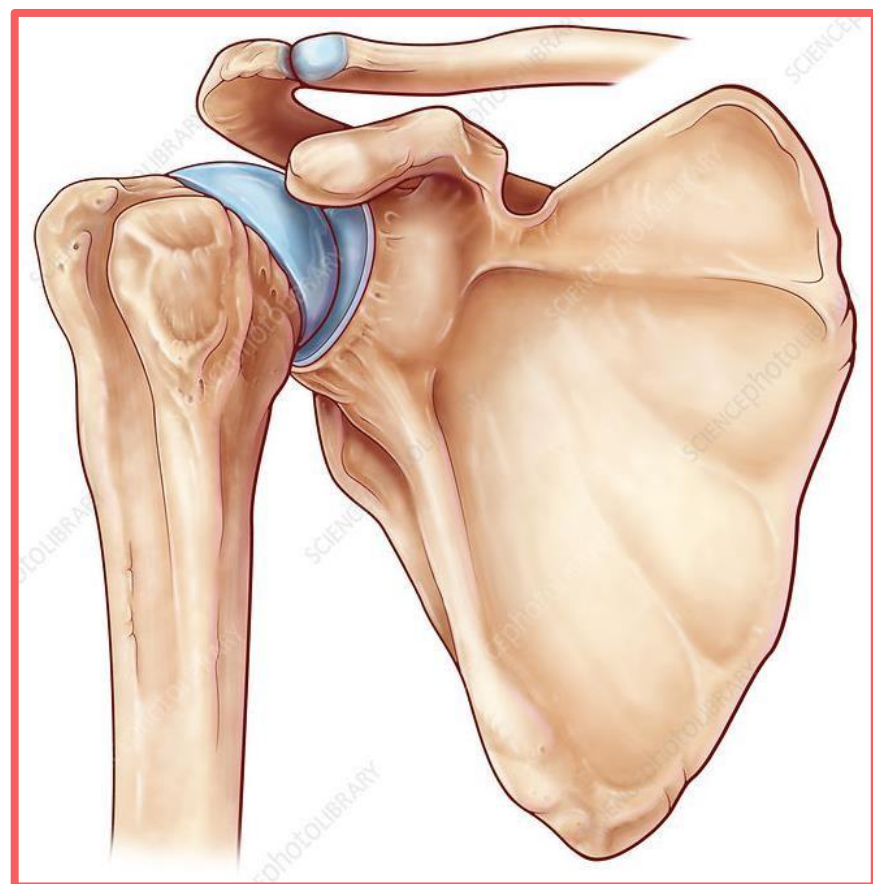
# Synovial Joints

## ➤ Examples of Major Synovial Joints

Ball: Head of the Humerus  
Socket: Glenoid cavity of the scapula

### Shoulder Joint

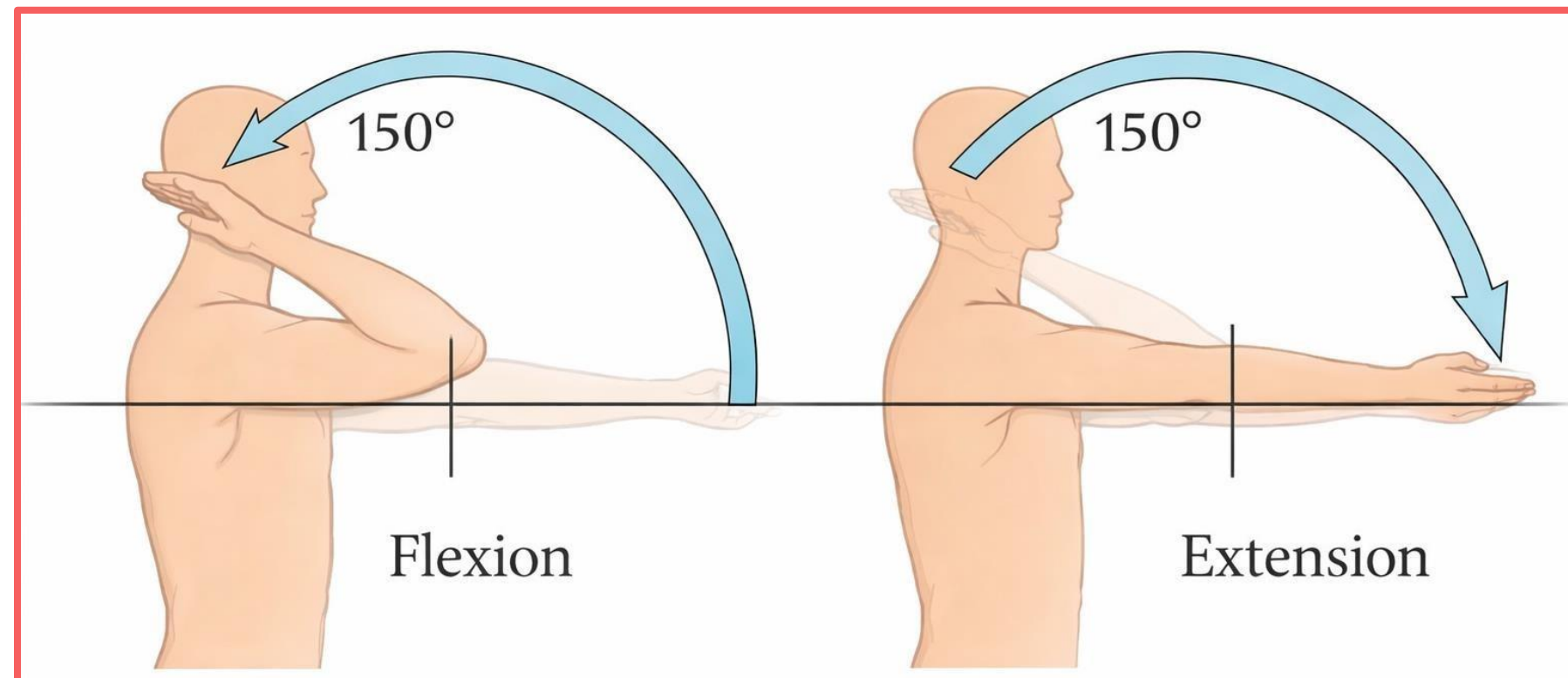
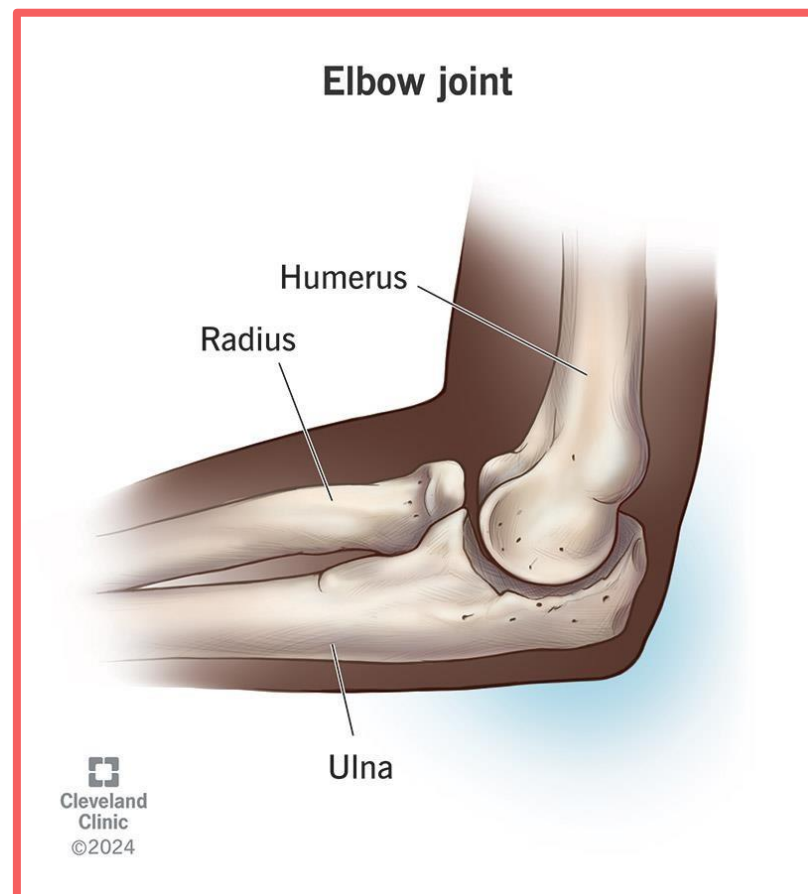
<b>Articulation</b>	• Formed by the head of the humerus and the glenoid cavity of the scapula.
<b>Type</b>	• A ball-and-socket joint.
<b>Movements</b>	• Flexion, extension, hyperextension, abduction, adduction, medial rotation, lateral rotation, and circumduction of the arm.



# Synovial Joints

## ➤ Examples of Major Synovial Joints

Elbow Joint	
<b>Articulation</b>	<ul style="list-style-type: none"> <li>Formed by the humerus, ulna, and radius. trochlea and capitulum of the humerus, the trochlear notch of the ulna, and the head of the radius</li> </ul>
<b>Type</b>	<ul style="list-style-type: none"> <li>A hinge joint.</li> </ul>
<b>Movements</b>	<ul style="list-style-type: none"> <li>Flexion and extension of the forearm.</li> </ul>

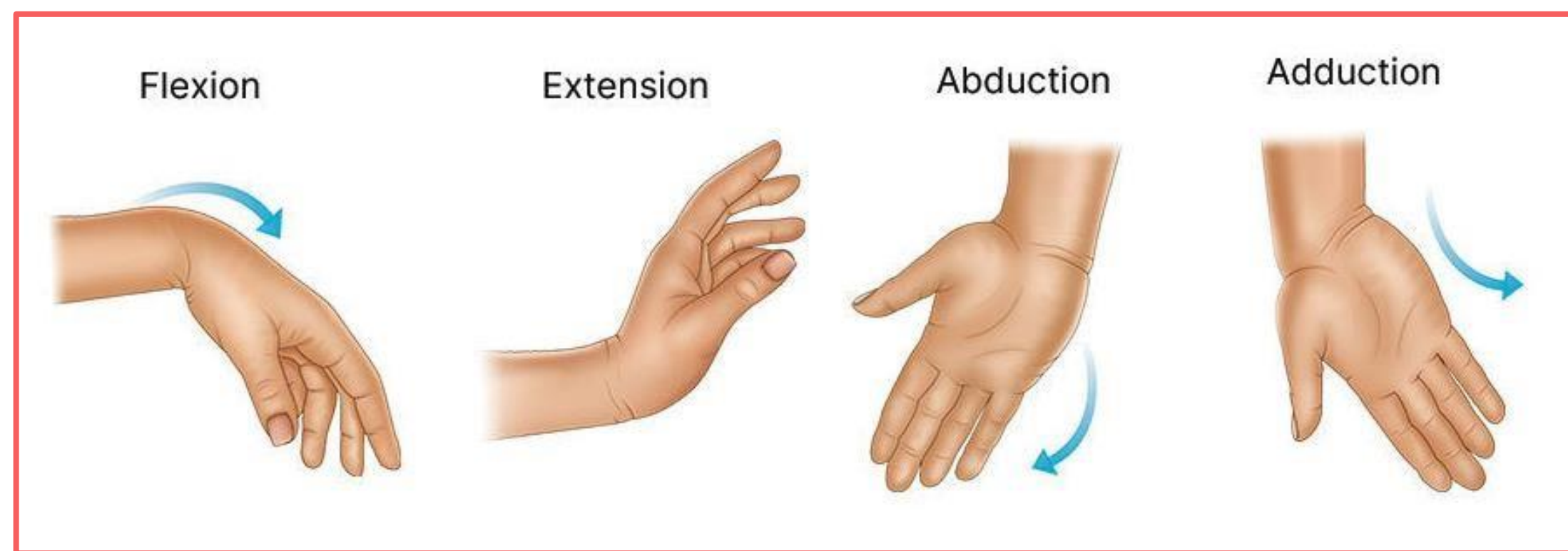
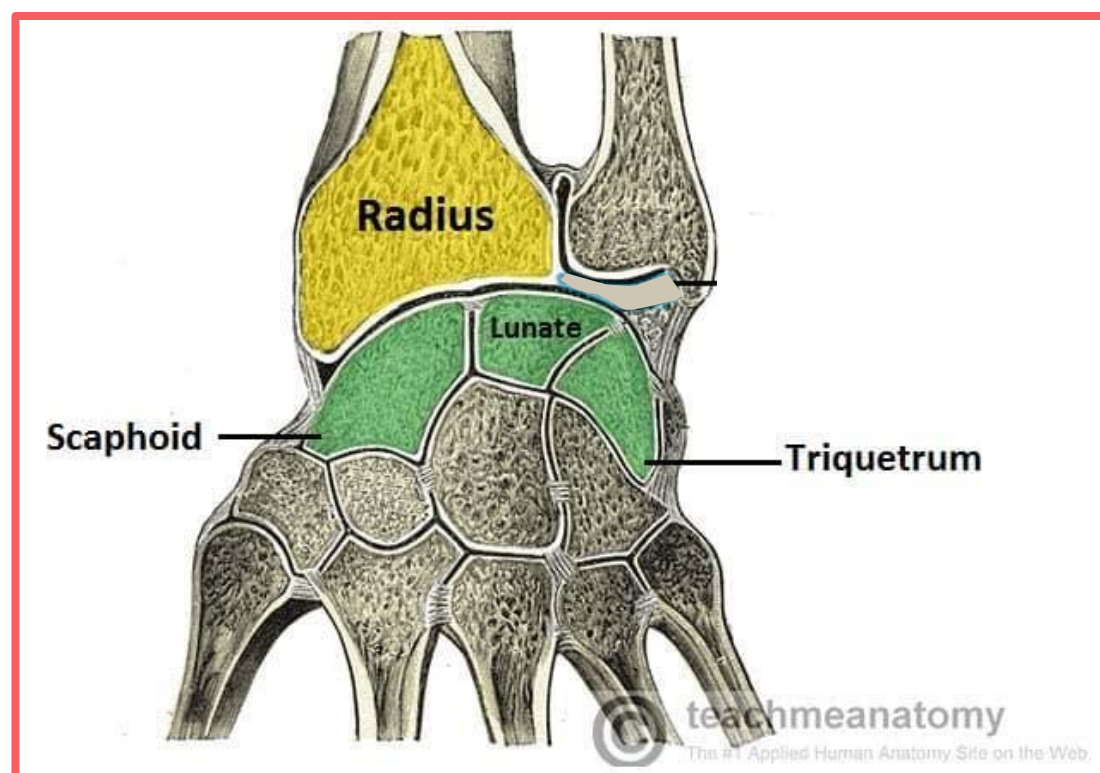


# Synovial Joints

## ➤ Examples of Major Synovial Joints

Wrist Joint	
<b>Articulation</b>	• Formed by distal end of the radius and carpal bones (scaphoid, lunate, and triquetrum)
<b>Type</b>	• Ellipsoid (Condyloid) joint
<b>Movements</b>	• Flexion, extension, abduction, and adduction of the hand

Reminder:  
The ulna is not a part of the wrist joint



# Synovial Joints

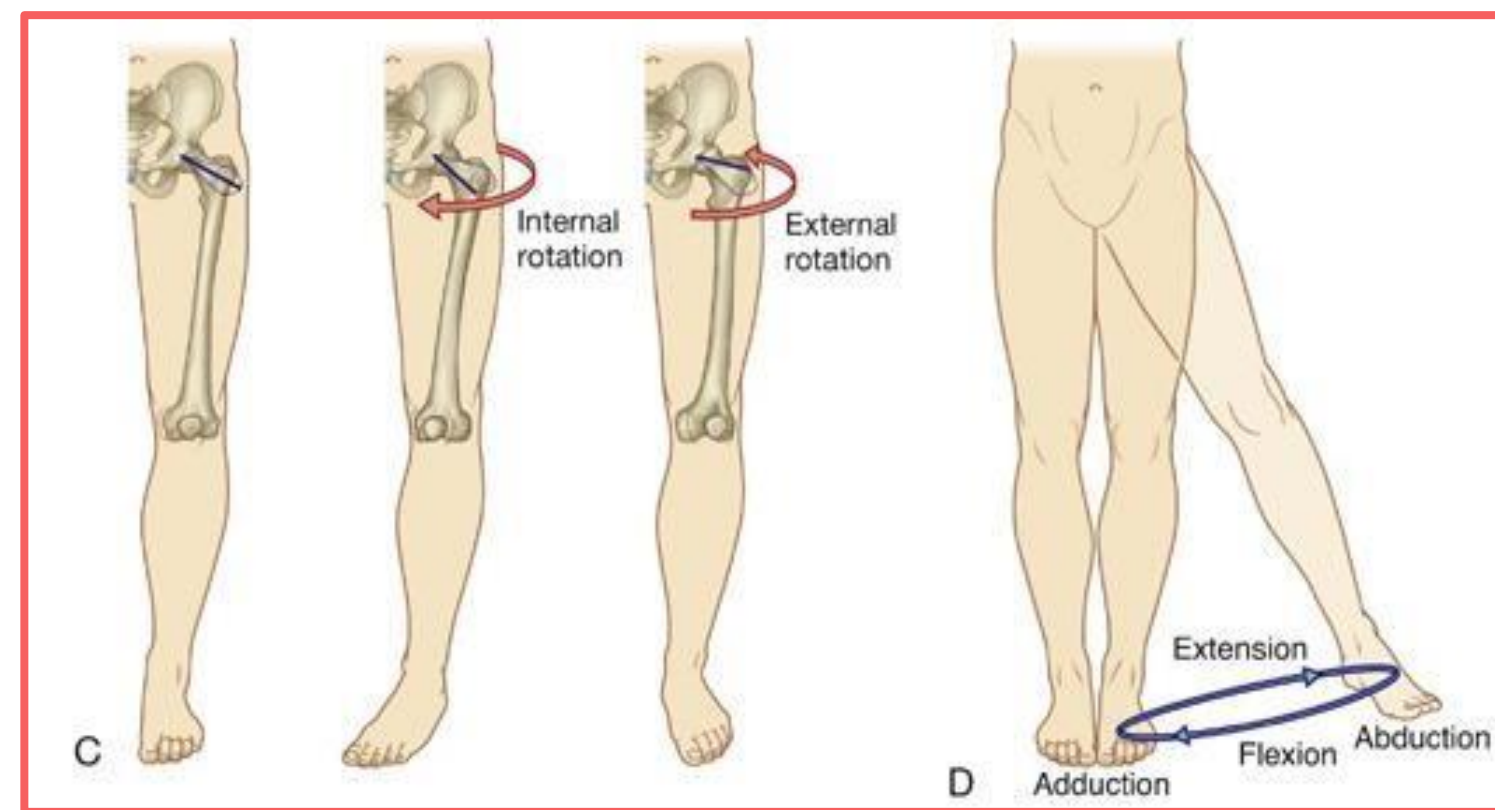
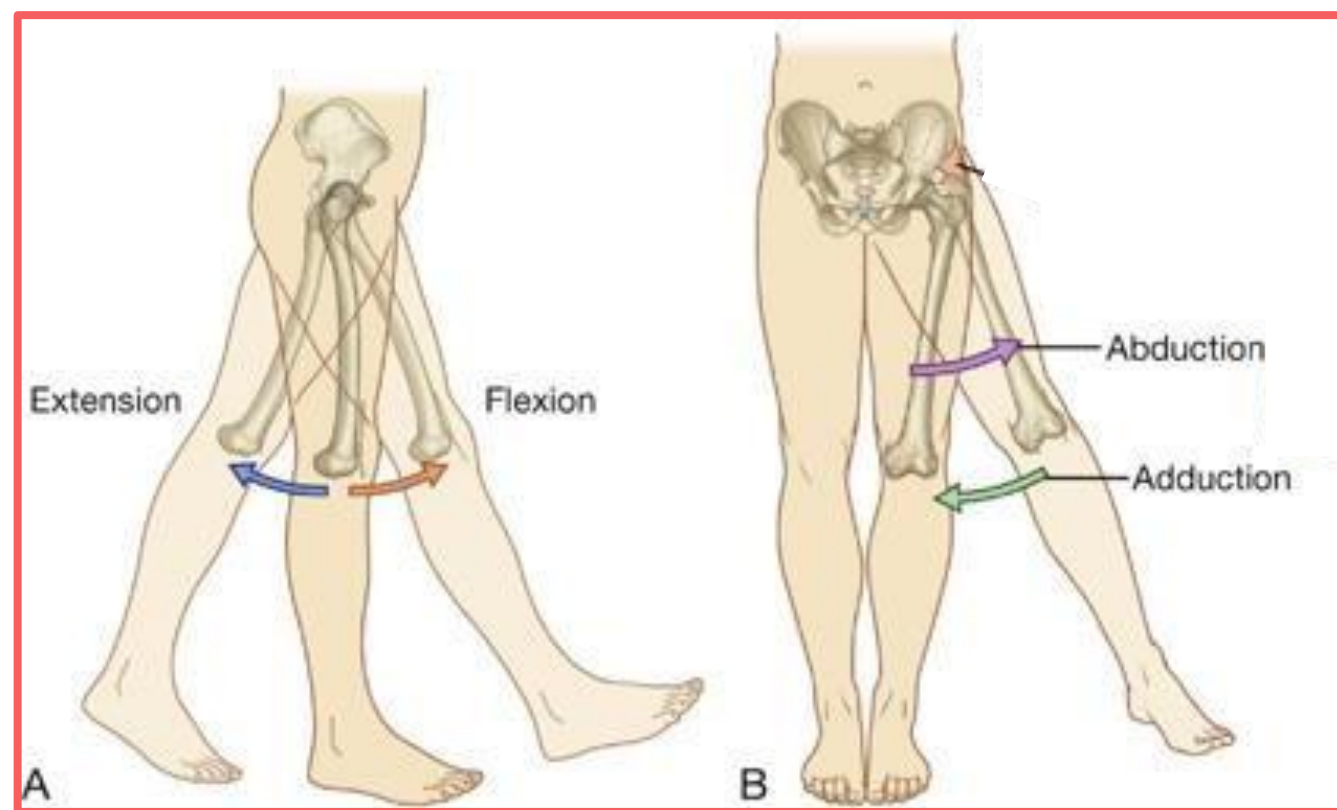
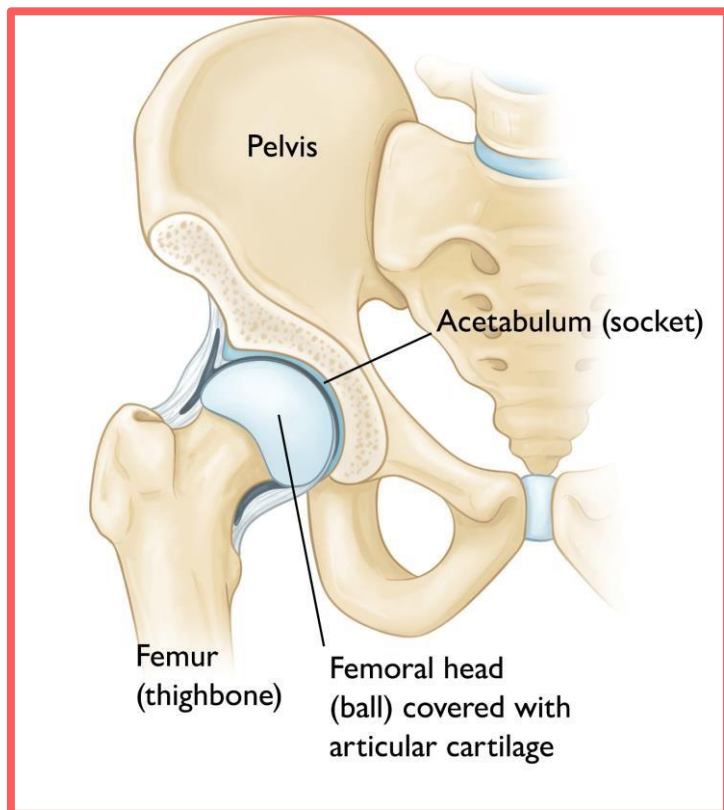
Similar to the shoulder joint

Ball: Head of the Femur

Socket: Acetabulum of the hip bone (on the lateral side)

## ➤ Examples of Major Synovial Joints

Hip Joint	
<b>Articulation</b>	<ul style="list-style-type: none"> <li>Formed by the head of the femur and the acetabulum of the hip bone.</li> </ul>
<b>Type</b>	<ul style="list-style-type: none"> <li>A ball-and-socket joint.</li> </ul>
<b>Movements</b>	<ul style="list-style-type: none"> <li>Flexion, extension, abduction, adduction, medial rotation, lateral rotation, and circumduction of the thigh.</li> </ul>

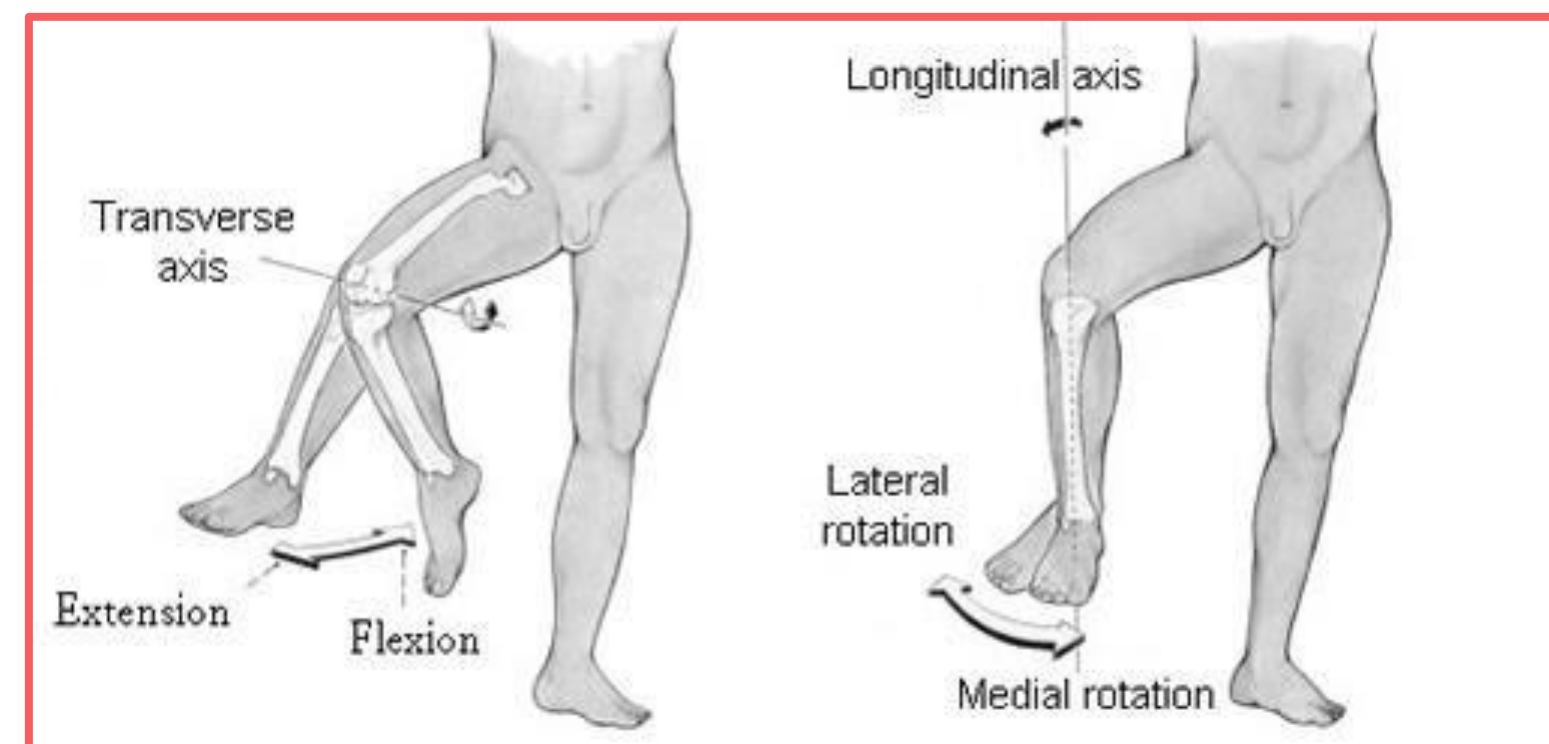
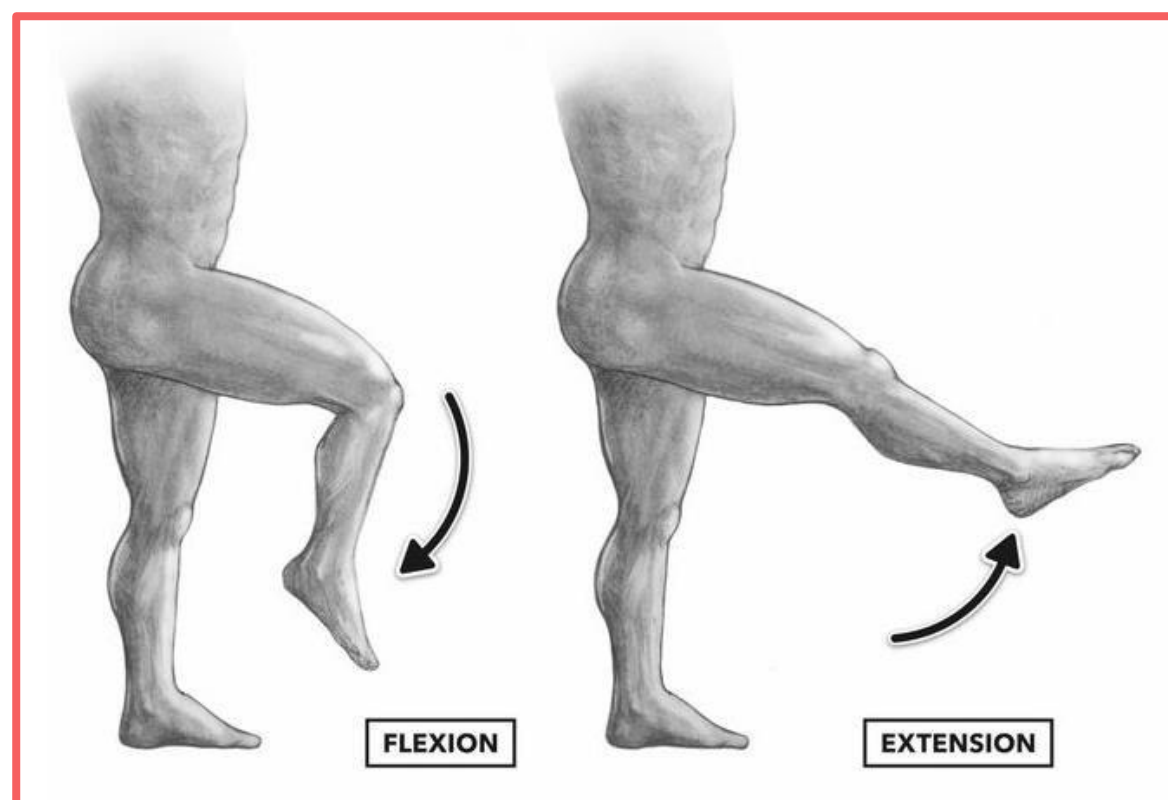
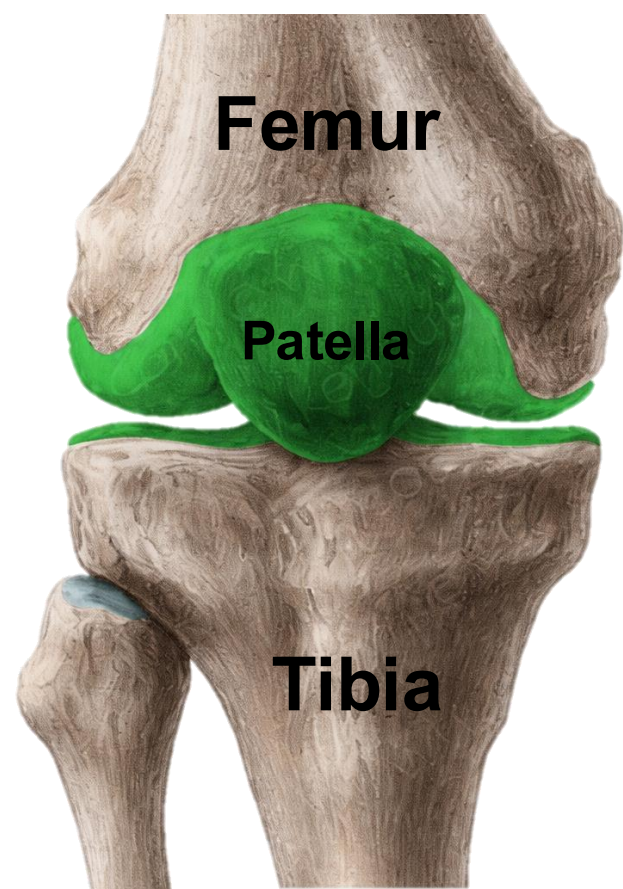


# Synovial Joints

Notice how it's a "modified" hinge joint. The hinge joint normally does flexion and extension only, however because this is a modified joint we have other movements such as a slight medial and lateral rotation of the leg (must be in a flexed position)

## ➤ Examples of Major Synovial Joints

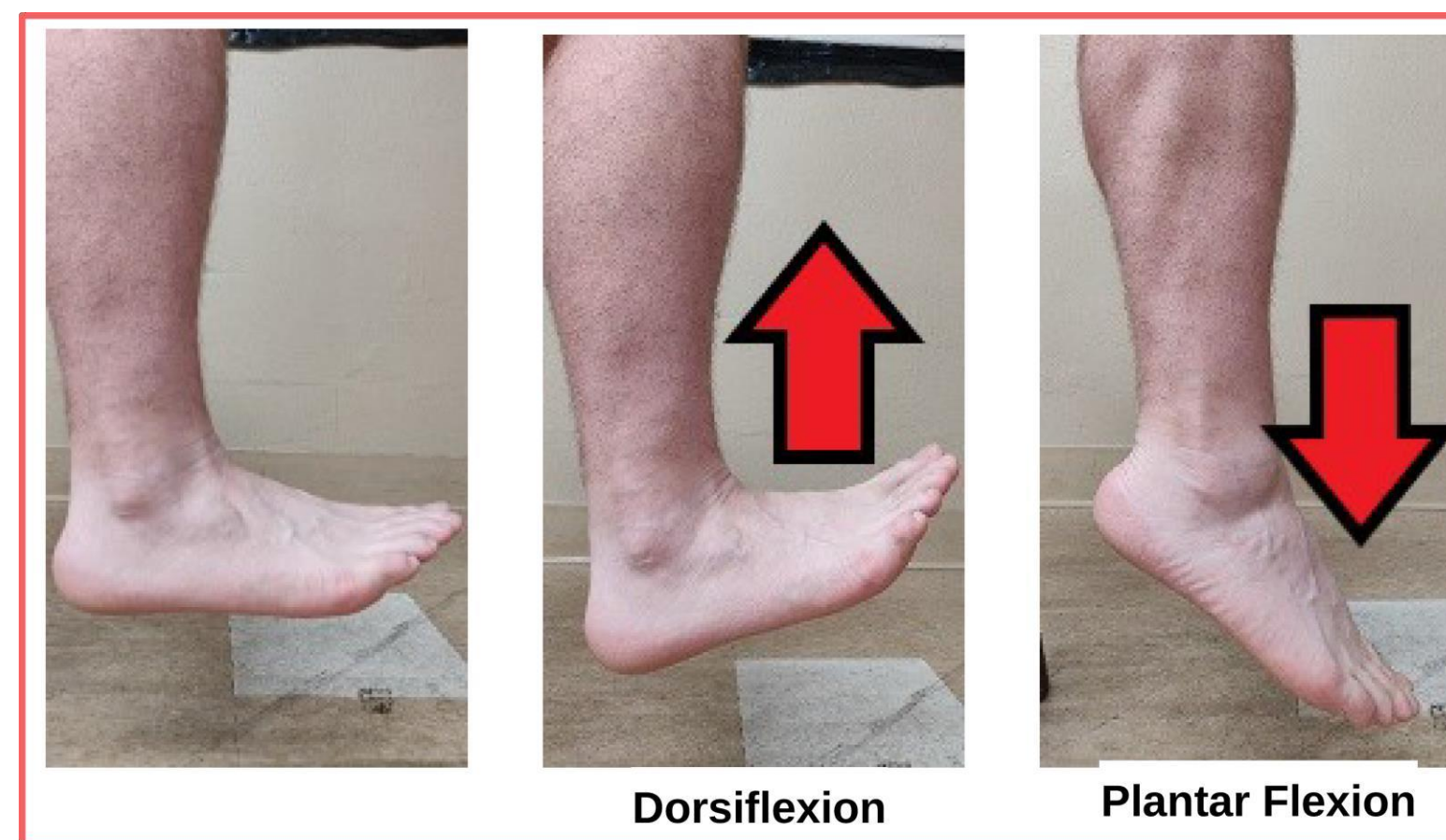
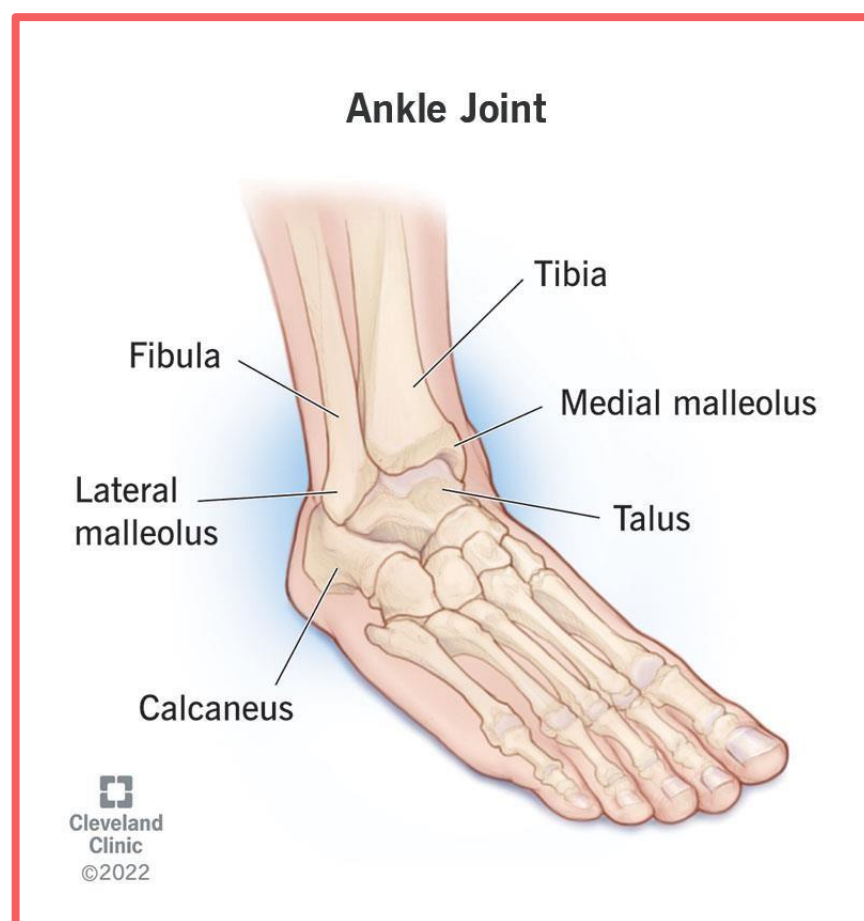
Knee Joint	
<b>Articulation</b>	<ul style="list-style-type: none"> <li>Formed by the distal end of the femur, the proximal end of the tibia, and Posterior surface of the Patella with the femur</li> </ul>
<b>Type</b>	<ul style="list-style-type: none"> <li>A modified hinge joint.</li> </ul>
<b>Movements</b>	<ul style="list-style-type: none"> <li>Flexion, extension, and slight medial and lateral rotation of the leg (in the flexed position).</li> </ul>



# Synovial Joints

## ➤ Examples of Major Synovial Joints

Ankle Joint	
<b>Articulation</b>	<ul style="list-style-type: none"> <li>Formed by the distal ends of the tibia and fibula with the talus bone of the foot.</li> </ul>
<b>Type</b>	<ul style="list-style-type: none"> <li>A hinge joint</li> </ul>
<b>Movements</b>	<ul style="list-style-type: none"> <li>Dorsiflexion (bending the foot upward)</li> <li>Plantar flexion (pointing the foot downward).</li> </ul>





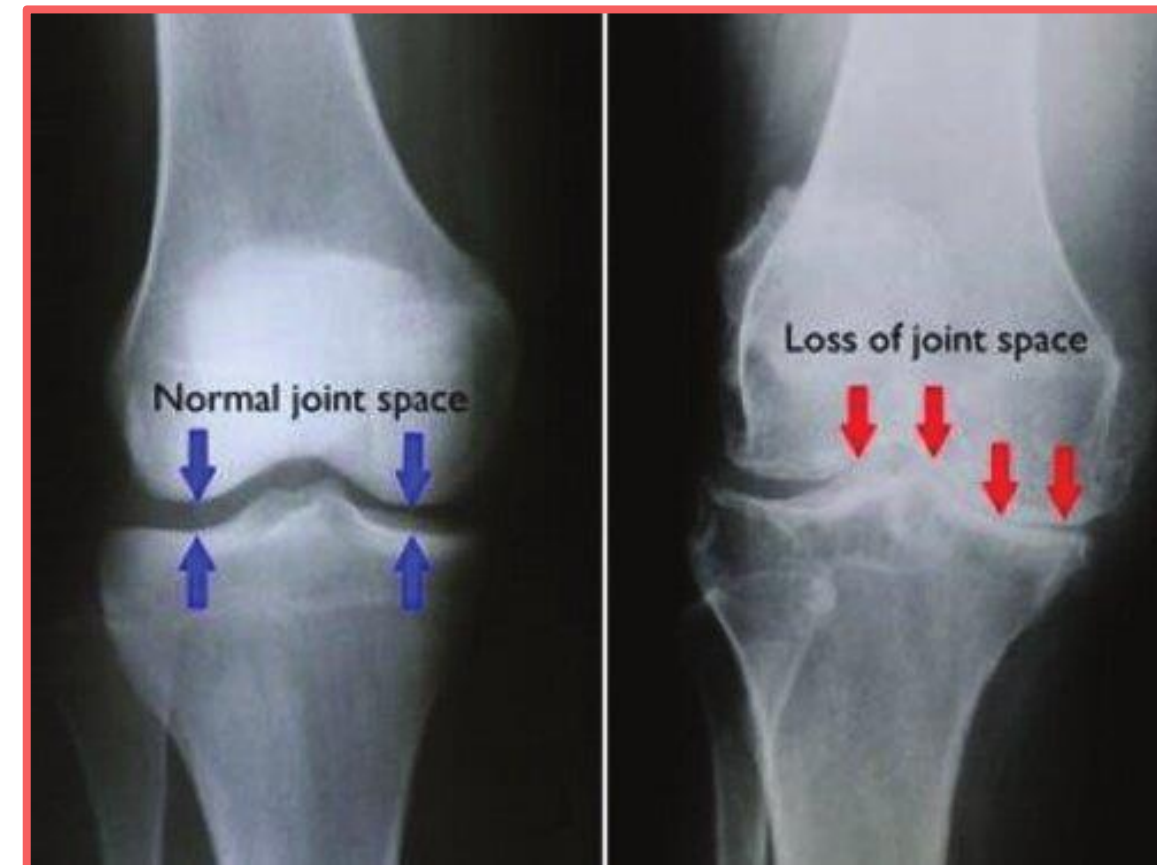
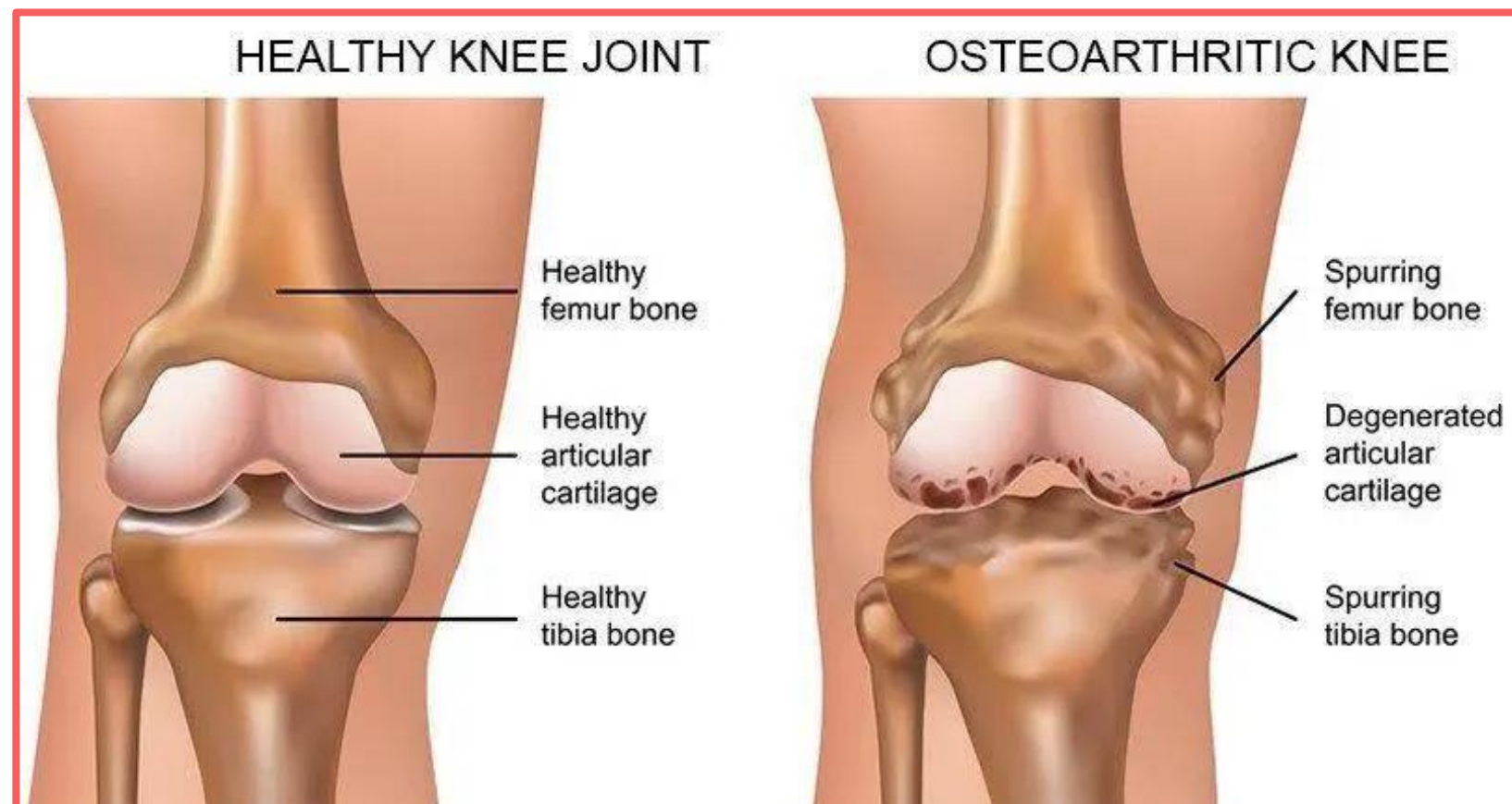
## Osteoarthritis

- A degenerative disorder of synovial joints in which the articular cartilage is damaged, allowing the articular surfaces of bones to come into contact.
- As the bones degenerate, abnormal bone repair occurs, resulting in irregular and misshapen articular surfaces, leading to pain and restricted movement.
- It most commonly affects large weight-bearing joints, such as the hip and knee joints.

Between two articulating bones there is a cartilage that degrades slowly due to age

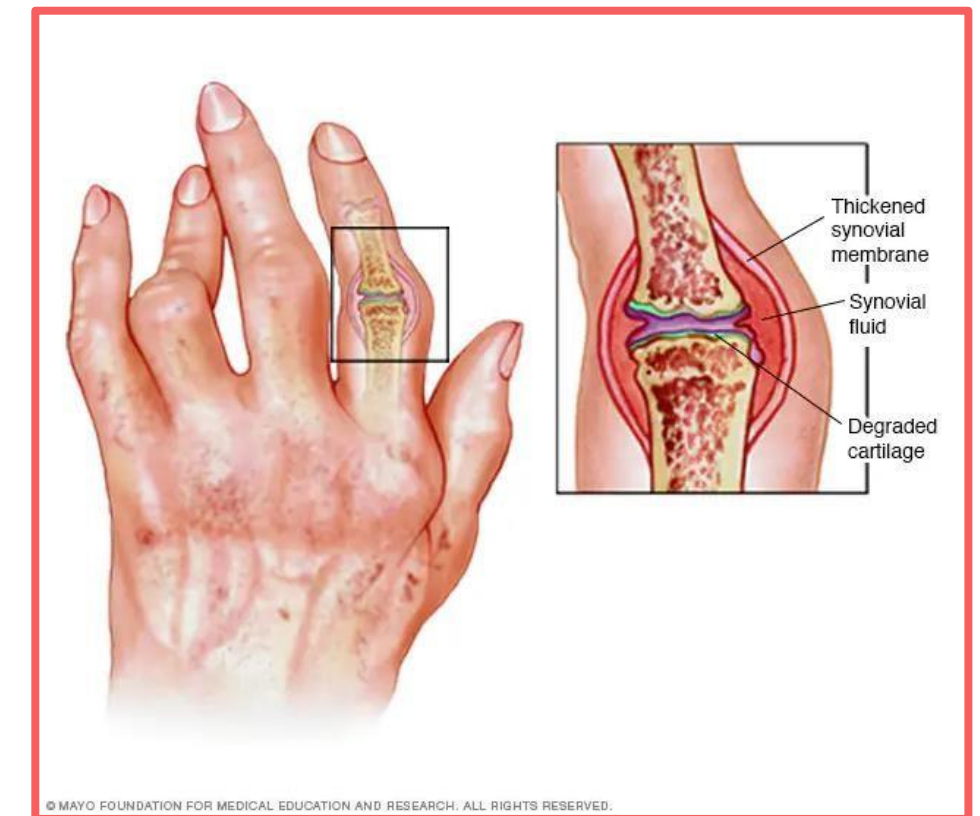
When the cartilage fully degenerates and due to adaptation reasons, the bones try to form irregular bones causing increase in pain and limited movement

To treat this condition we use injections to reduce friction between the bones so that the bones slide smoothly like a healthy bone

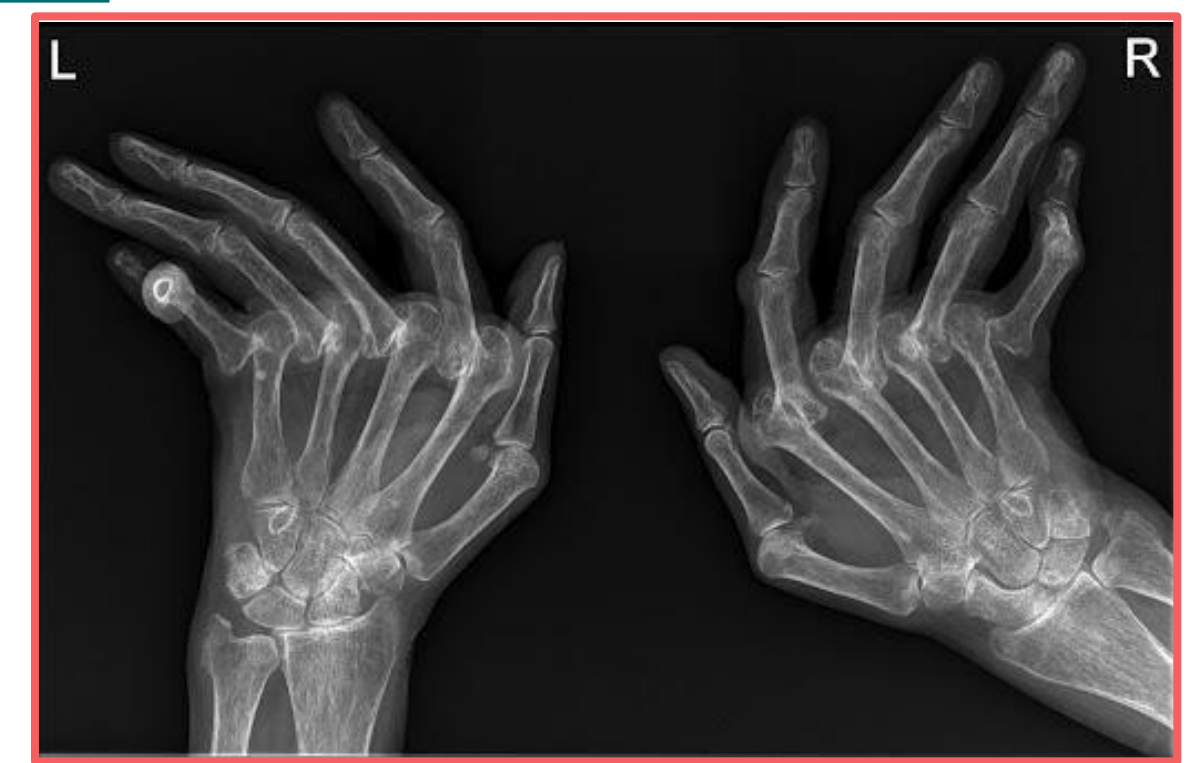
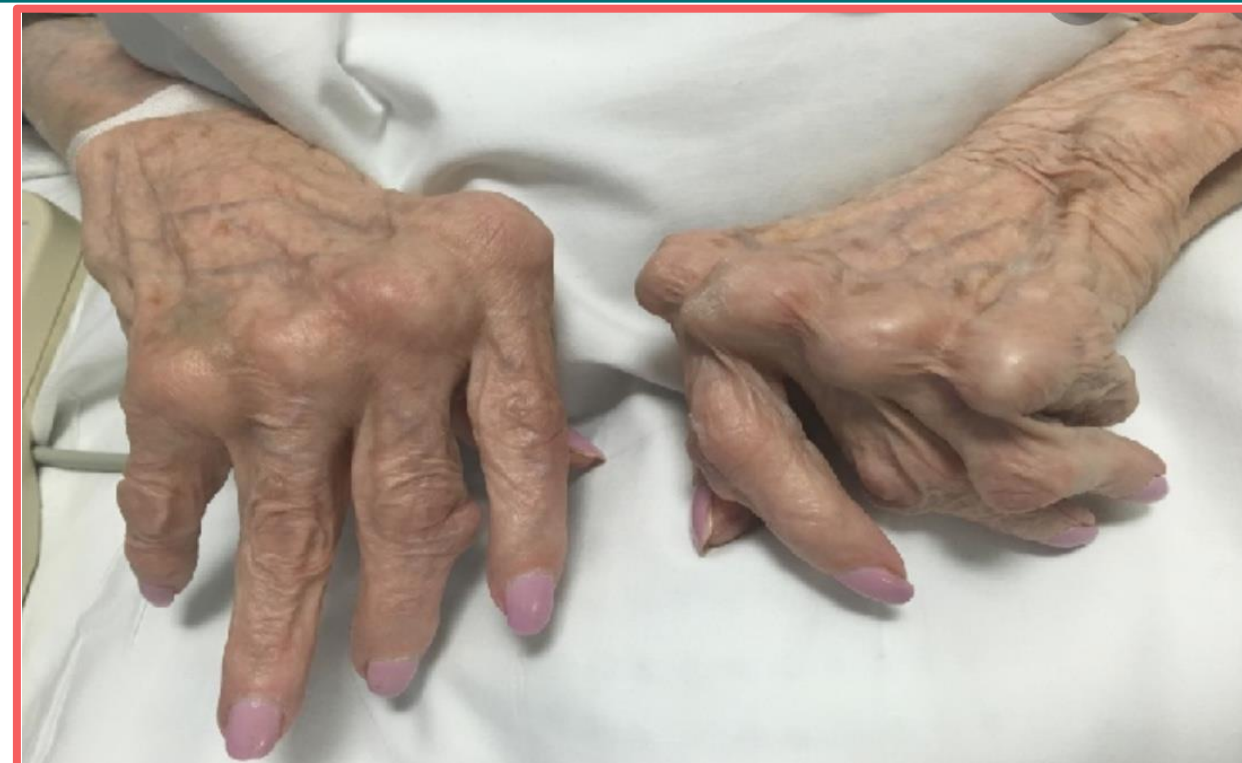
Clinical  
CorrelationRheumatoid Arthritis

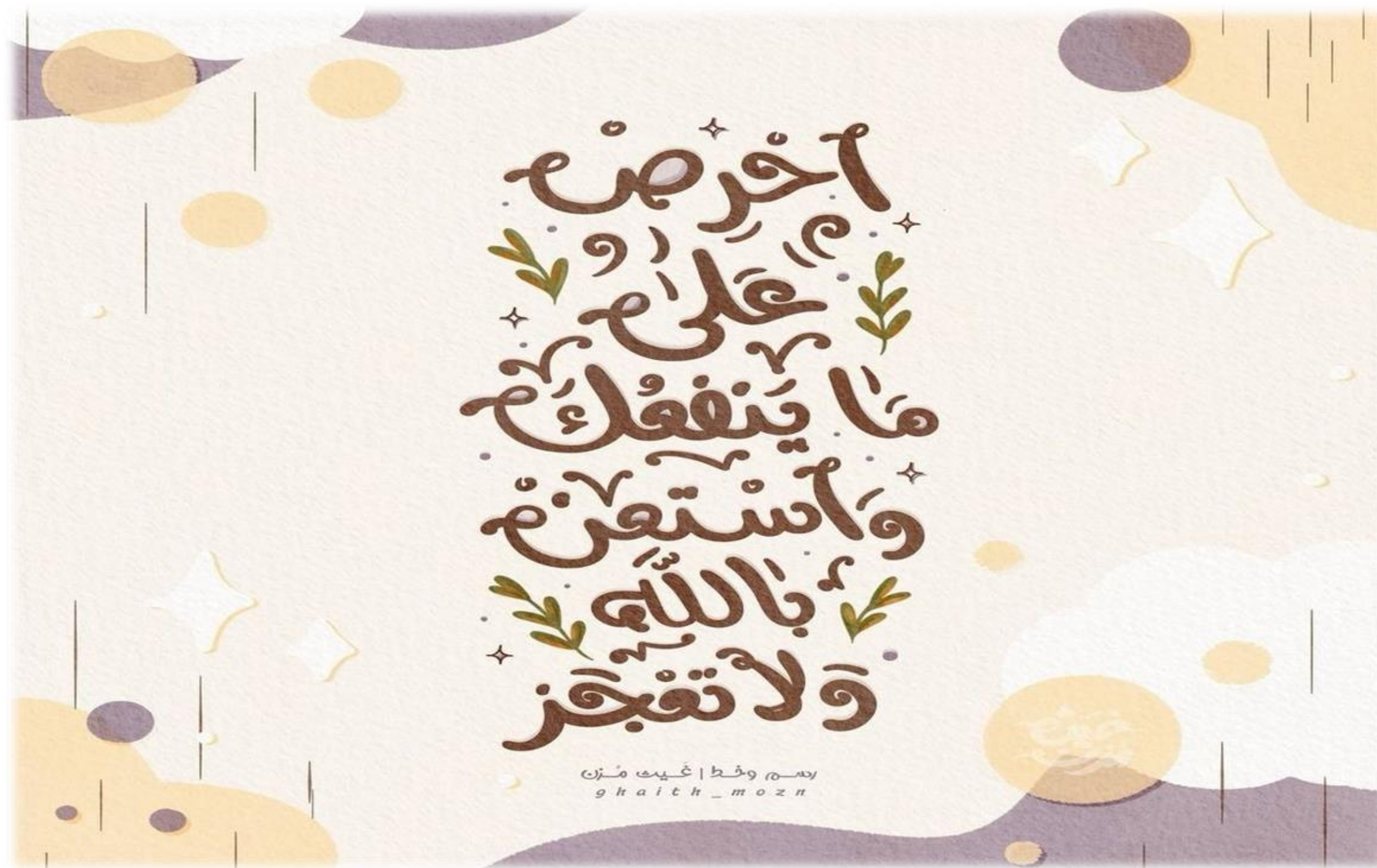- A chronic, progressive, inflammatory autoimmune disease that primarily involves the synovial membrane of joints.
- It is characterized by pain, swelling, stiffness, and loss of joint function.
- The inflammation leads to thickening of synovial membrane, damage of cartilage and bone, and joint deformity.
- It commonly affects small joints of hands and feet.



When the inflammation happens to the synovial membrane, the body starts secreting antibodies that cause a change in the shape of the synovial membrane which itself leads to a change in the joint's shape.



# رسالة من الفريق العلمي:



# For any feedback, scan the code or click on it.



Corrections from previous versions:

Versions	Slide # and Place of Error	Before Correction	After Correction
V0 → V1			
V1 → V2			