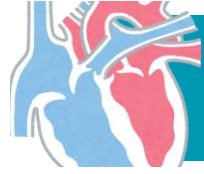


بِسْمِ اللَّهِ الرَّحْمَنِ الرَّحِيمِ



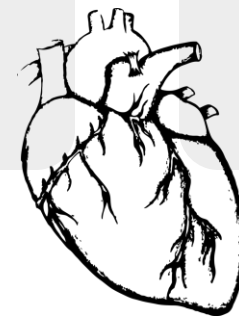ANATOMY

MID | Lecture 3

وَلَقَدْ خَلَقْنَا الْإِنْسَانَ وَنَعَلَهُمَّا تَوْسُوسٌ بِهِ نَفْسُهُ وَنَحْنُ أَقْرَبُ إِلَيْهِ مِنْ حَبْلِ الْوَرِيدِ

# Skeletal System 2

**Written by :** Yaman Khalil  
Yamen Aljarrah



**Reviewed by :** Joud Alsafadi

# Introduction to Anatomy

1<sup>st</sup> Year Medical Students

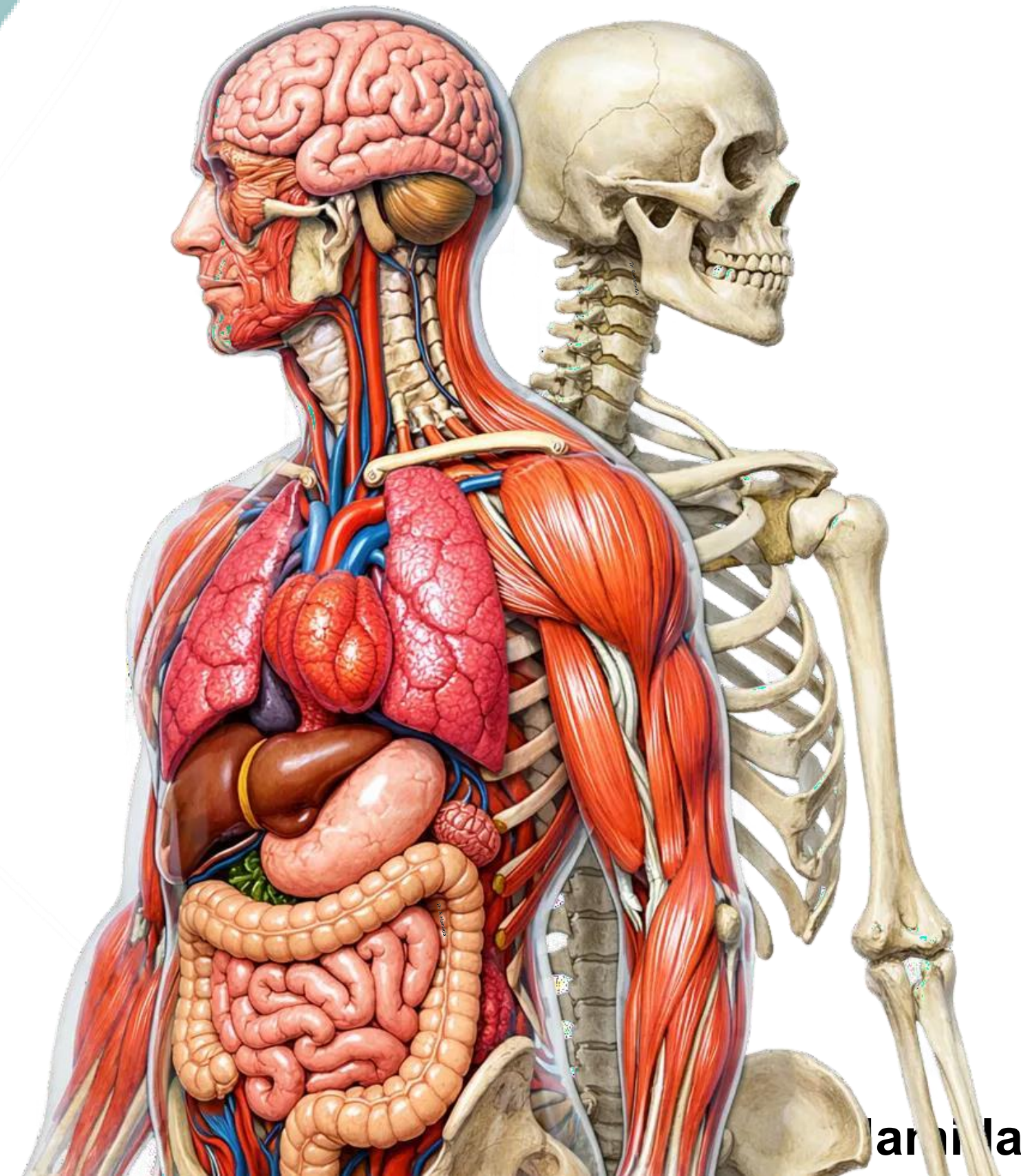
2025-2026  
Second Semester

Dr. Abedallah Hamida, MBBS, PhD

Department of Anatomy and Histology

School of Medicine-The University of Jordan

[a\\_hamida@ju.edu.jo](mailto:a_hamida@ju.edu.jo)



Hamida

# Course Outline:

1 Introduction and Terminology

2 Skeletal System

3 Cardiovascular System

4 Lymphatic System

5 Nervous System

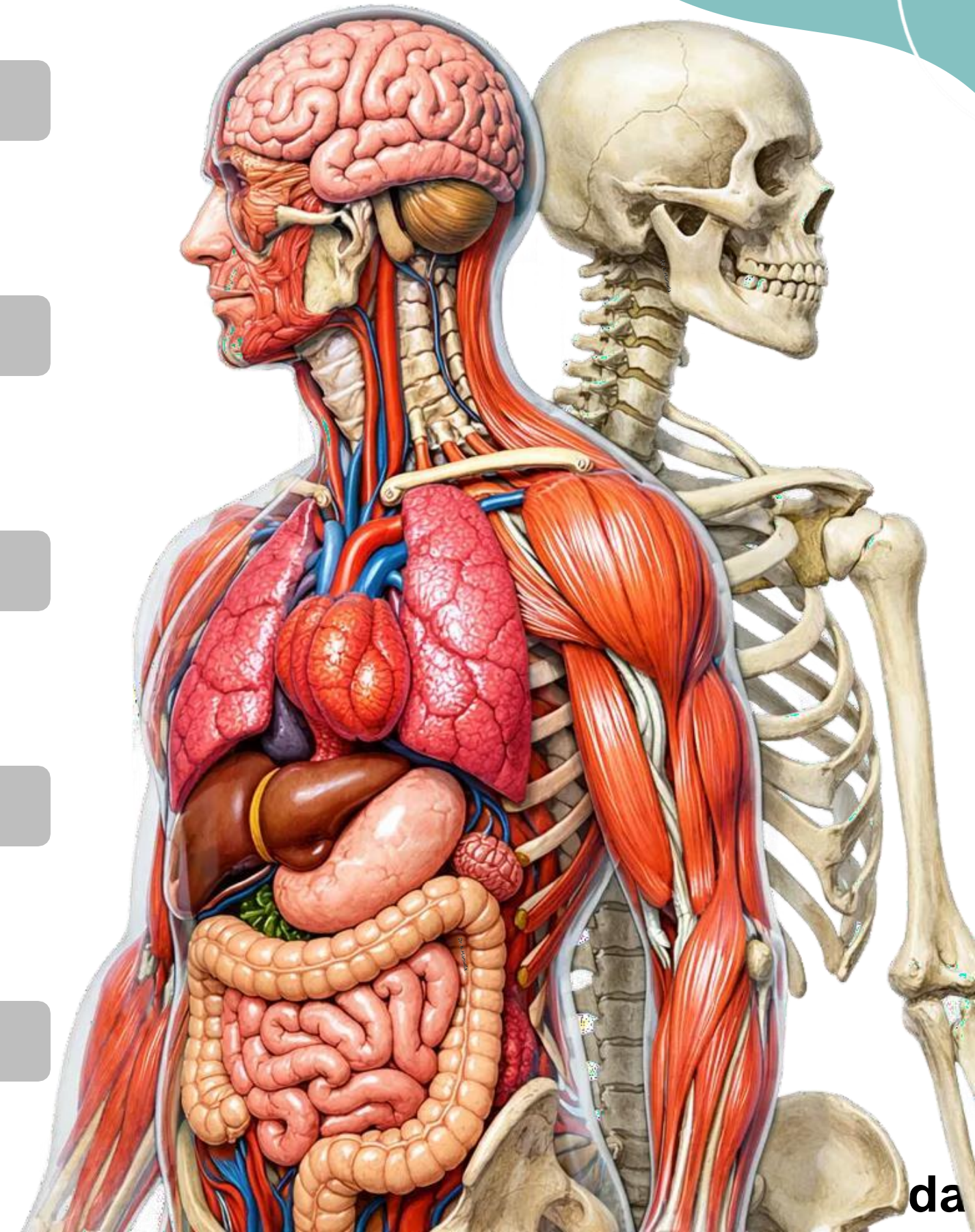
6 Muscular System

7 Respiratory System

8 Digestive System

9 Urinary System

10 Endocrine System



# 2 Skeletal System

## System Outline:

2.1

Axial Skeleton

2.2

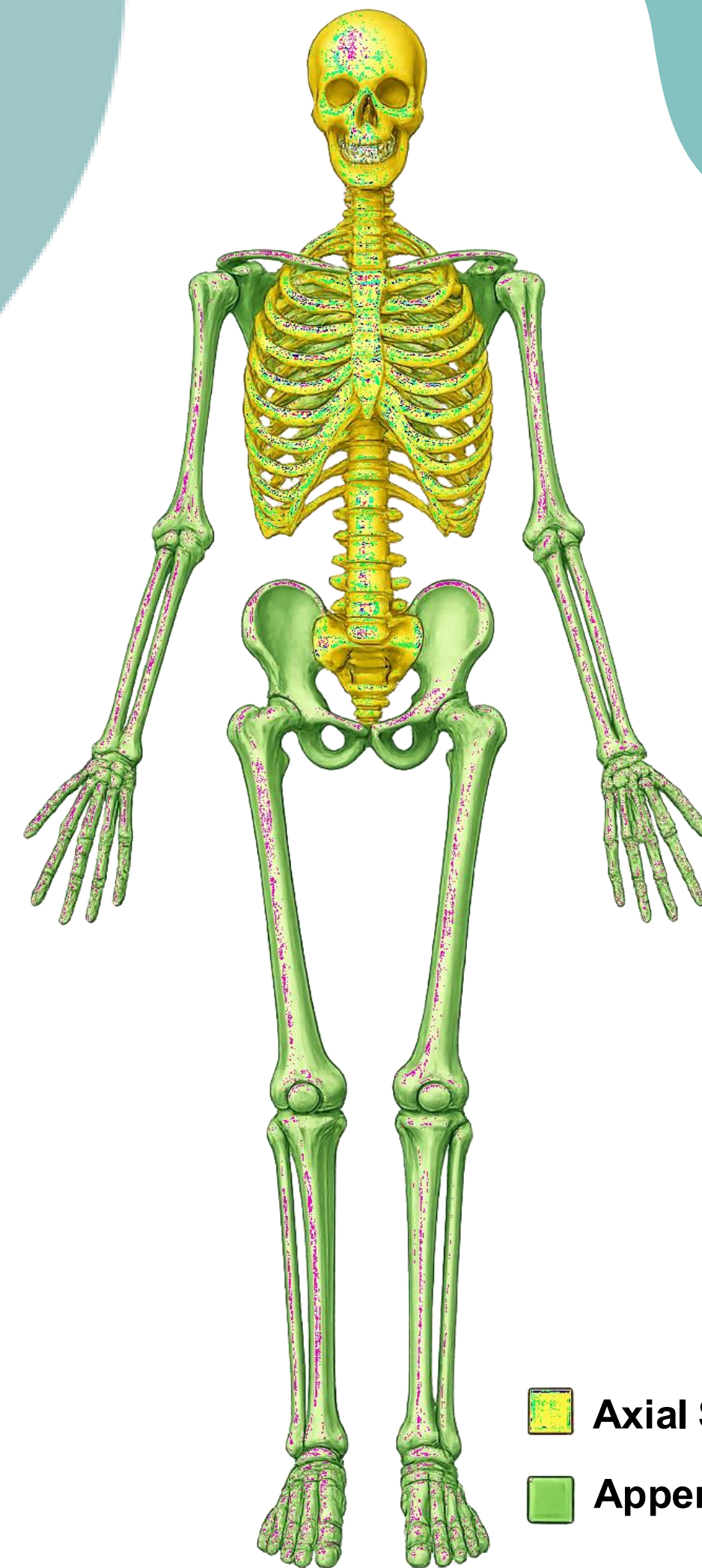
Appendicular Skeleton



2.3

Joints

# Skeletal system

## 1. Axial Skeleton-2



-  Axial Skeleton
-  Appendicular Skeleton

# 2

## Skeletal System

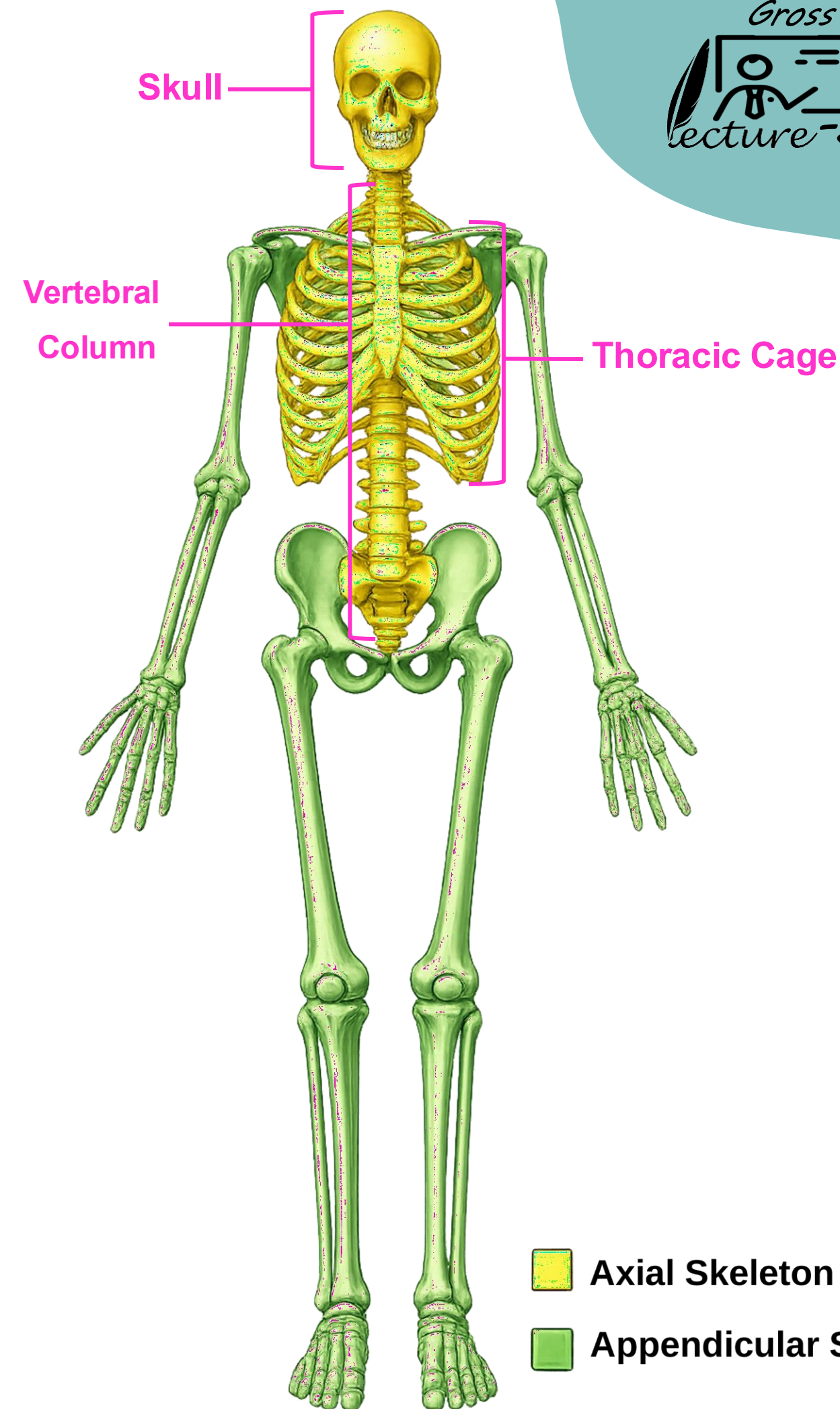
- The human skeletal system consists of **206 bones**
- The skeletal system is classified functionally into:

### 1. Axial Skeleton :

- Consists of the bones and cartilages that lie close to the
- central axis of the body.
- It includes the bones of the
  1. Skull
  2. Vertebral Column
  3. Thoracic Cage

### 2. Appendicular Skeleton :

- It is bilaterally symmetrical and consist of the bones and cartilages of the:
  1. Upper Limb
  2. Lower Limb



# 2.1 Skeletal System–Axial Skeleton

## Lecture Outline:

2.1.1

Skull

2.1.2

Vertebral Column

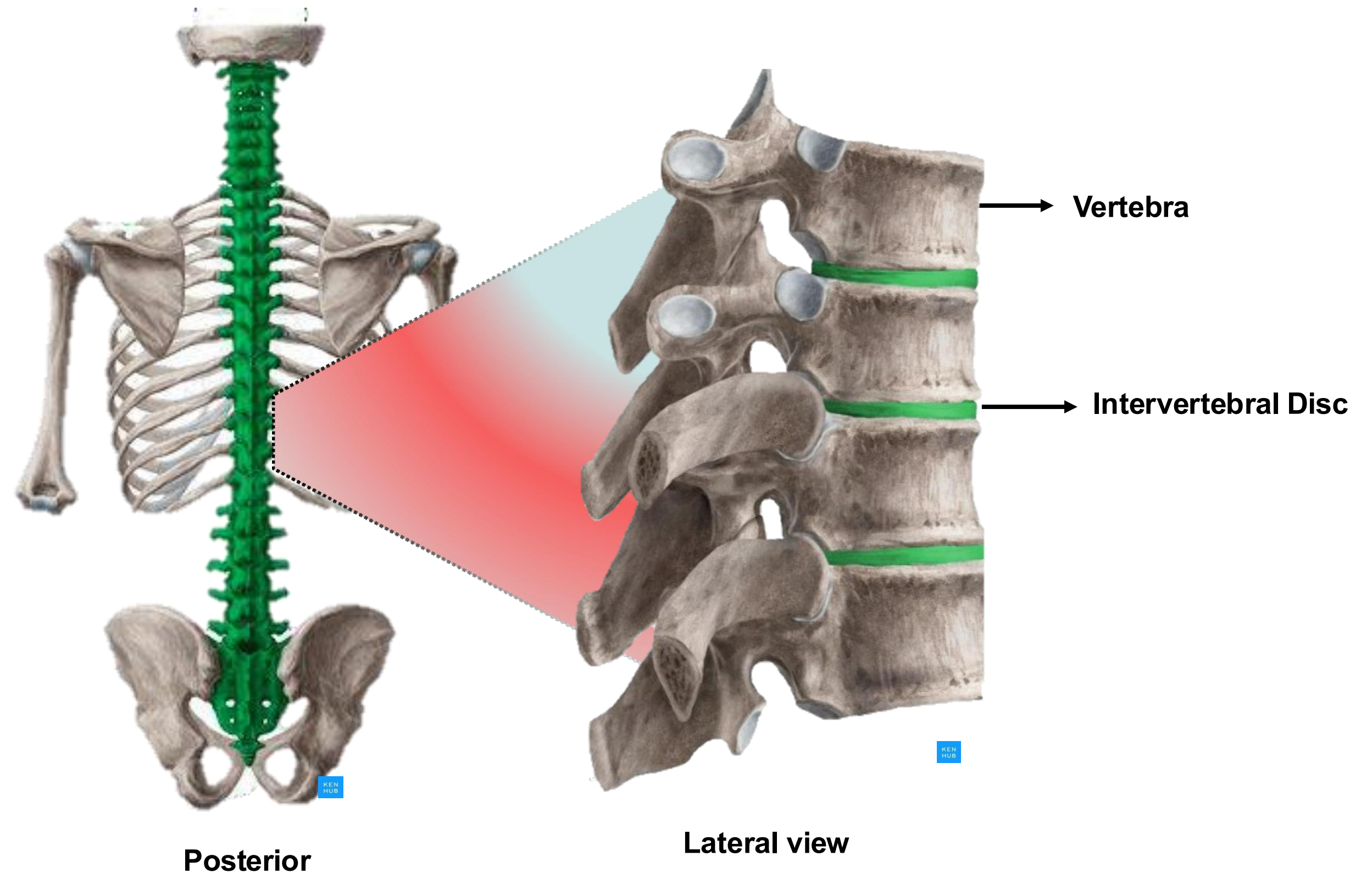
2.1.3

Thoracic Cage

# Vertebral Column

➤ The Vertebral Column consist of:

1. Vertebrae
2. Intervertebral Discs



2.1.2 **Vertebral Column** 1. Vertebrae

➤ The vertebral column consists of 33 vertebrae:

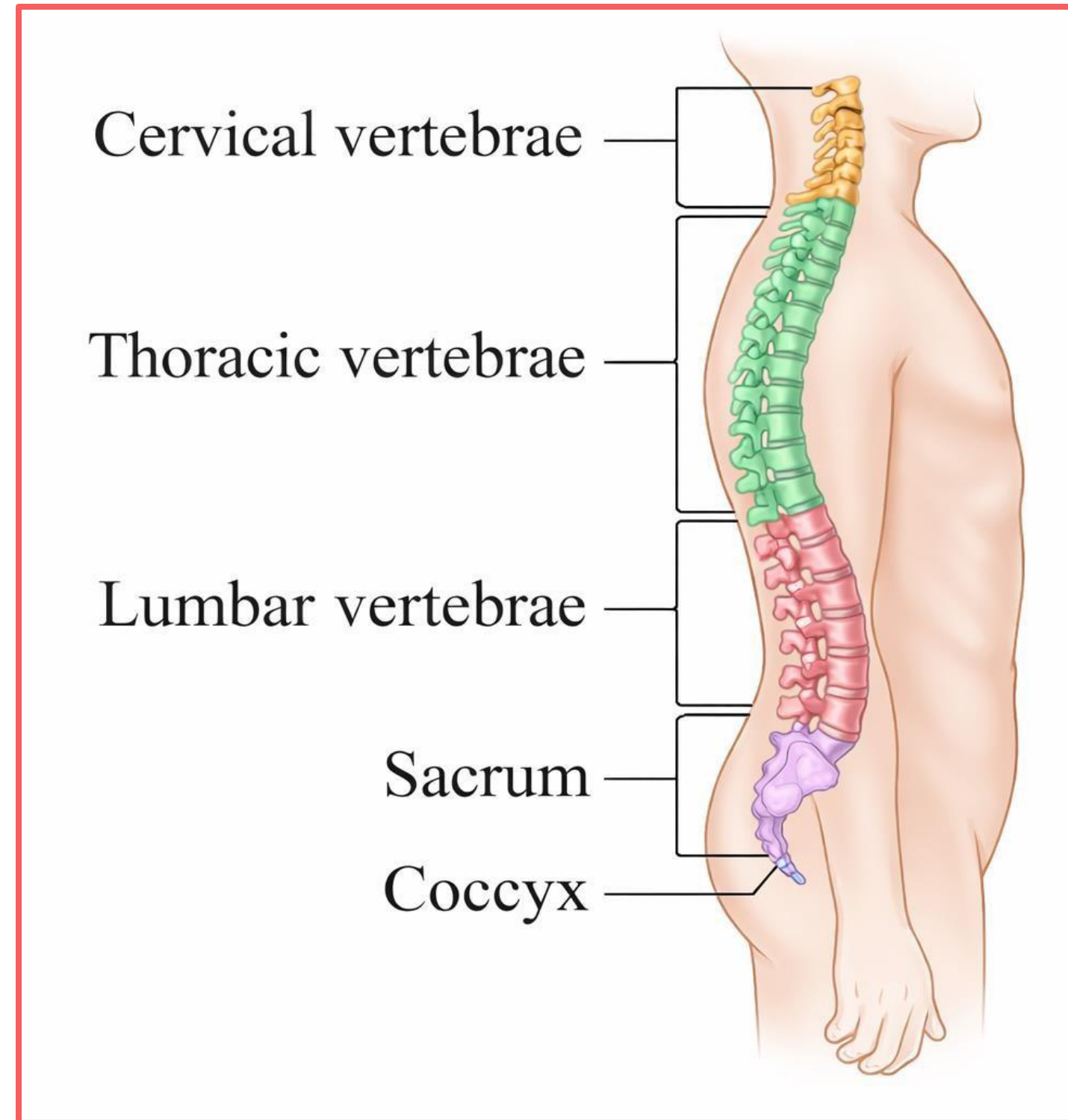
**7 Cervical Vertebrae**

**12 Thoracic Vertebrae**

**5 Lumbar Vertebrae**

**5 Sacral Vertebrae (fused)**

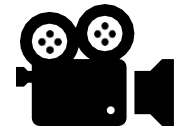
**4 Coccygeal Vertebrae (fused)**



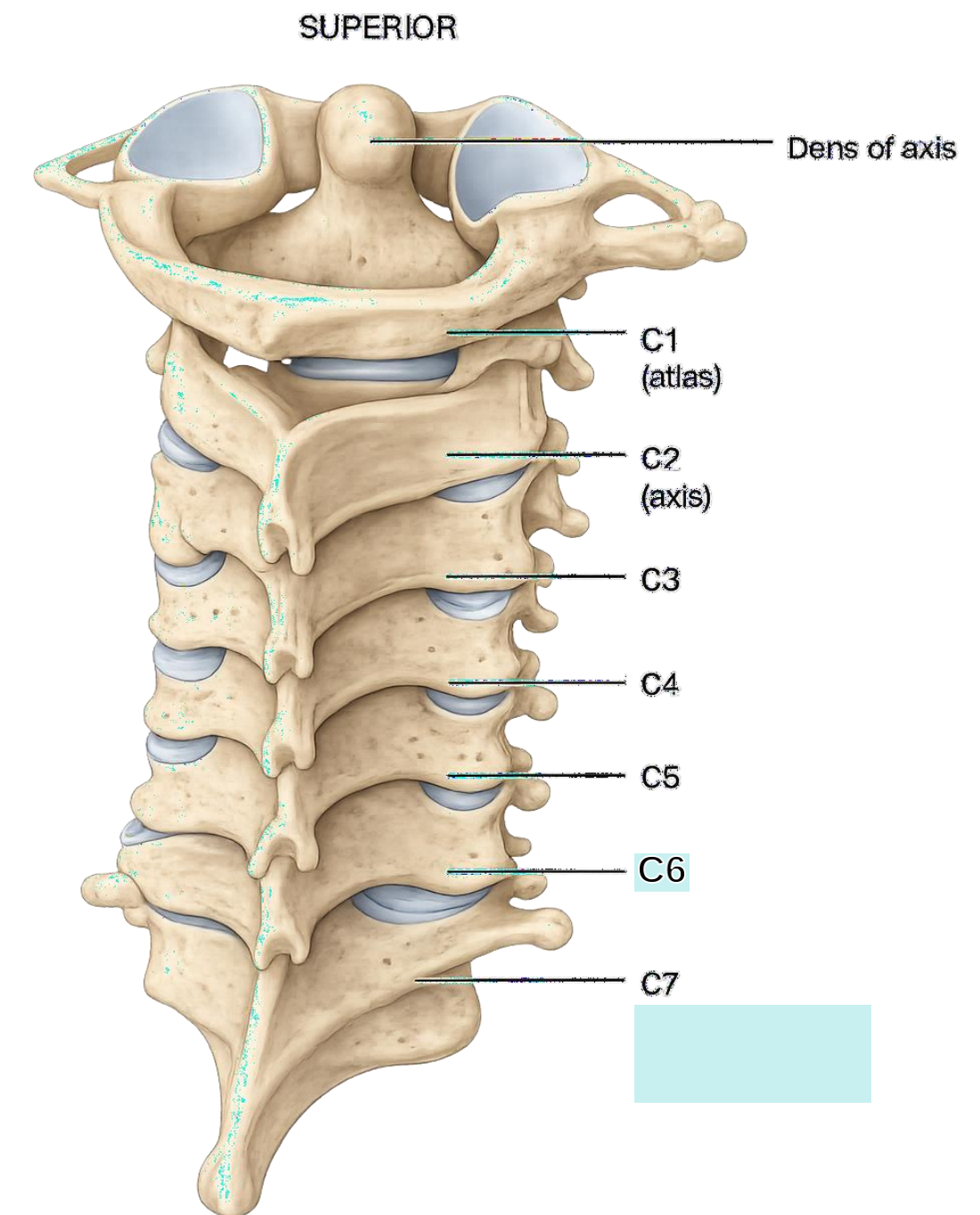
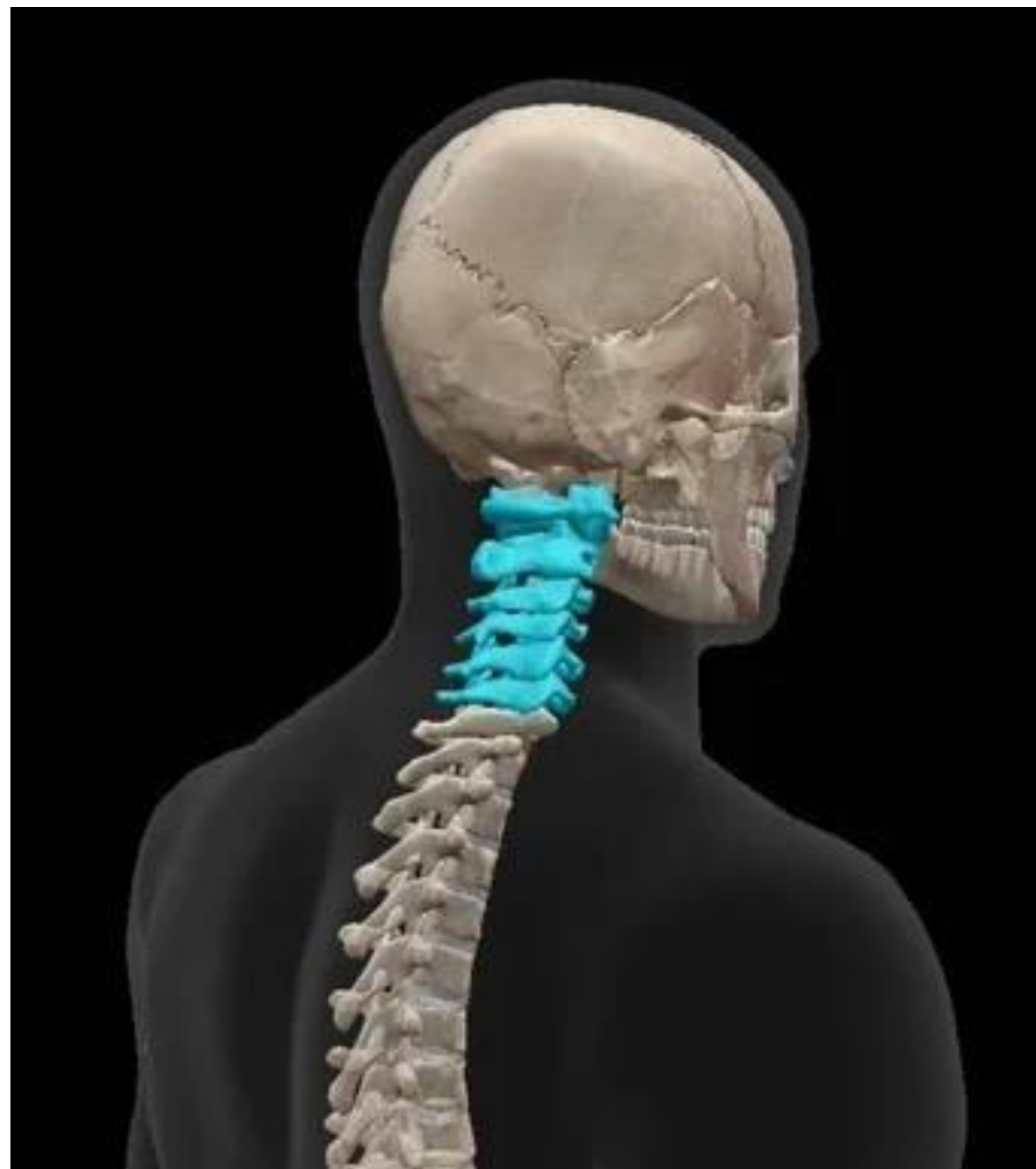
# Vertebral Column

## 1. Vertebrae

### 1. Cervical Vertebrae (7)



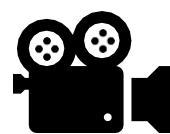
- Found in the neck region.
- Have intervertebral discs between every two vertebrae.
- The 1<sup>st</sup> cervical vertebra (atlas) articulates with the base of skull.



# Vertebral Column

## 1. Vertebrae

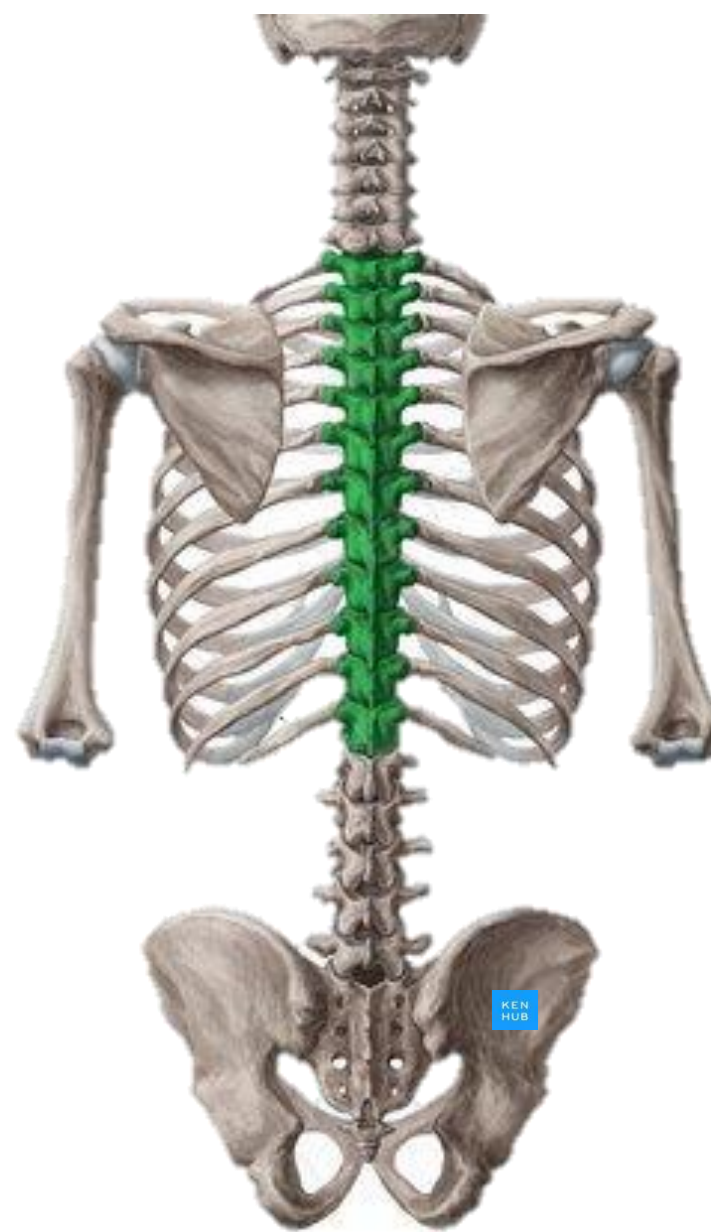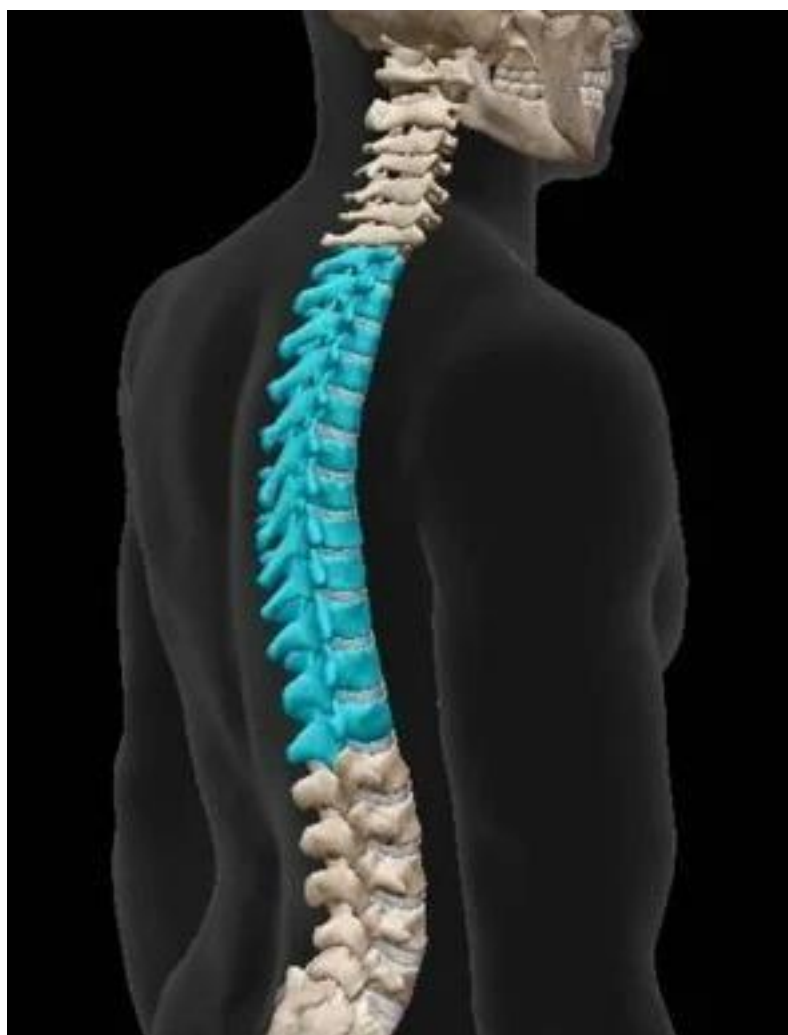### 2. Thoracic Vertebrae (12)



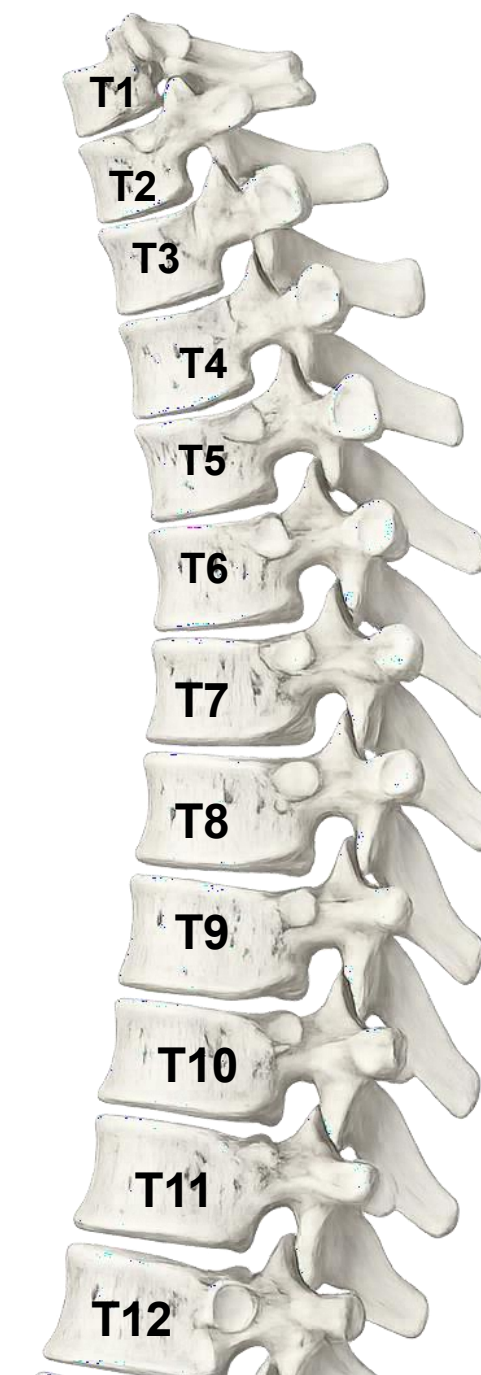
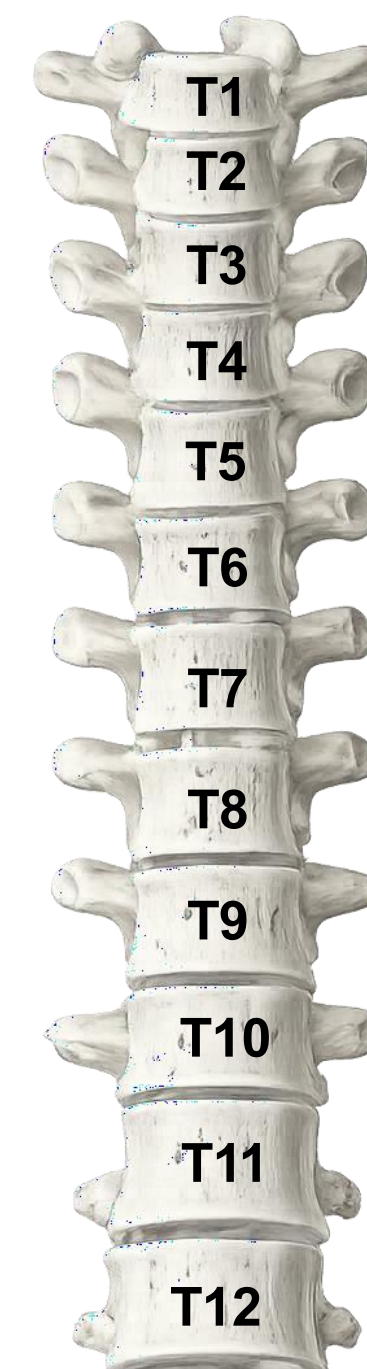- Found in the thoracic region (posterior to the thoracic cavity).
- Have intervertebral discs between every two vertebrae.
- Articulates with the ribs.

Each thoracic vertebra articulates with a pair of ribs (right and left)

a



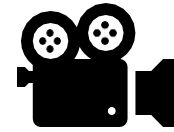
Posterior



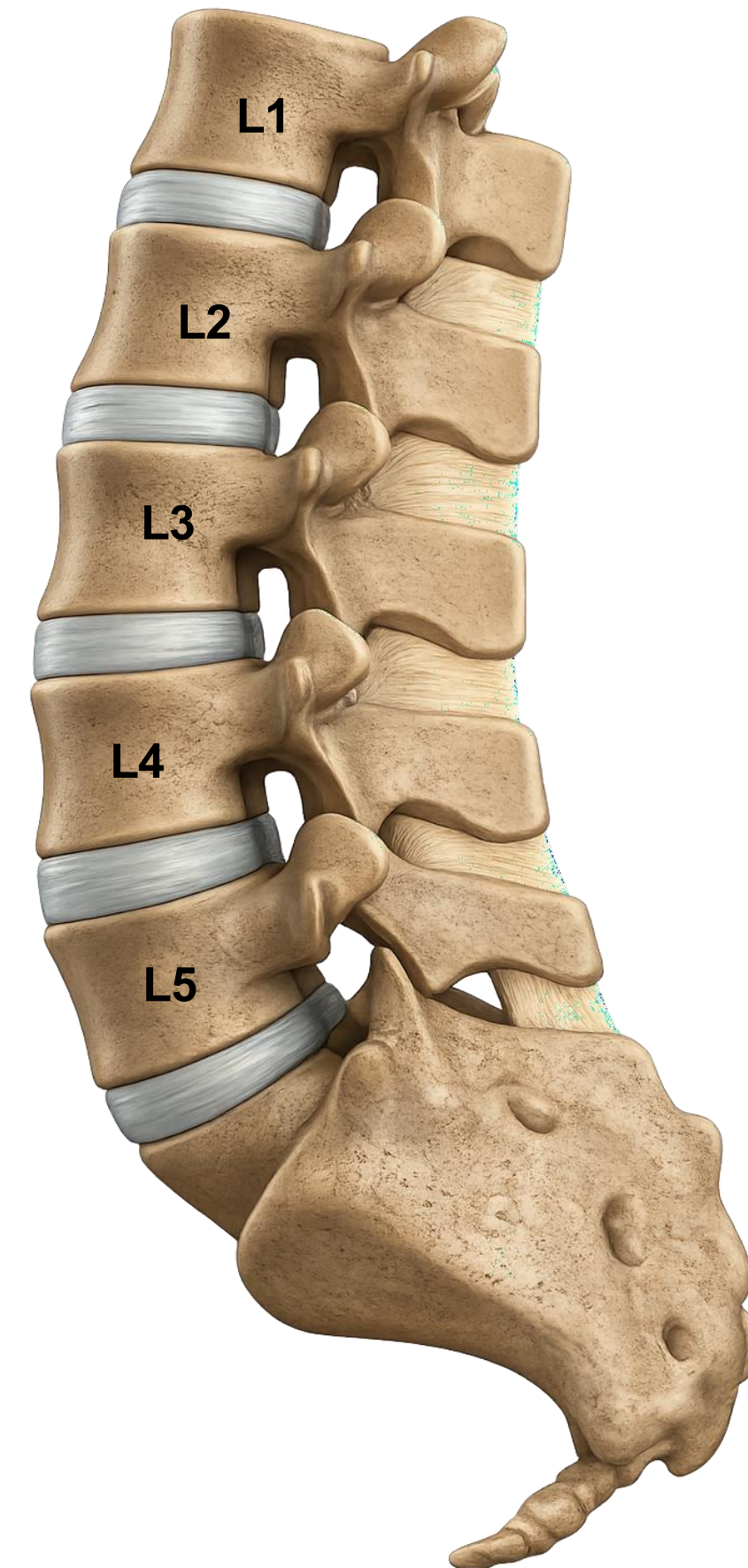
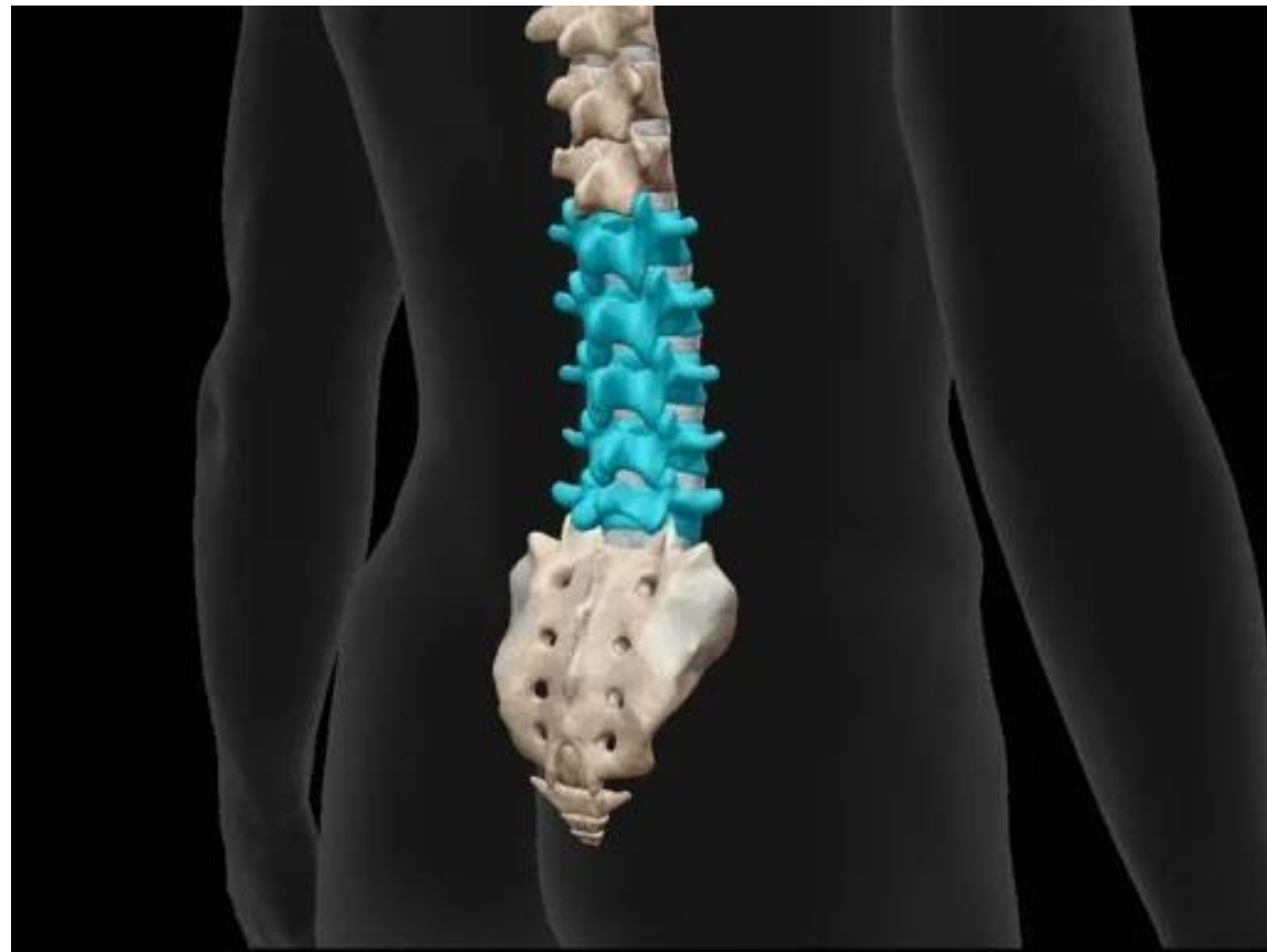# Vertebral Column

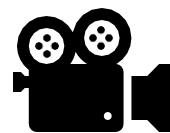
## 1. Vertebrae

### 3. Lumbar Vertebrae (5)

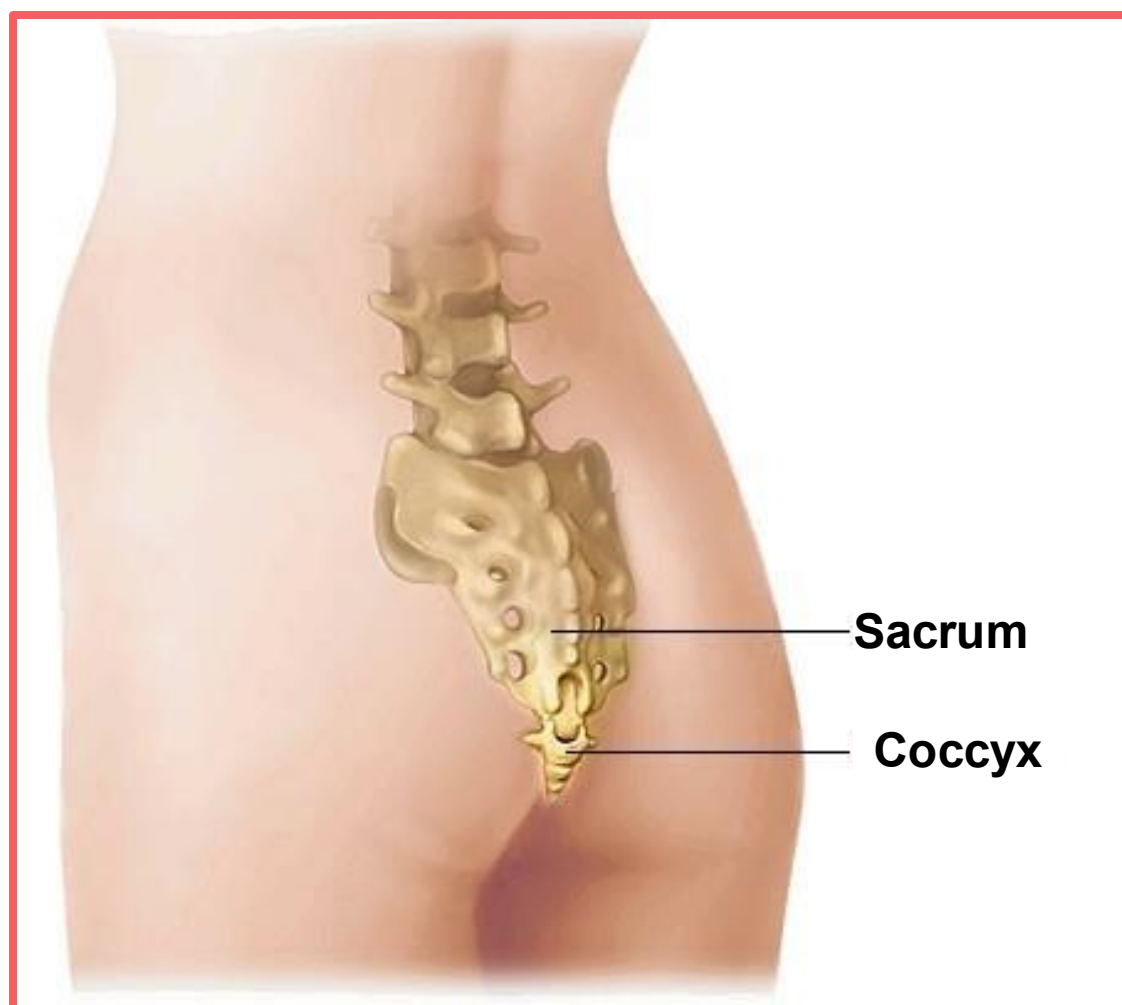
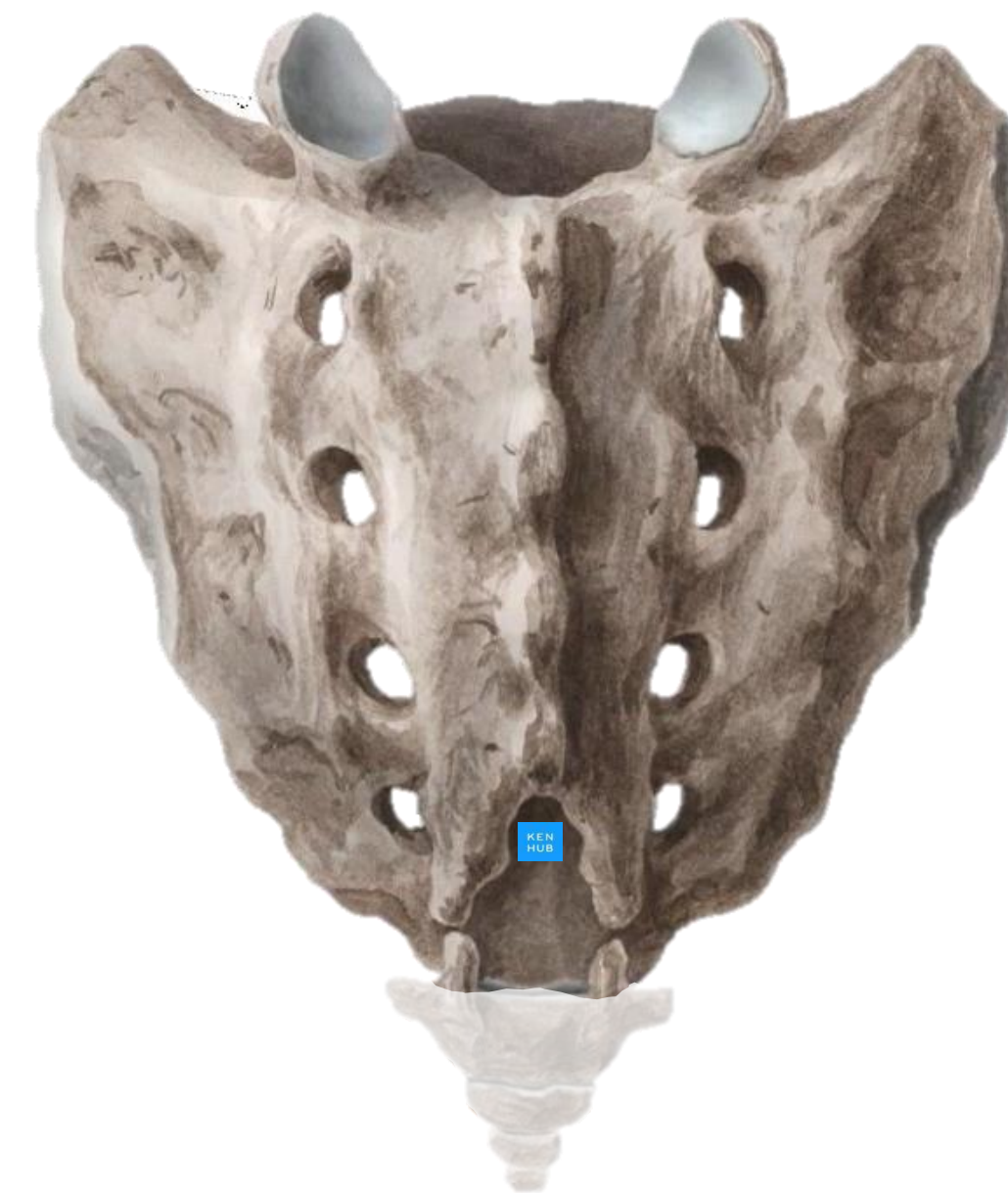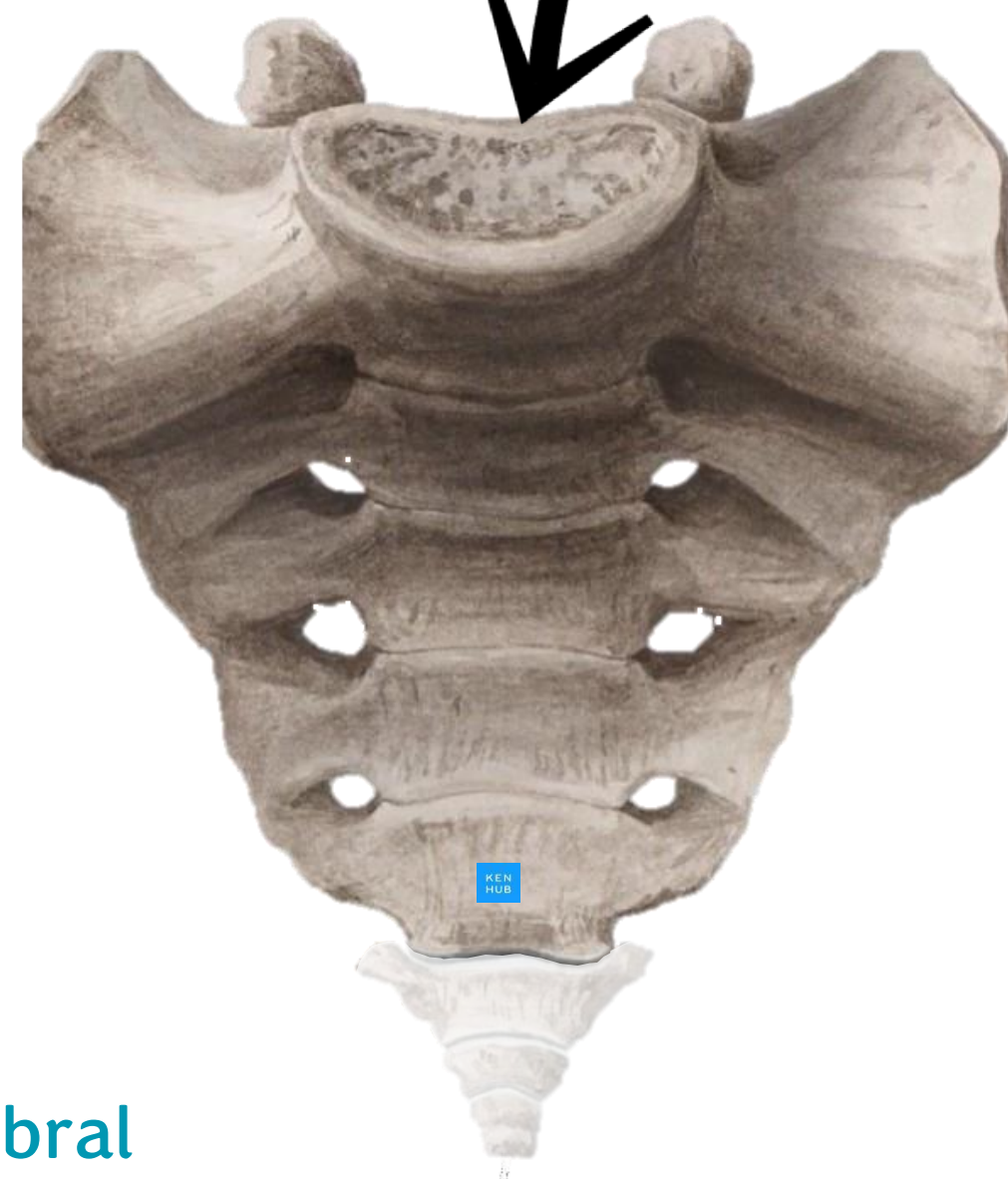
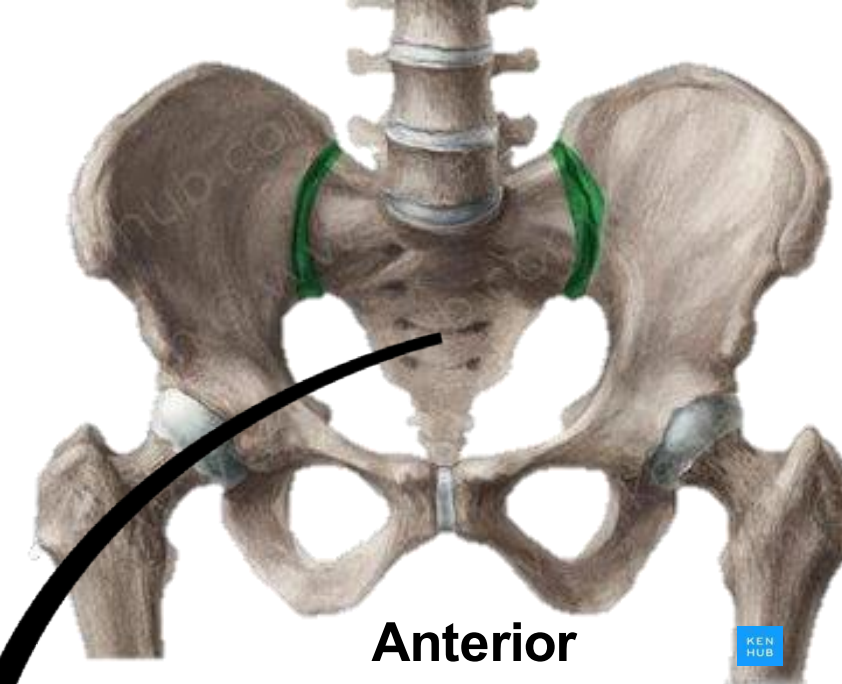


- Found posterior to the abdomen.
- Have intervertebral discs between every two vertebrae.



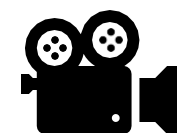
4. Sacral Vertebrae (5)

- Found in the posterior portion of the pelvic cavity.
- Fused vertebrae, have no intervertebral discs.
- Articulates with the hip bones (sacroiliac joint)



After age 20 (after childhood), the intervertebral disks are **degenerated**, and the sacral vertebrae fuses to become a single bone named sacrum bone

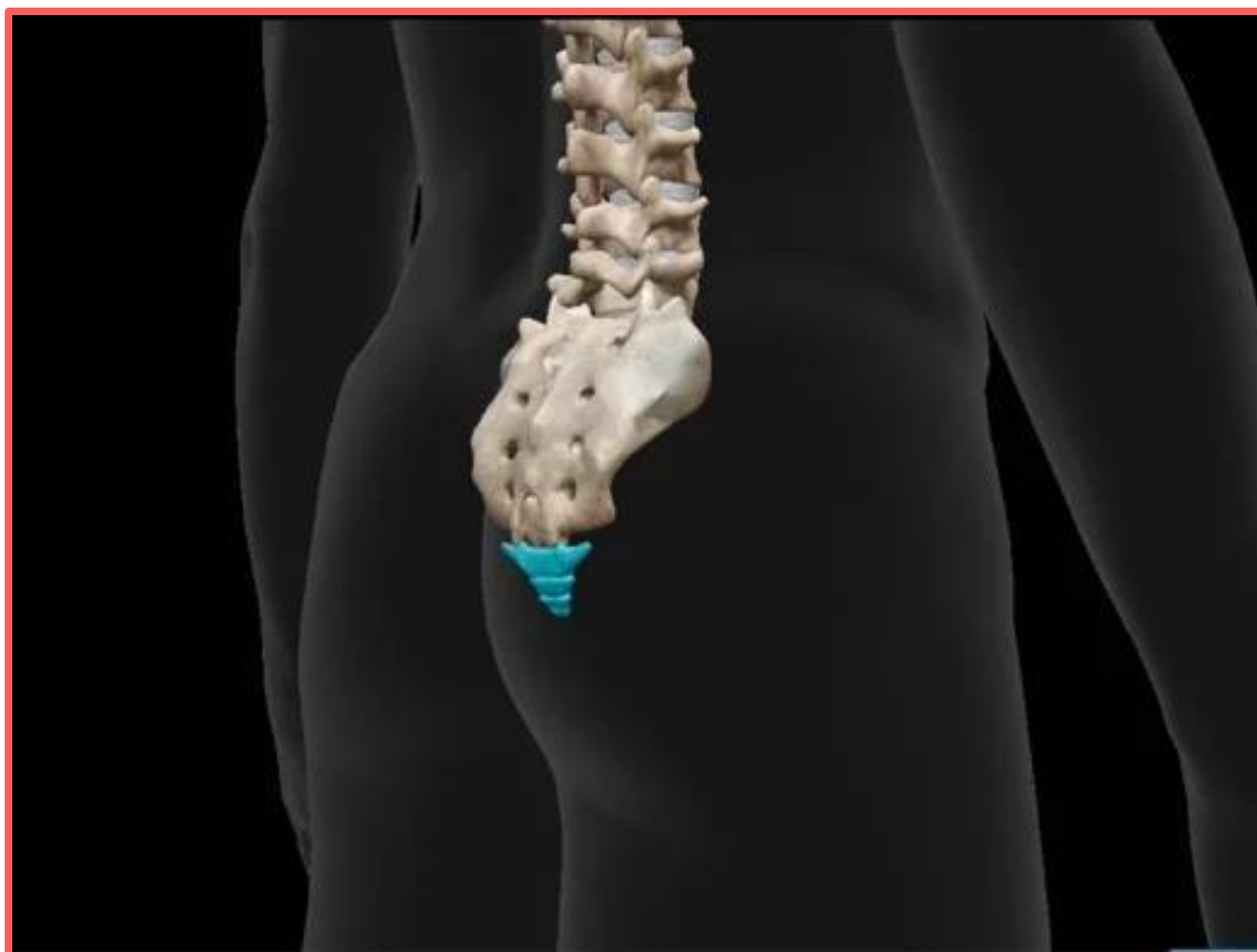
### 5. Coccygeal Vertebrae (4)



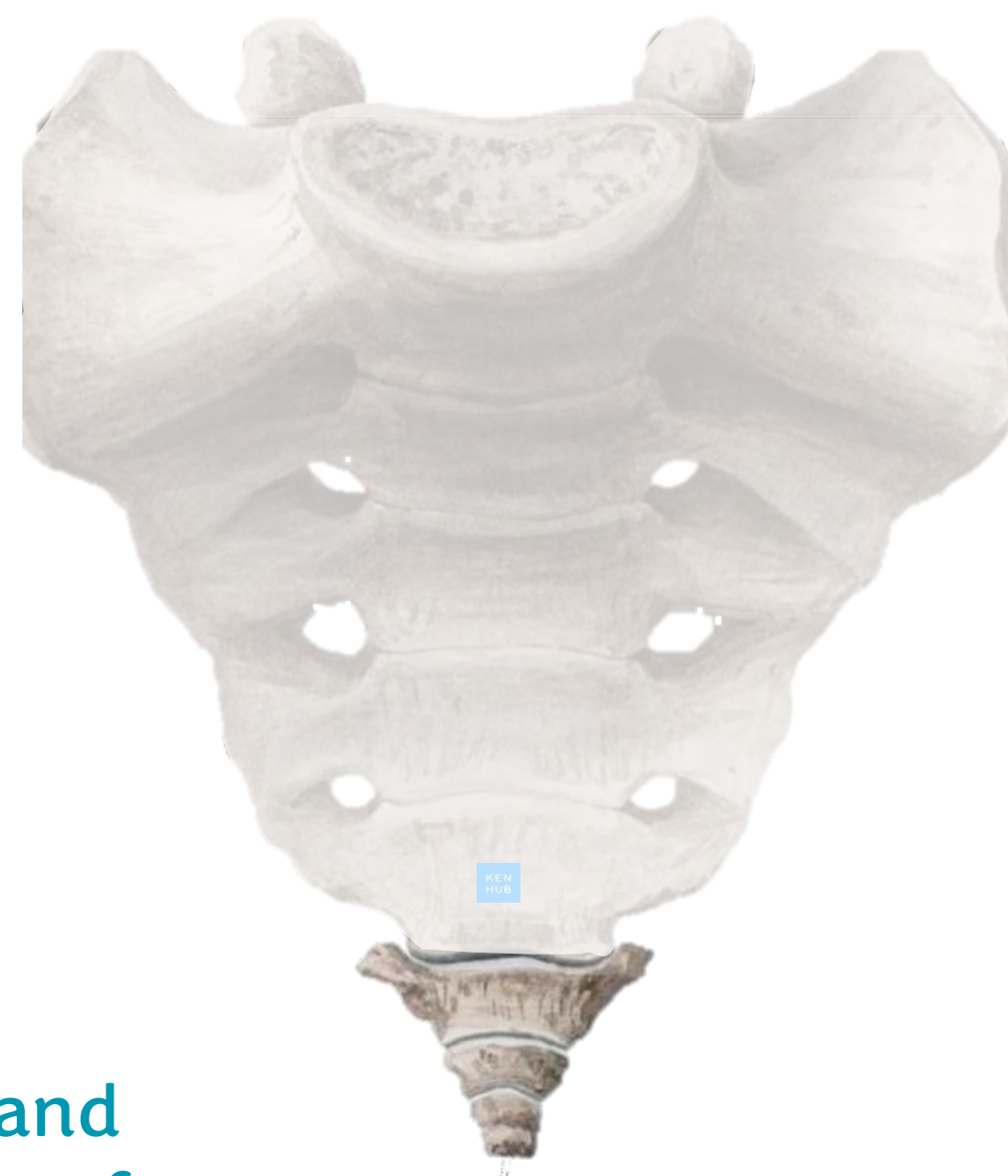- Found at the lower end of the vertebral column.
- Fused vertebrae, have no intervertebral discs.
- Articulates with the sacrum.

It is located in the inferior part of sacrum

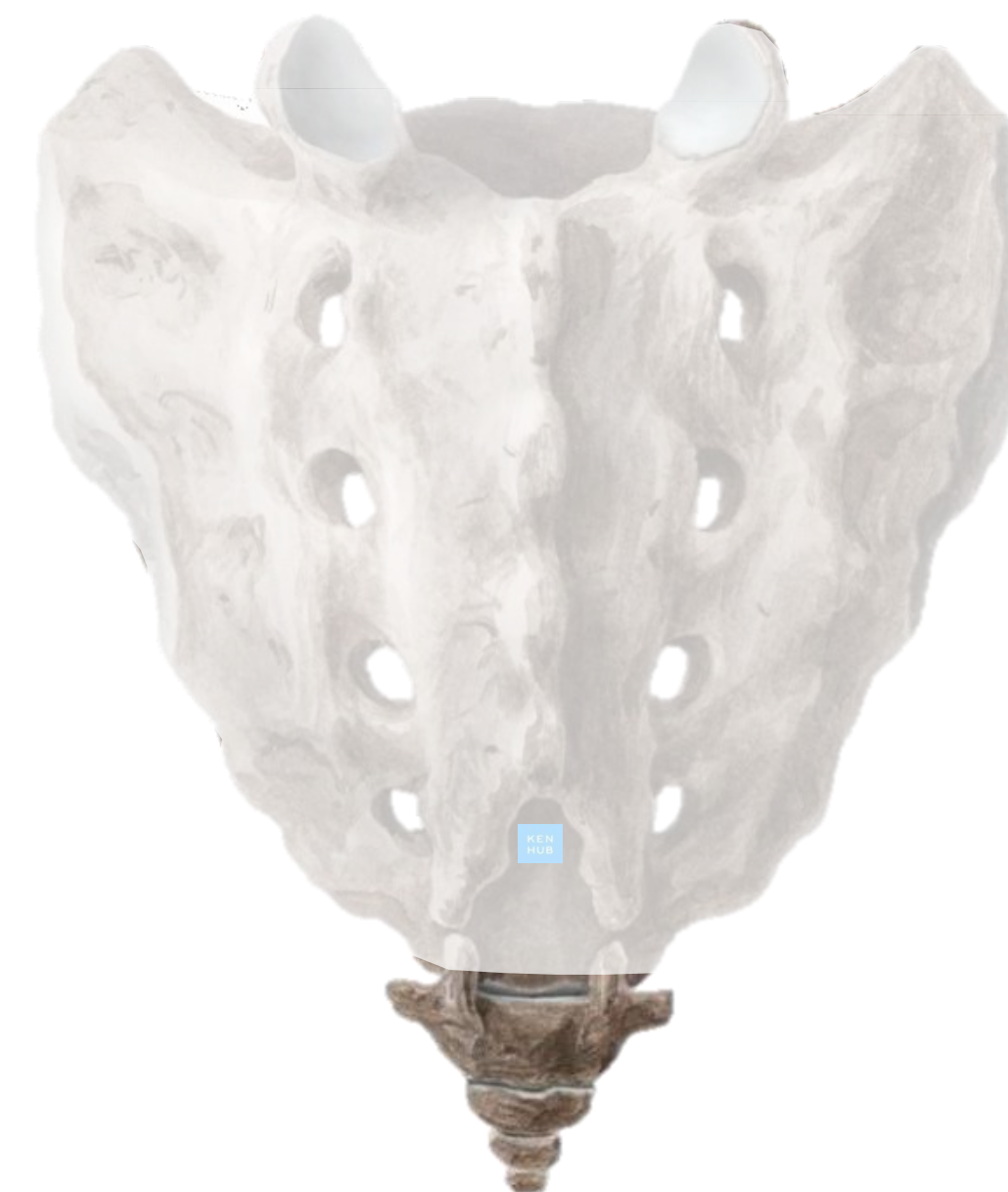After age 20 (after childhood), the intervertebral disks are degenerated, and the coccygeal vertebrae fuse to become a single bone named coccyx bone



Normal vertebral column has 33 vertebrae, and we can also say 26 (if we consider the fusion of coccygeal and sacral vertebrae)



Anterior



Posterior

# Vertebral Column

## 1. Vertebrae

➤ **Structure of a Typical Vertebra:** Typical vertebrae are vertebrae that has similar common features and structures.

1. **Body:** Thick, disc-shaped anterior portion. The intervertebral disc is located between the bodies of two vertebrae.

2. **Vertebral Arch:** Extends posteriorly from the body of the vertebra.

3. **Processes (7):**

i. **Two transverse Processes:** Extend laterally on each side.

ii. **Spinous Process:** Spin-like structure projecting posteriorly. You feel the tips of the spinous process when you touch the middle of your back .

iii. **Two superior articular processes:** Project superiorly and articulate with the two inferior articular processes of the vertebra immediately above them.

iv. **Two inferior articular processes:** Project inferiorly and articulate with the two superior articular processes of the vertebra immediately below them.

1. **Vertebral Foramen**

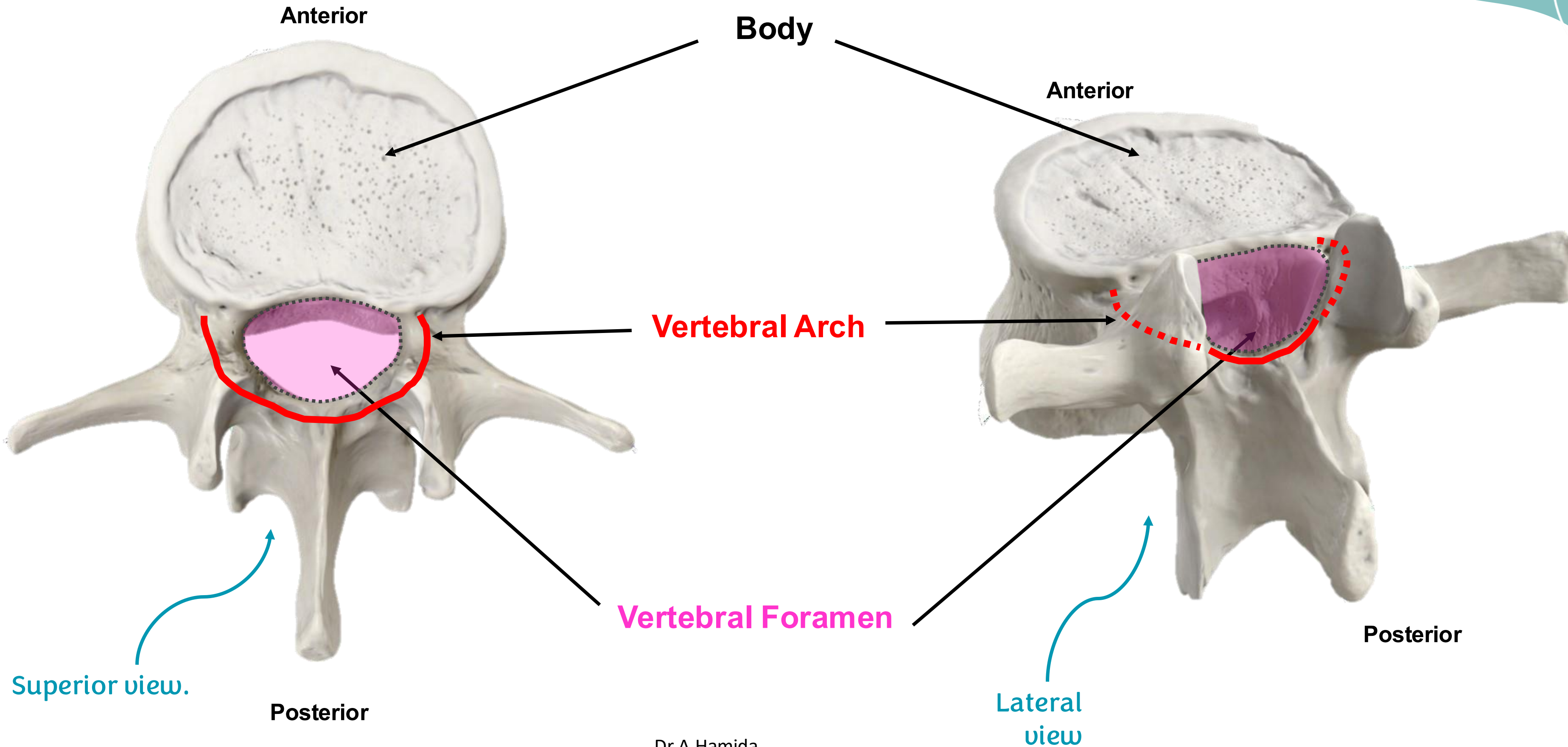
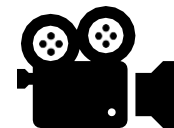- Central space.

- The vertebral foramina of all vertebrae form the vertebral (spinal) canal, which houses the spinal cord.

# Vertebral Column

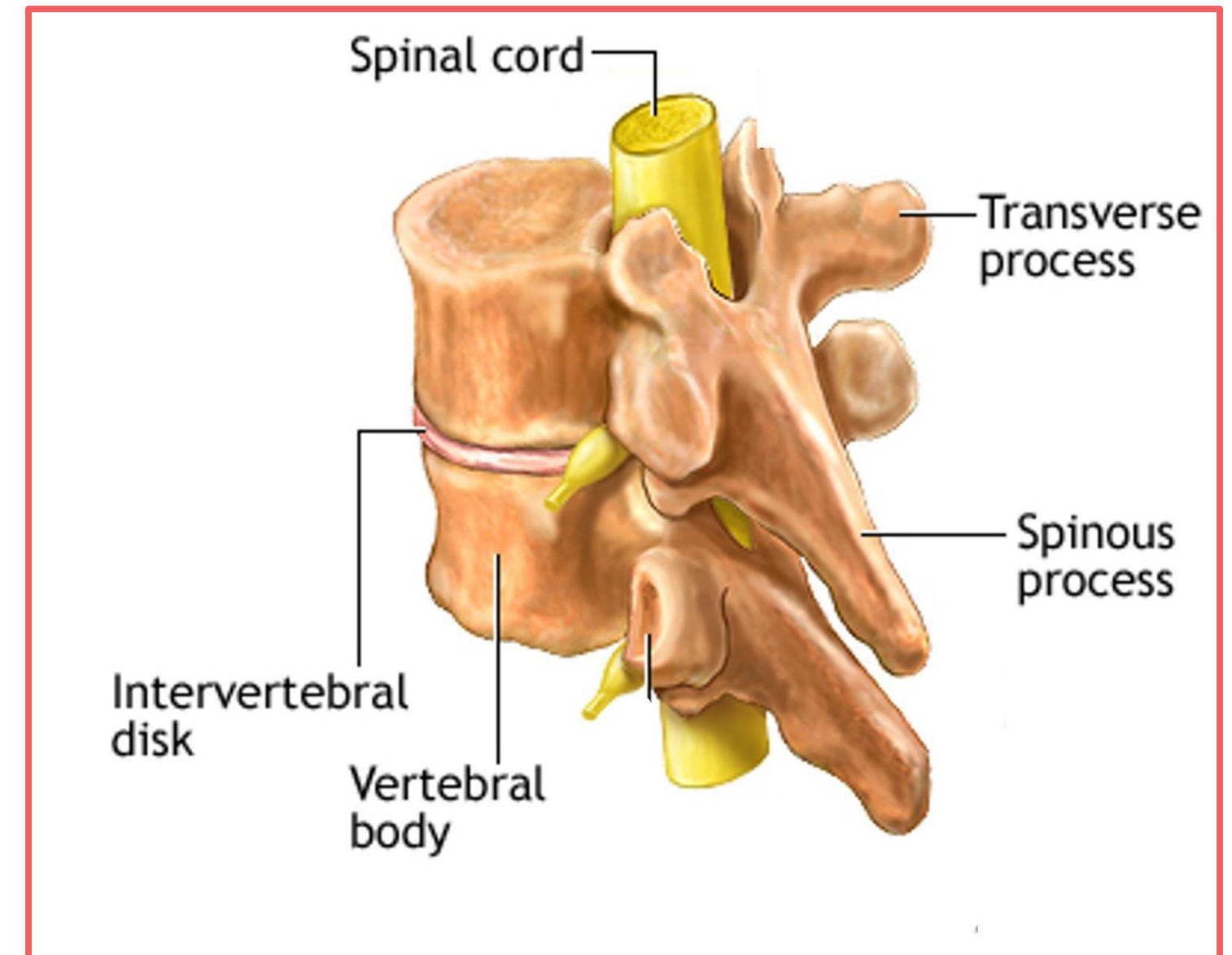
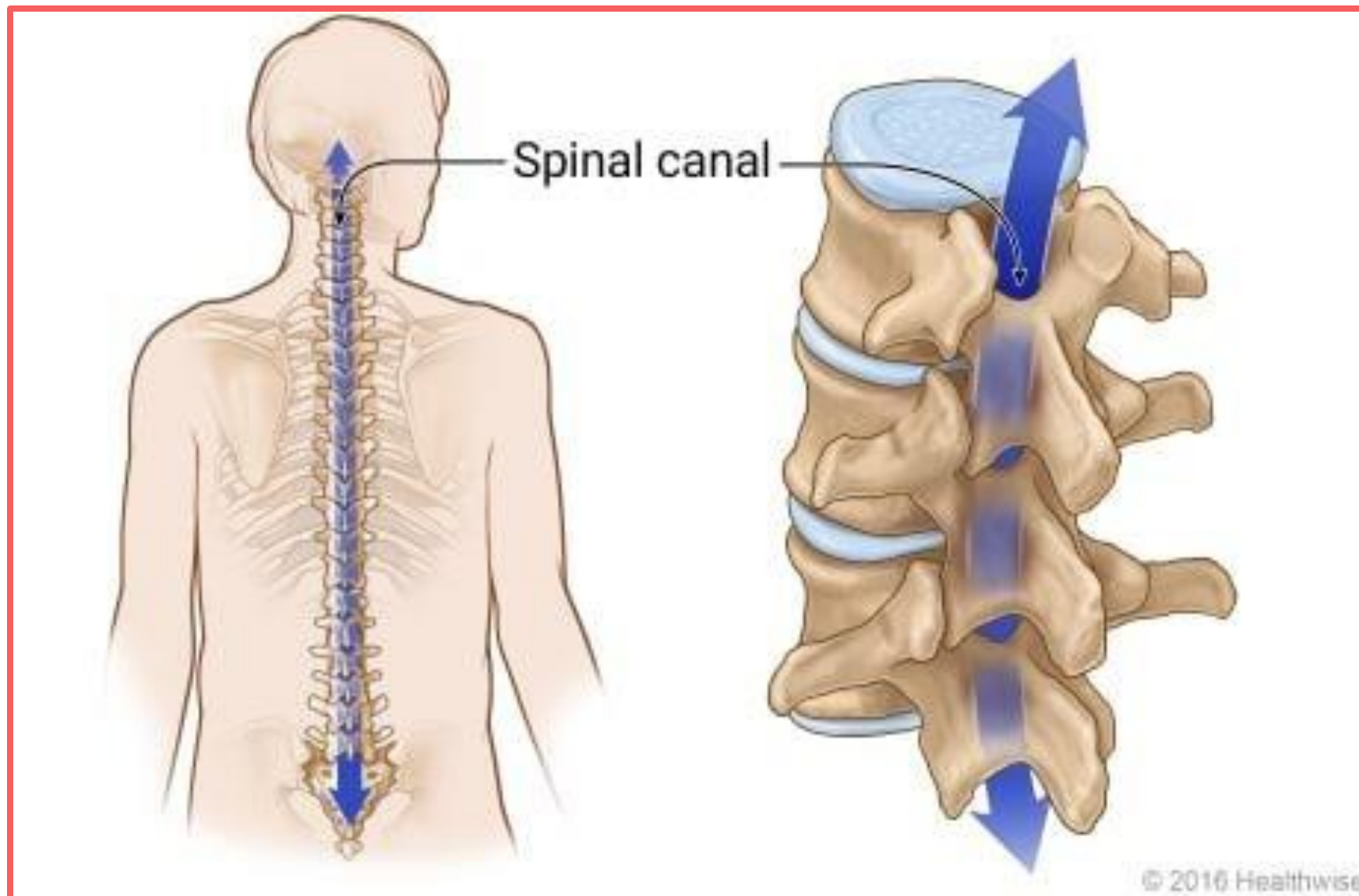
## 1. Vertebrae

### ➤ Structure of Typical Vertebra



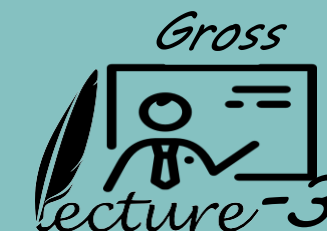### ➤ Structure of Typical Vertebra Spinal Canal

- **Vertebral foramina of all vertebrae form the vertebral (spinal) canal, which houses the spinal cord.**

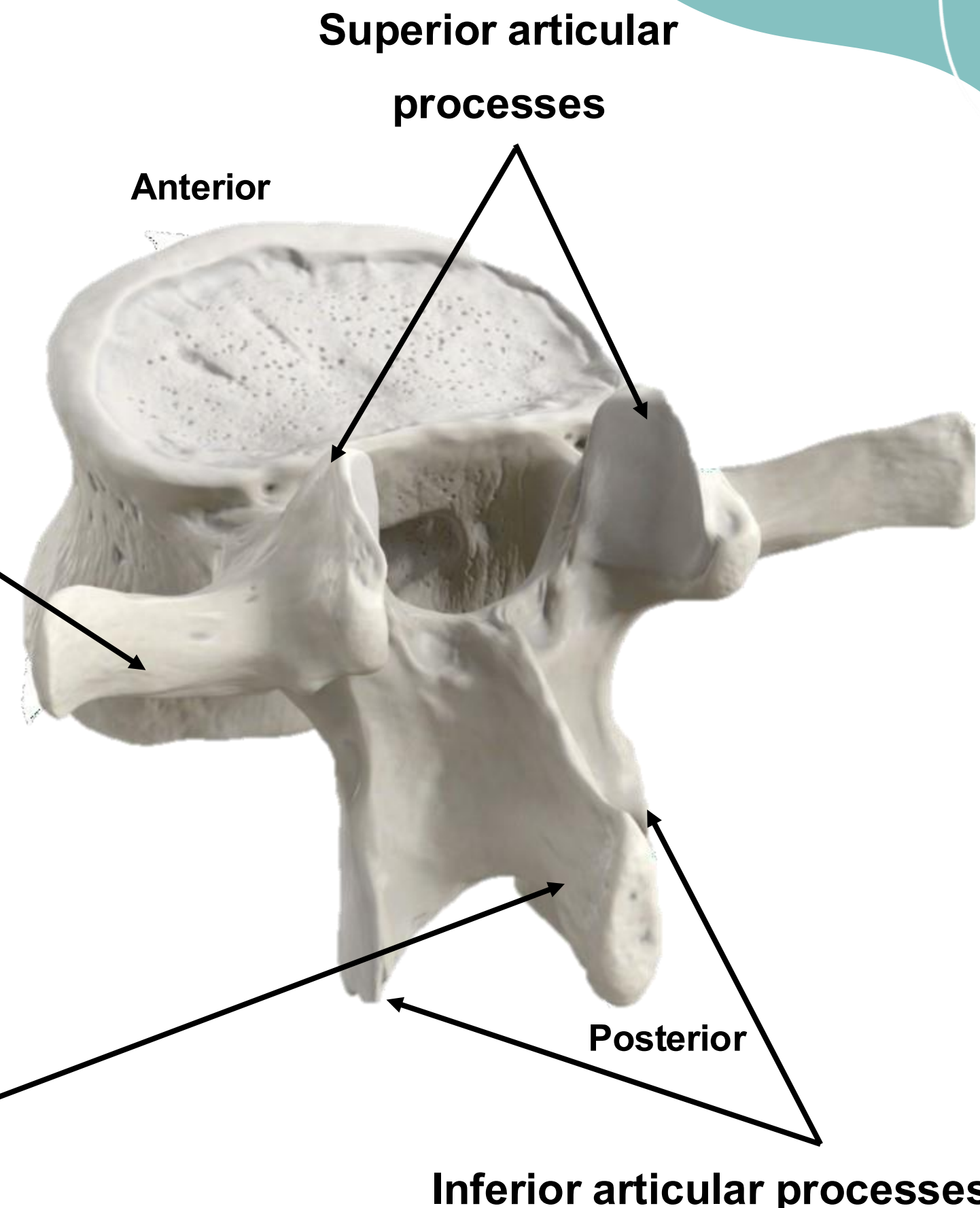
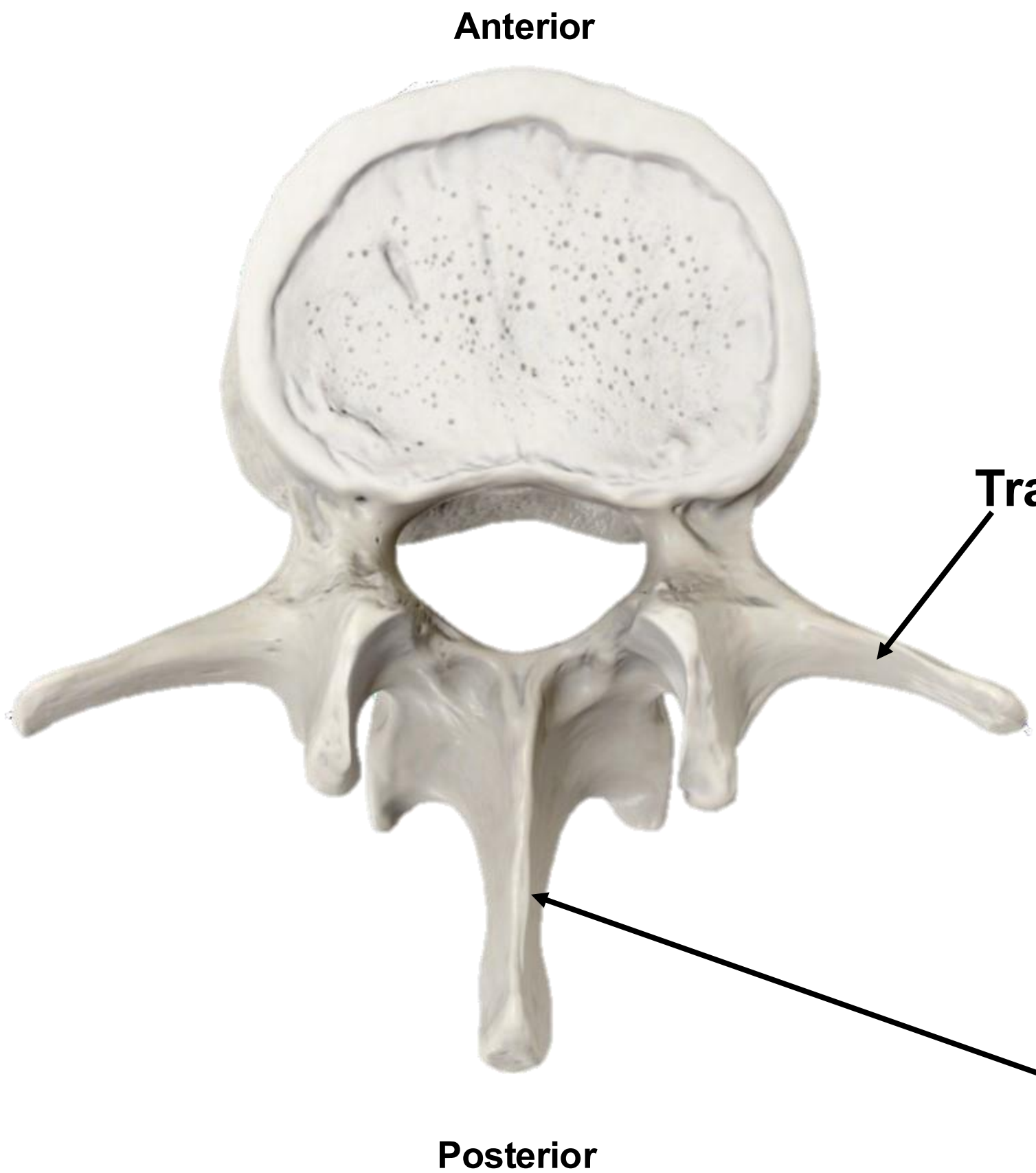
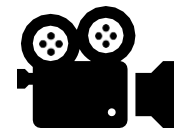


# Vertebral Column

## 1. Vertebrae



### ➤ Structure of Typical Vertebra

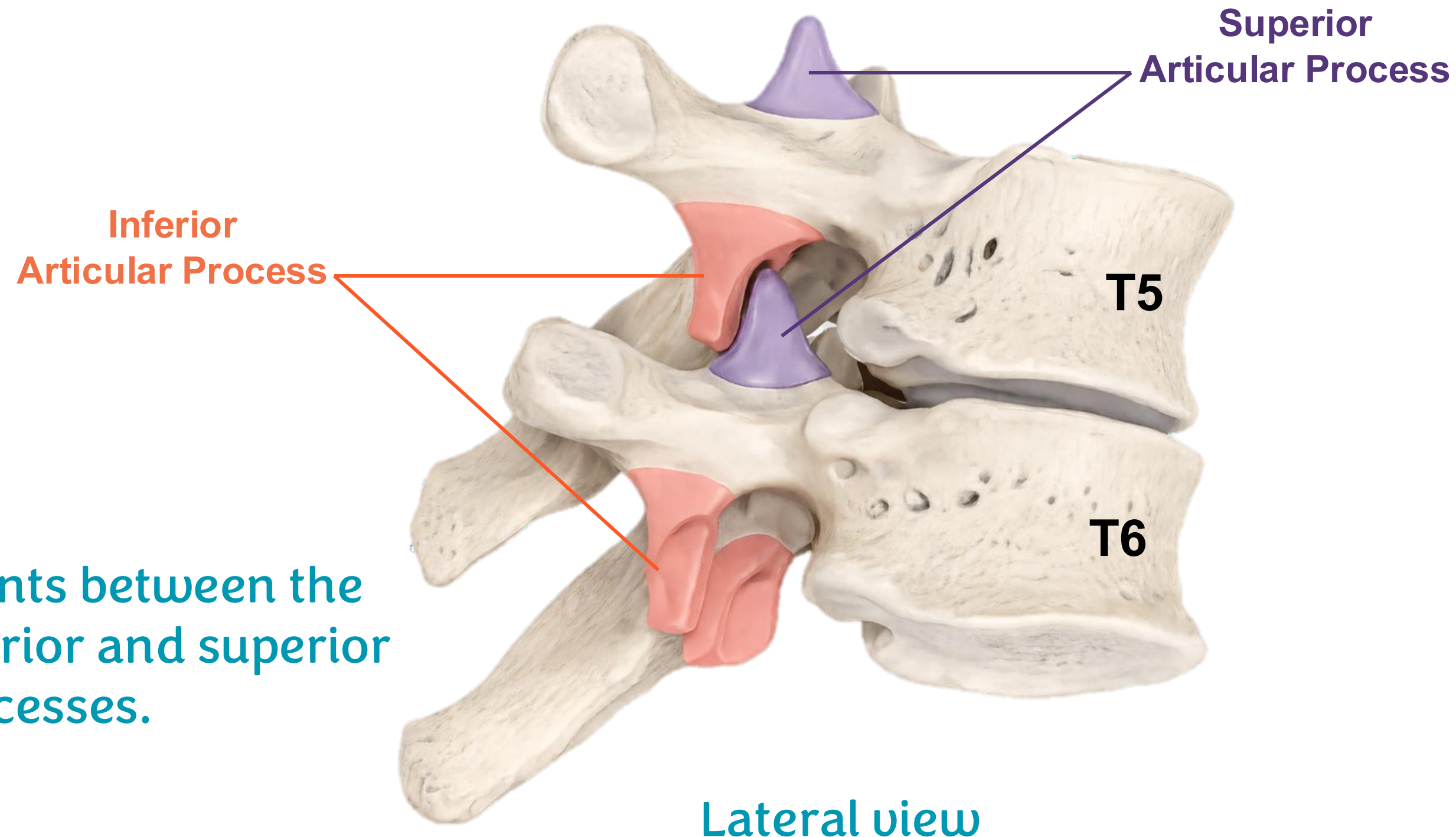


# Vertebral Column

## 1. Vertebrae

### ➤ Structure of Typical Vertebra

- Superior articular processes
- Inferior articular processes



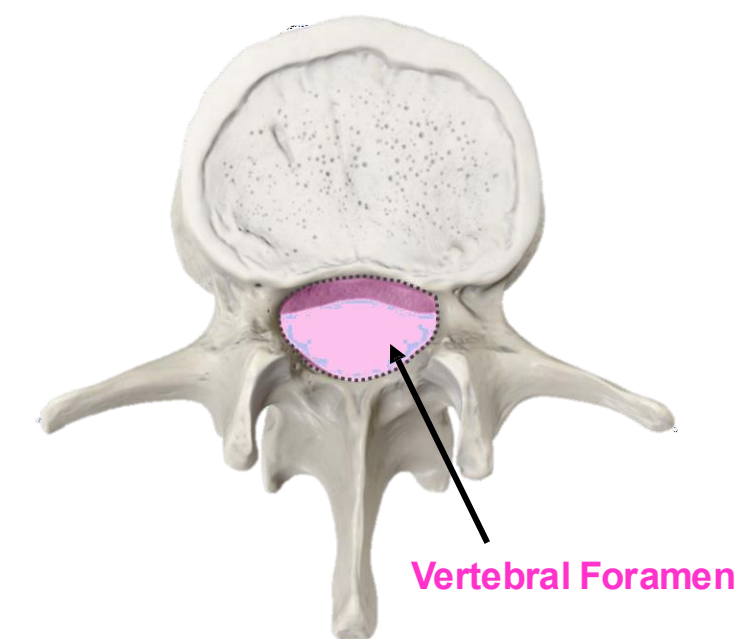
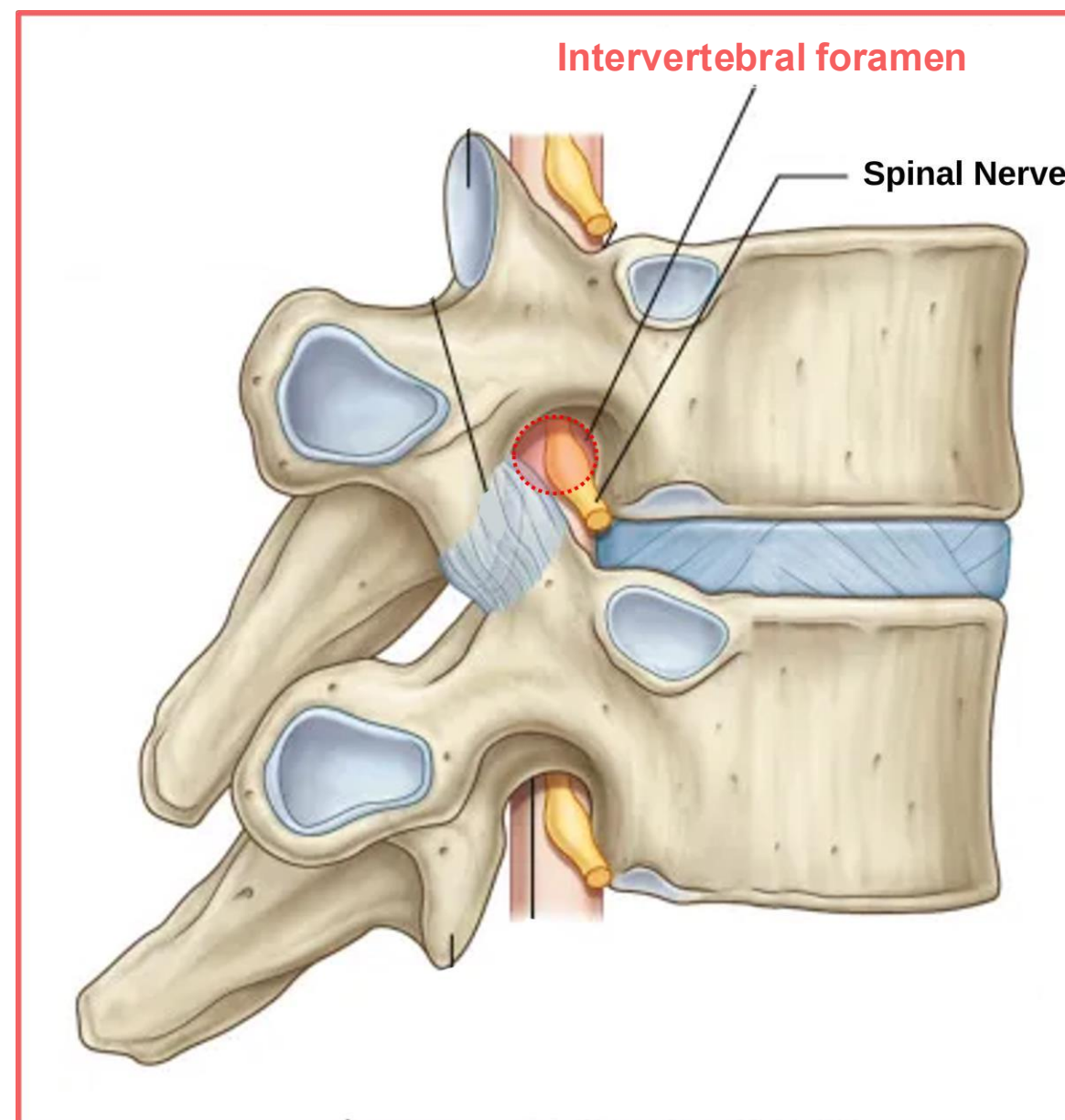
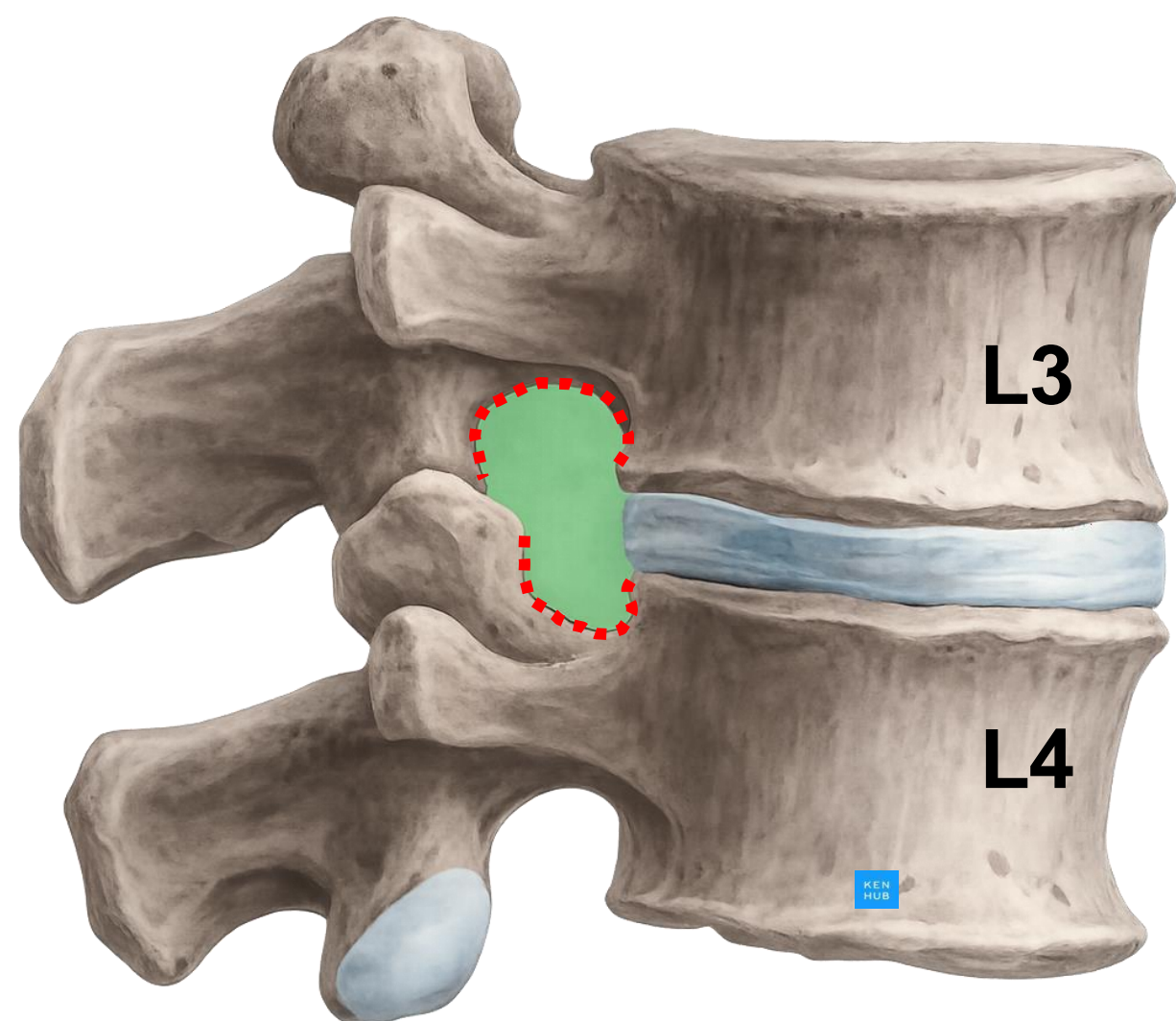
There are joints between the articular inferior and superior articular processes.

# Vertebral Column

## 1. Vertebrae

➤ Intervertebral Foramen: Inter = between

- It is a lateral opening between adjacent vertebrae formed by the superior and inferior notches.
- The foramina allow structures, such as spinal nerves and blood vessels, to pass in and out of the vertebral canal.

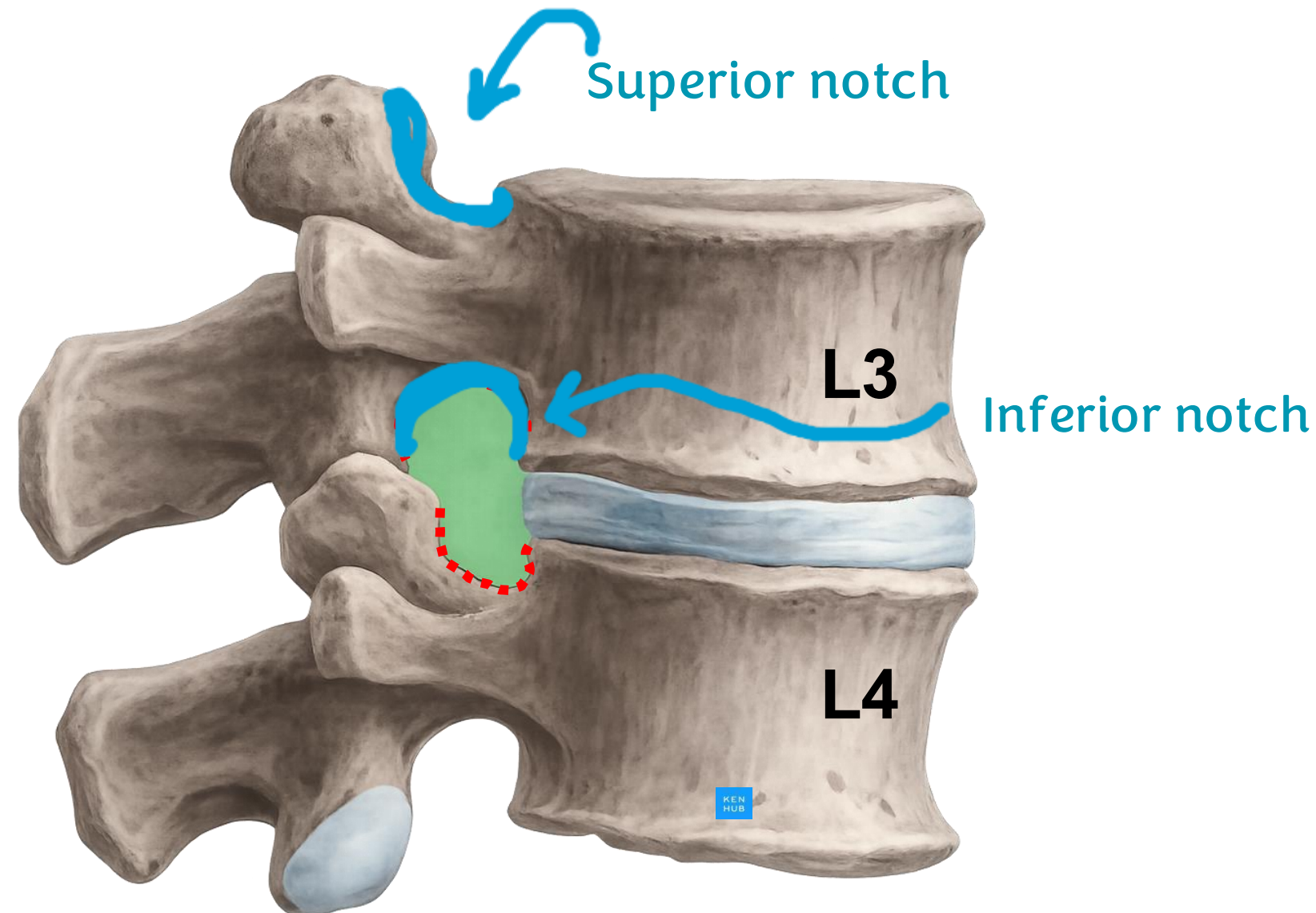


# Vertebral Column

## 1. Vertebrae

- All typical vertebrae in the body have superior and inferior notches.

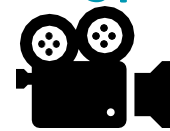When two vertebrae articulate, the inferior notch from the vertebra that's above makes a lateral opening with the superior notch from the vertebra that's below.



The intervertebral foramen is between the vertebral cavity and the other parts of the body.

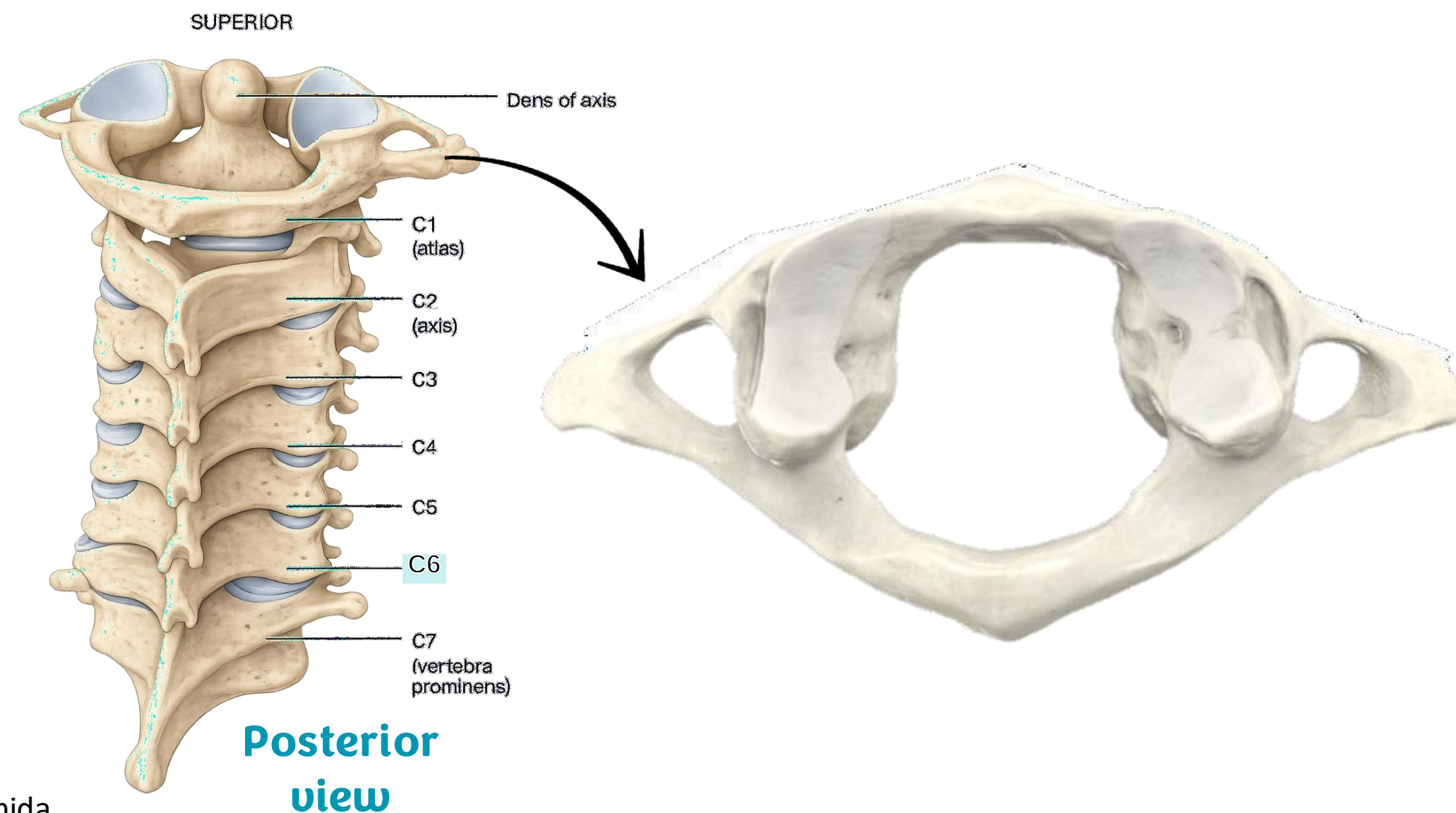
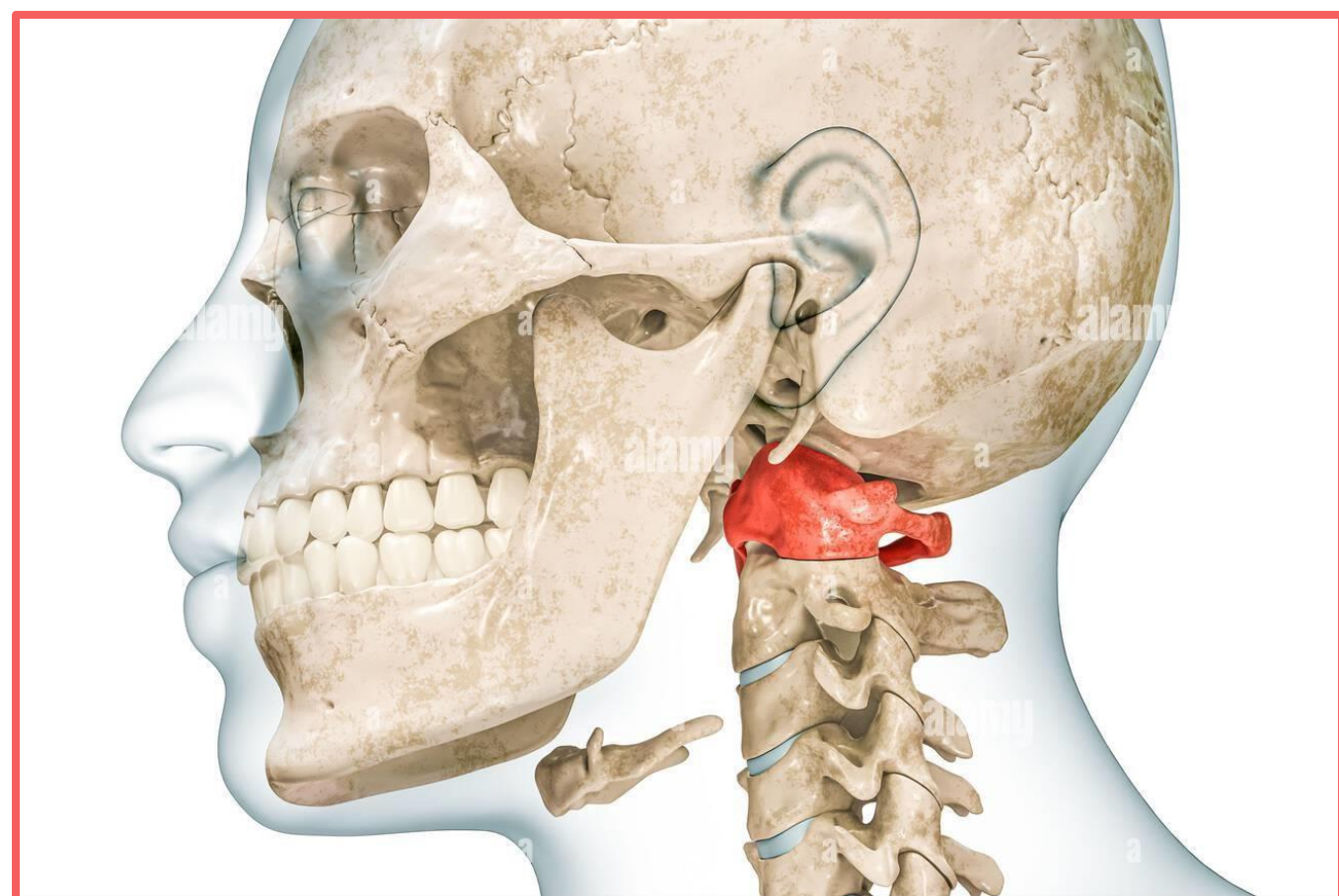
➤ **Structure of Atypical Vertebra** Atypical vertebrae are slightly different than other vertebrae.

- **1st Cervical Vertebra (Atlas)**



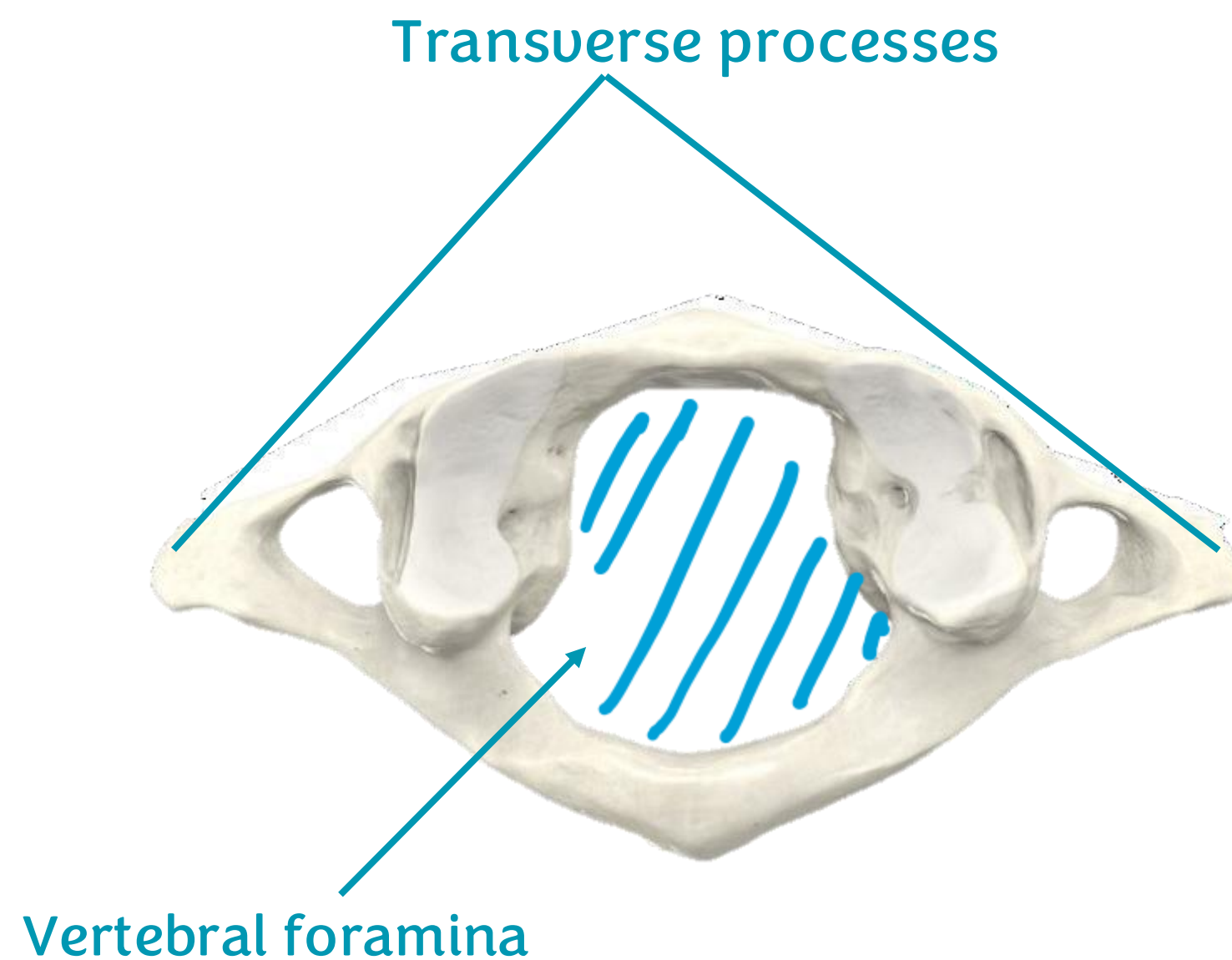
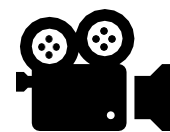
- **Named after the mythological Atlas who supported the world.**
- **Ring-shaped vertebra with no body or spinous process.**
- **Articulates with the base of the skull.**
- **Function: Allows nodding movement of the head, as when you move your head to signify “yes”.**

Its vertebral foramina is the biggest vertebral foramina in the body.



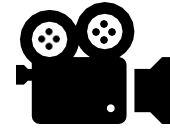
### ➤ Structure of Atypical Vertebra

- 1st Cervical Vertebra (Atlas)



- The joint between the skull and the Atlas makes us able to nod.

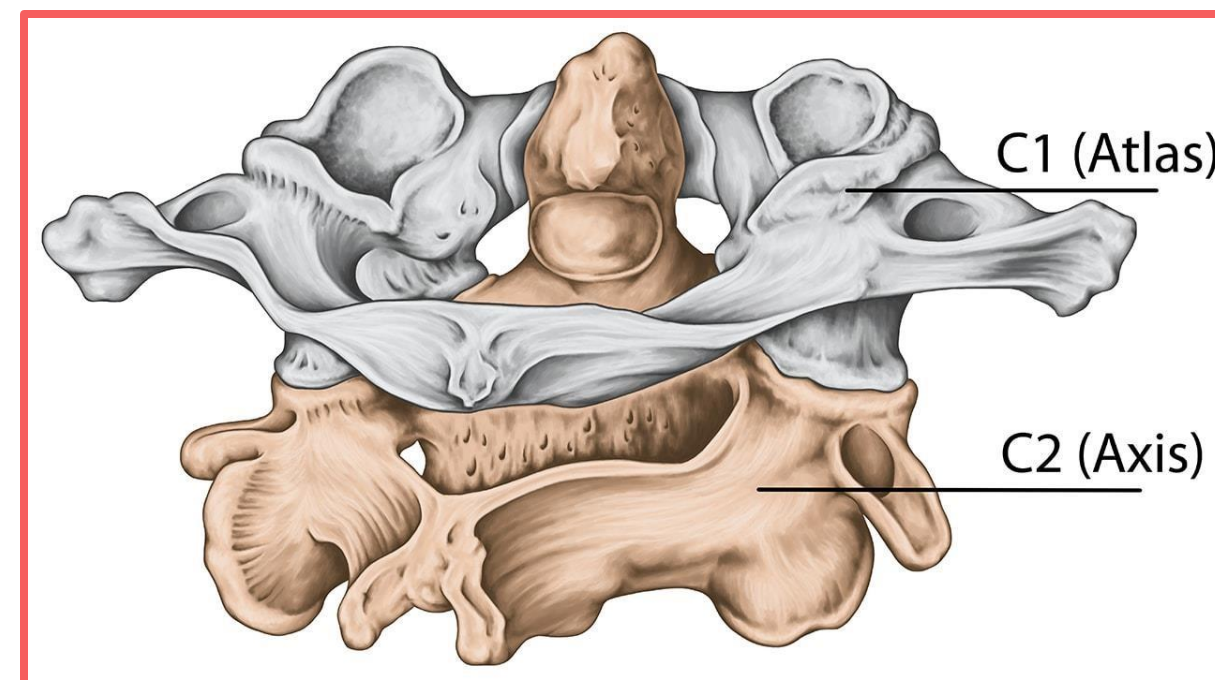
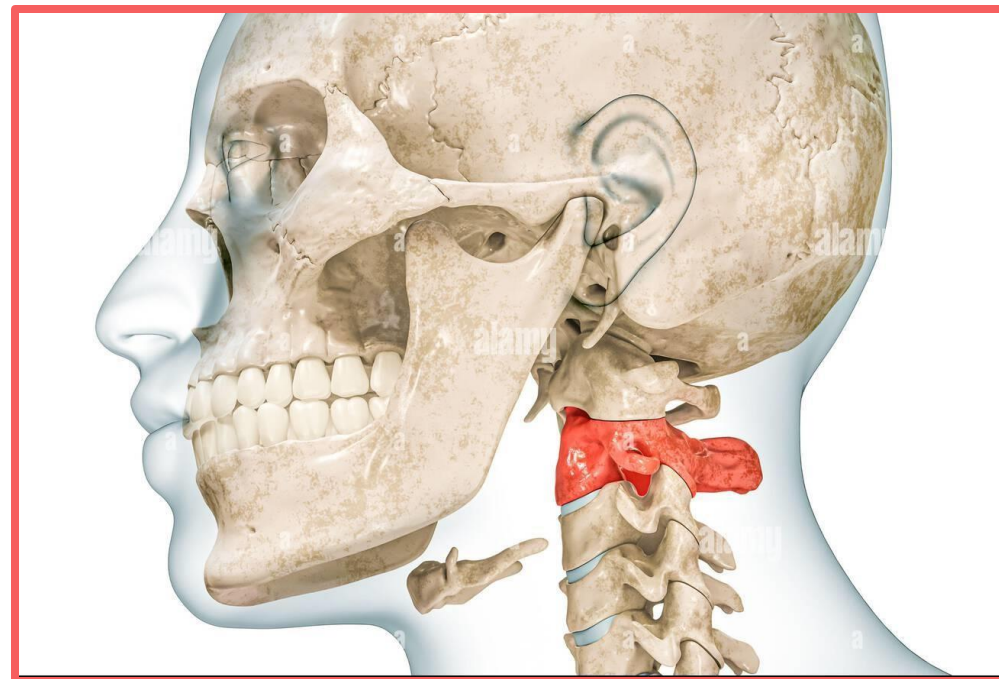
## ➤ Structure of Atypical Vertebra

• 2<sup>nd</sup> Cervical Vertebra (Axis)

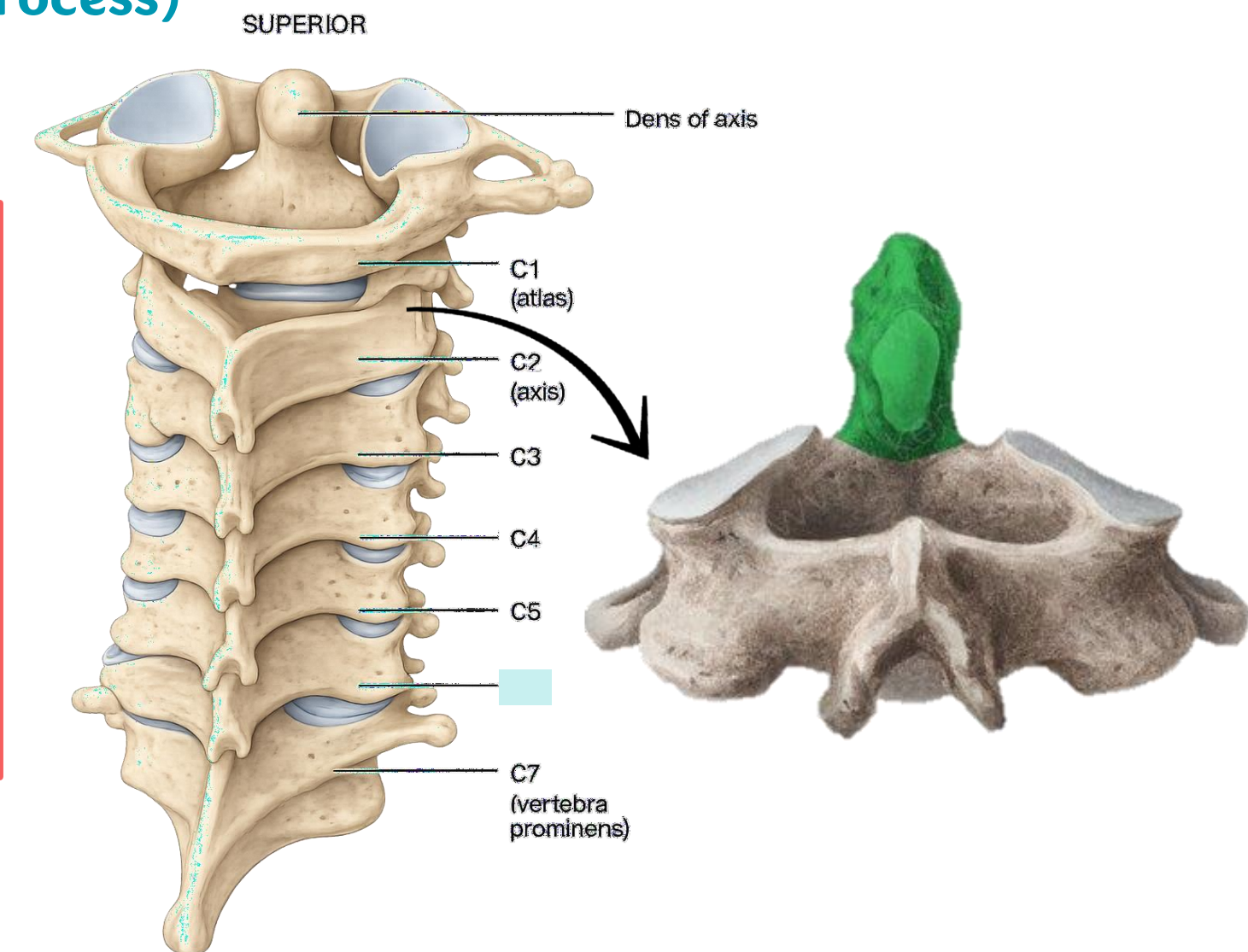
- Features a peg-like projection called the dens (= tooth) or odontoid process, which projects superiorly through the anterior portion of the vertebral foramen of the atlas.
- The dens acts as a pivot on which the atlas and head rotate.
- Function: Allows side-to-side movement of the head, as when you move your head to signify “no”.

The C2 vertebra (Axis) has 8 processes(it doesn't lack a spinous process) and it has an extra process (odontoid).

The C2 vertebra (Axis) has a large body unlike the C1



Posterior  
view



# Vertebral Column

## 2. Intervertebral Discs

- The bodies of adjacent vertebrae are united by intervertebral discs.
- The disc consists of two parts:

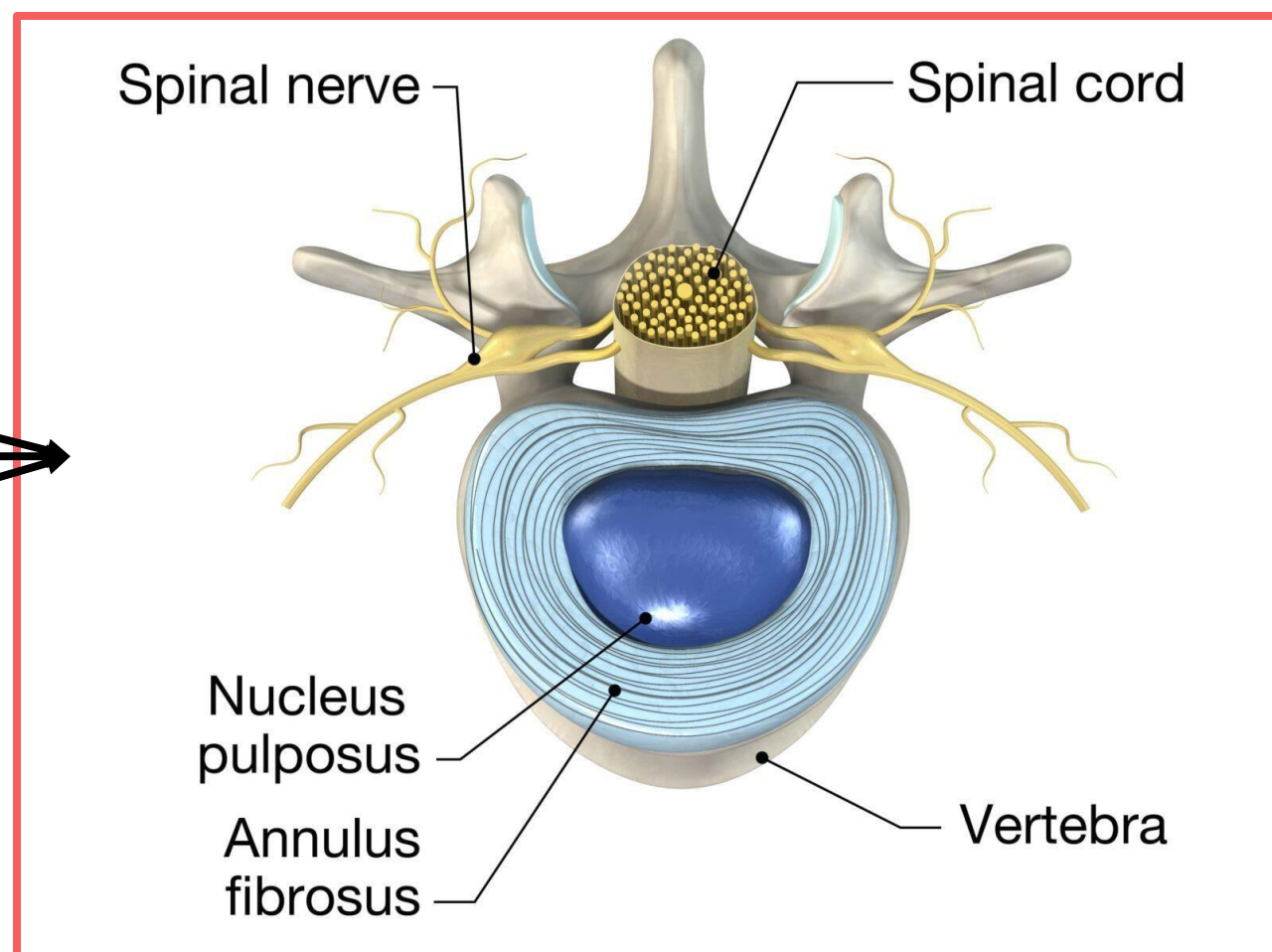
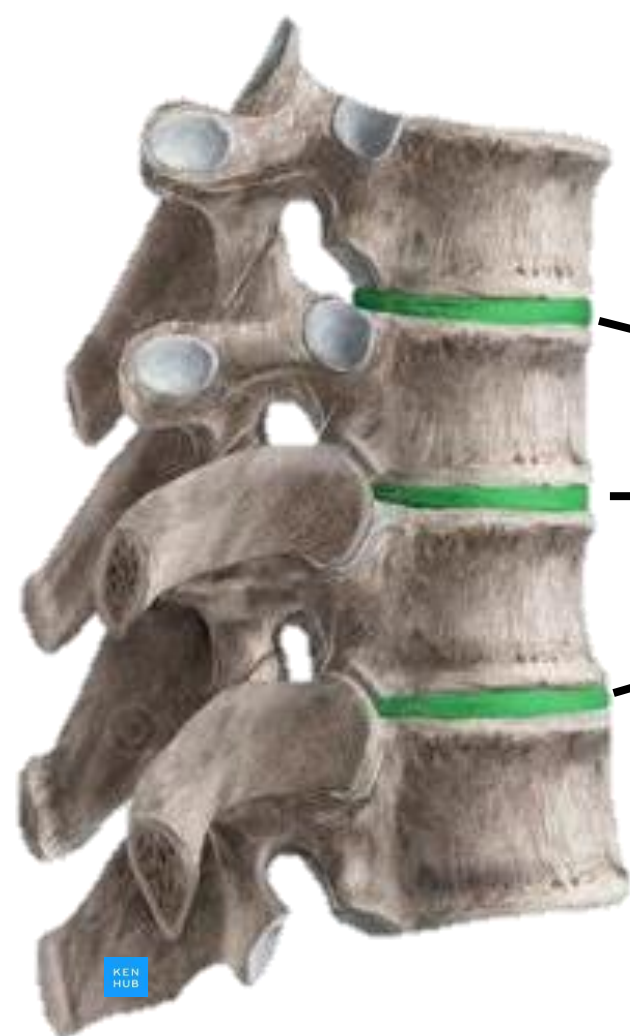- Annulus Fibrosus

Outer fibrocartilage ring that protects the central part.

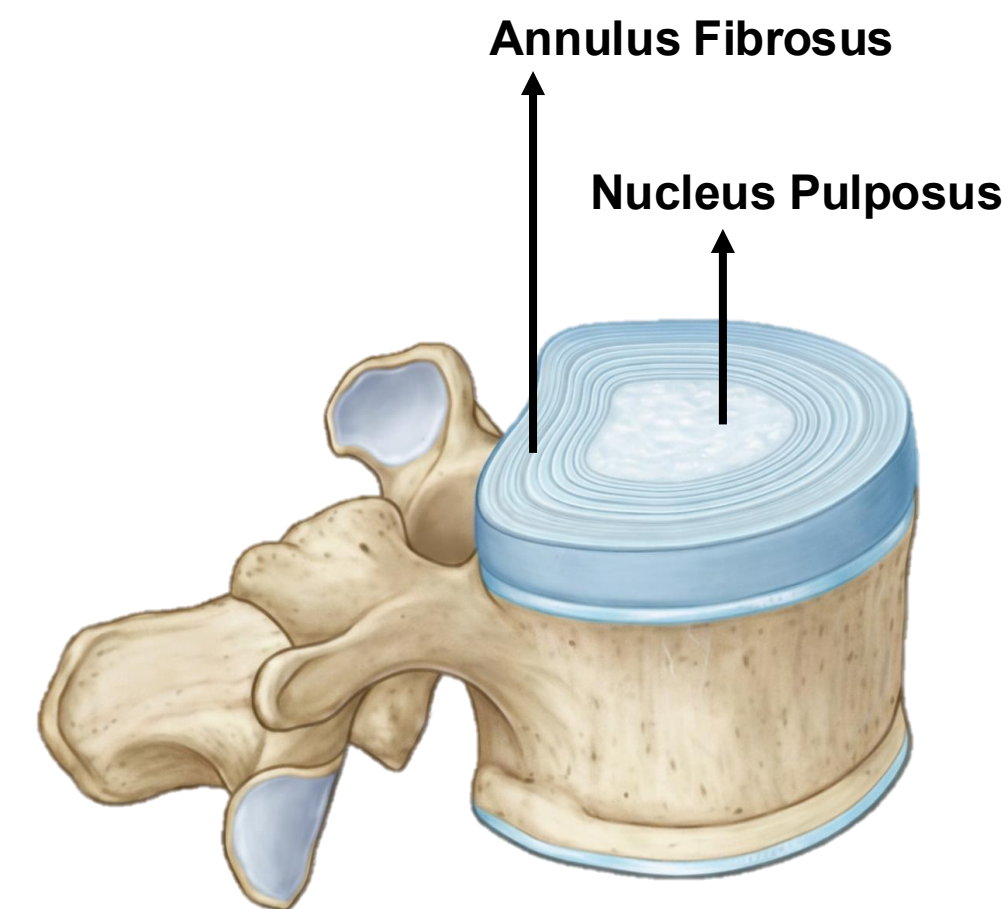
- Nucleus Pulposus

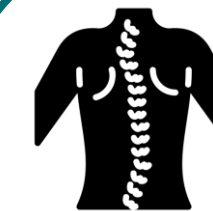The jelly-like material in the intervertebral discs absorbs the overweight.

Inner gelatinous core (jelly-like material) acting as a cushion or shock absorber.



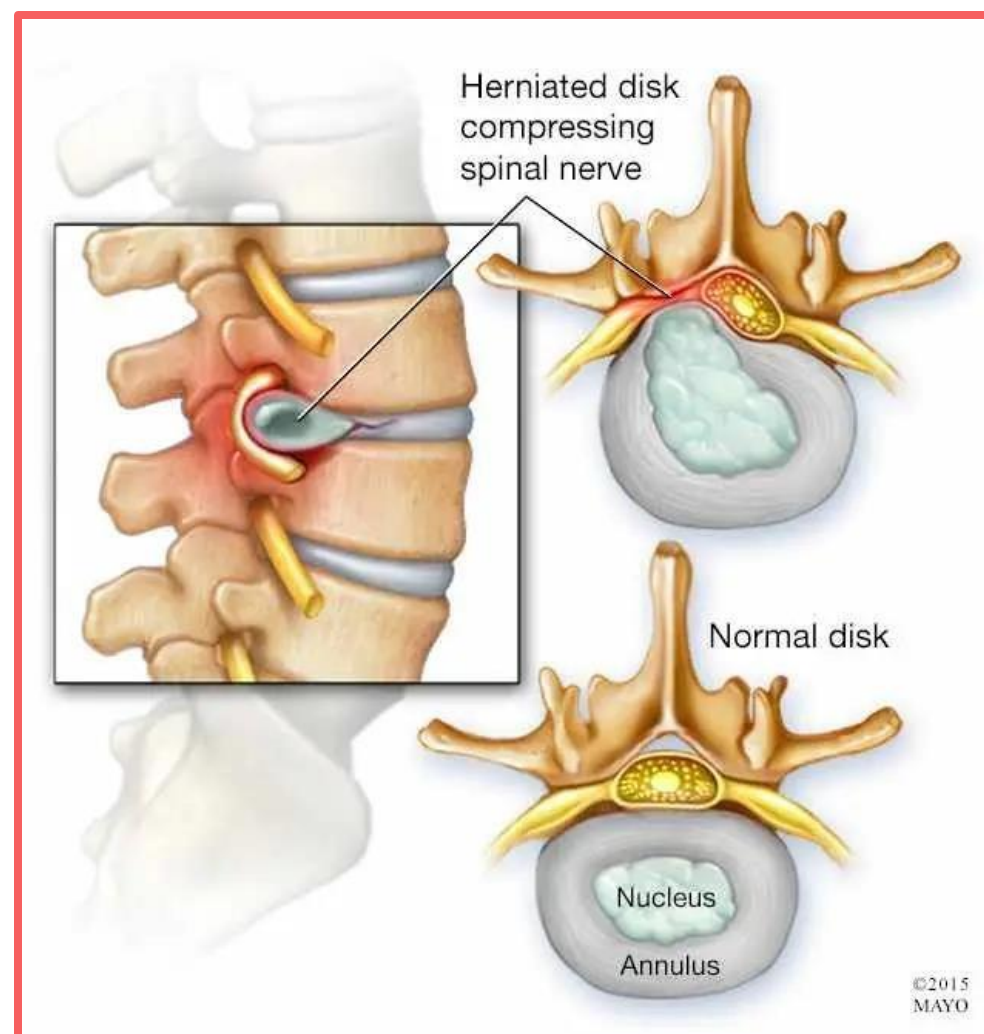
Top view



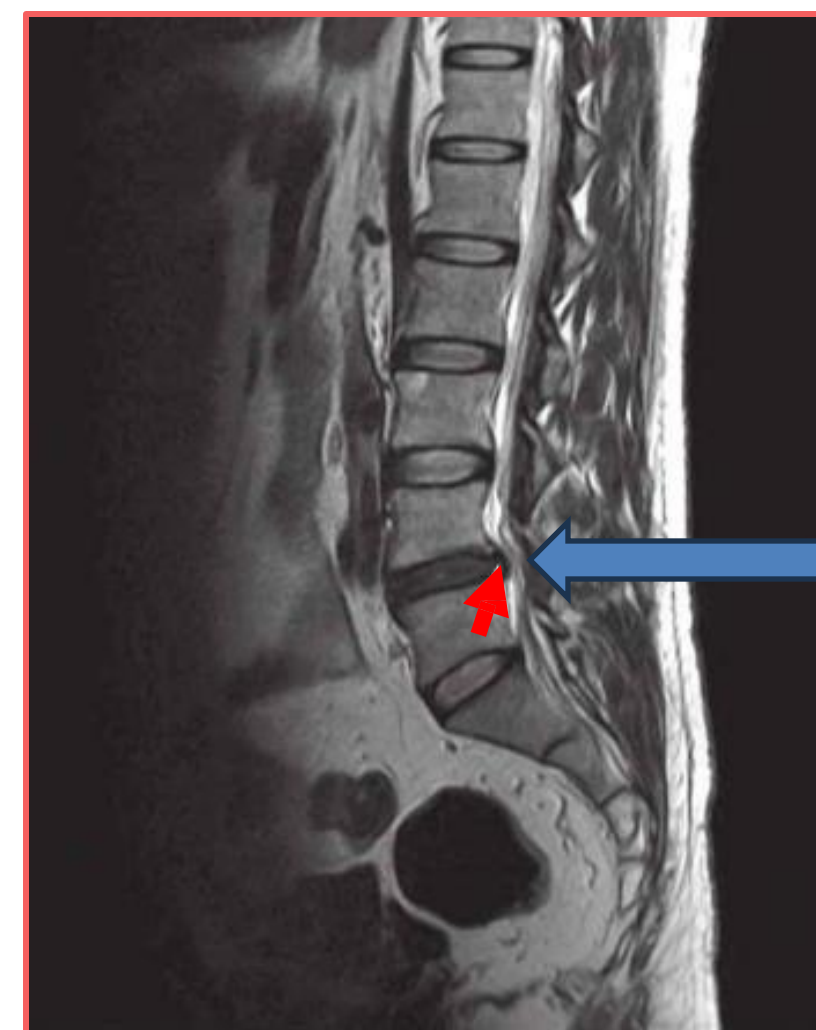


## Herniated (Slipped) Disc

- Excessive pressure on the nucleus pulposus can rupture the annulus fibrosus, causing the nucleus to herniate posteriorly or into adjacent vertebrae.
- This movement exerts pressure on spinal nerves, causing acute pain and weakness.
- Most common in the lumbar region due to high weight-bearing and mobility.



Dr A.Hamida



Midsagittal view

The spinal cord

# Vertebral Column

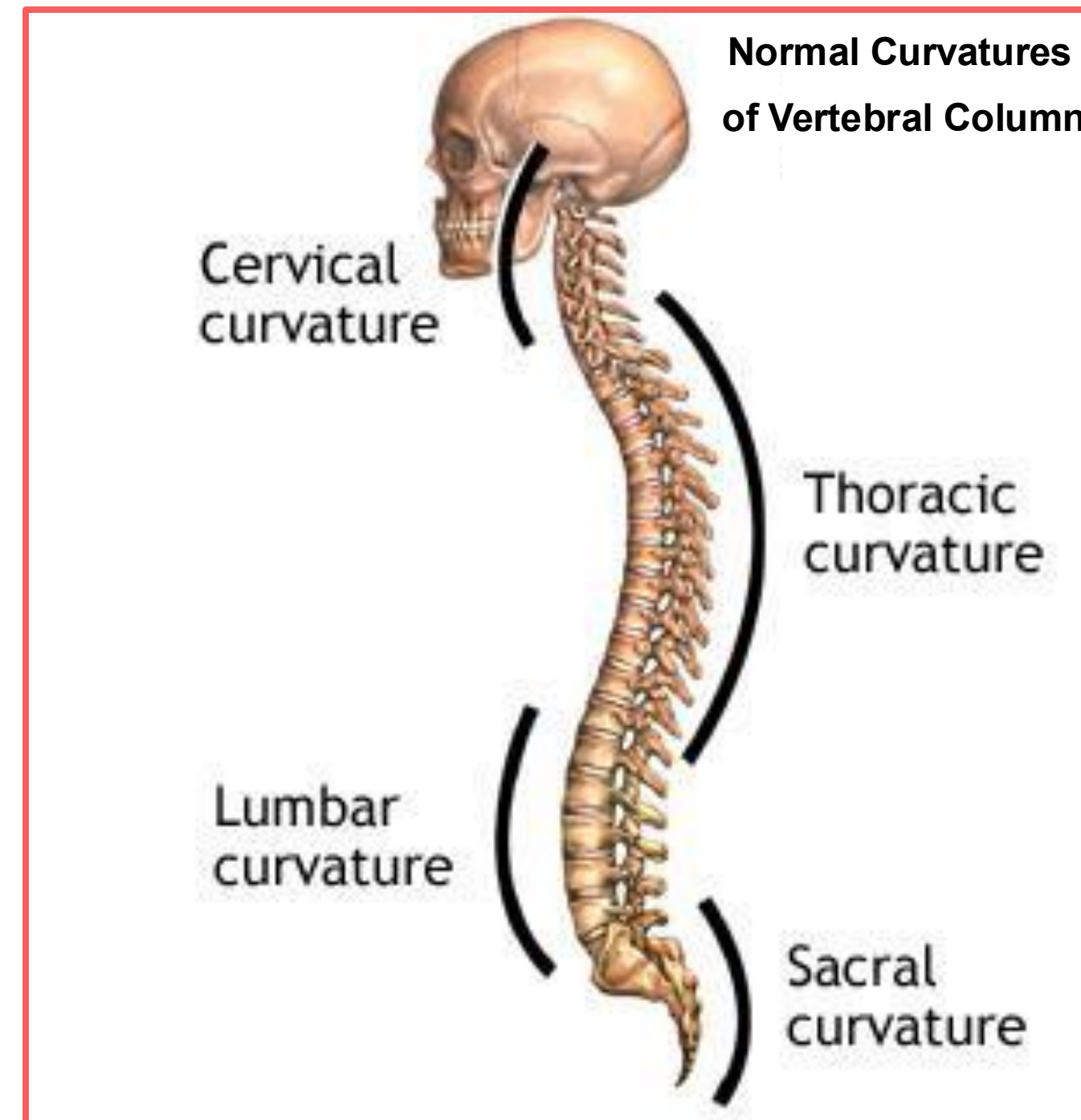
## ➤ Curvatures of Vertebral Column

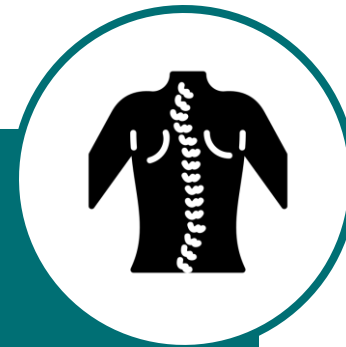- When vertebral column viewed from the anterior or posterior, a normal adult vertebral column appears straight.
- **When vertebral column viewed from the side, the adult vertebral column has four normal curvatures:**

1. **Cervical curvature** -- (convex forward)
2. **Thoracic curvature** - (concave forward)
3. **Lumbar curvature** --- (convex forward)
4. **Sacral curvature** ----- (concave forward)

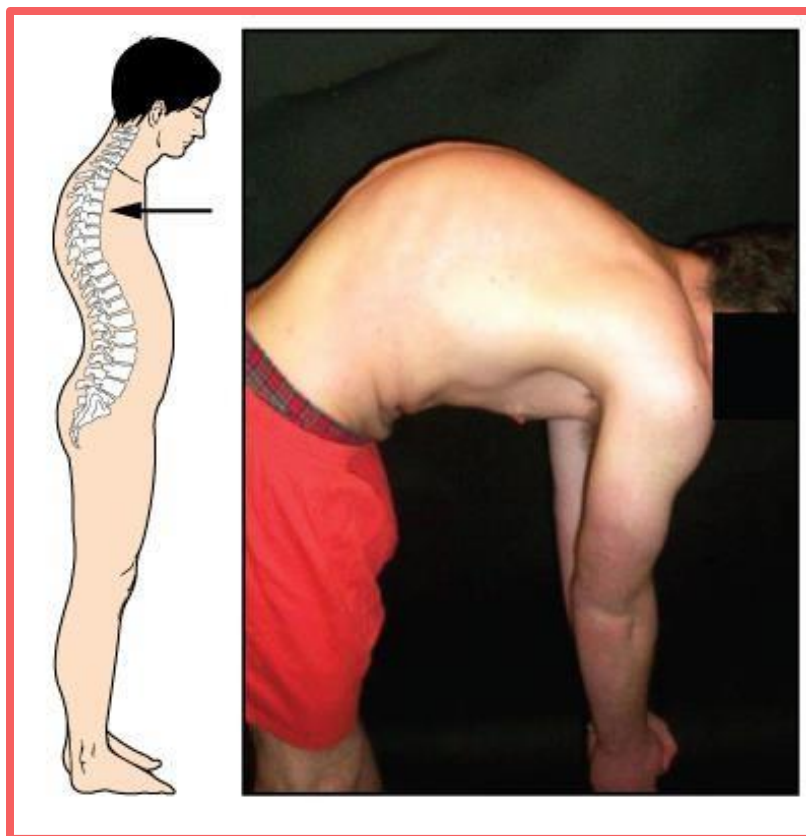
concave forward means convex backward and vice versa

- **The curves of the vertebral column increase its strength, help maintain balance in the upright position, absorb shocks during walking.**

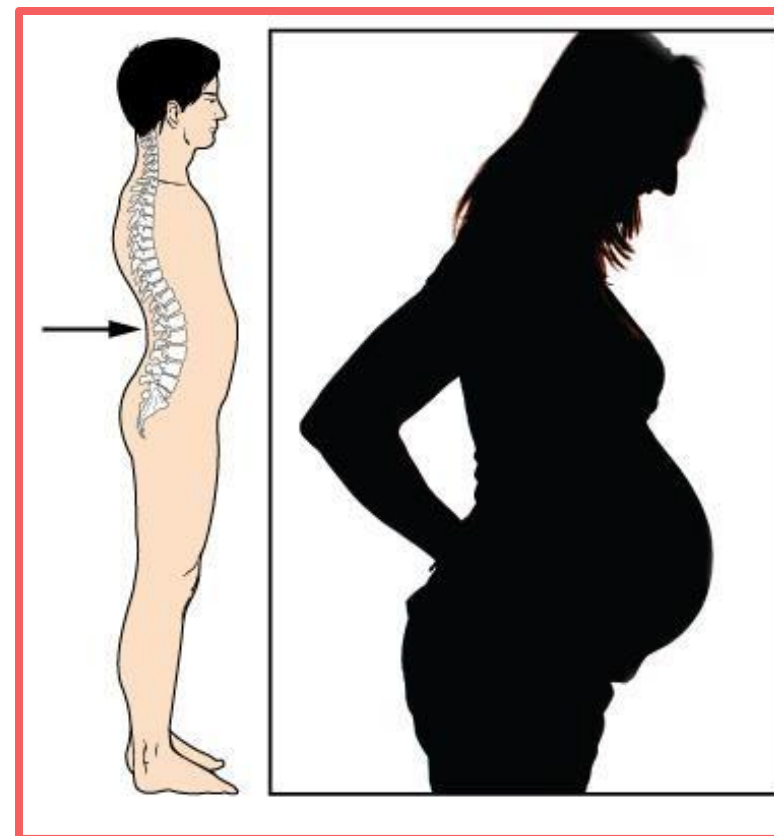


Clinical  
CorrelationAbnormal Curvatures

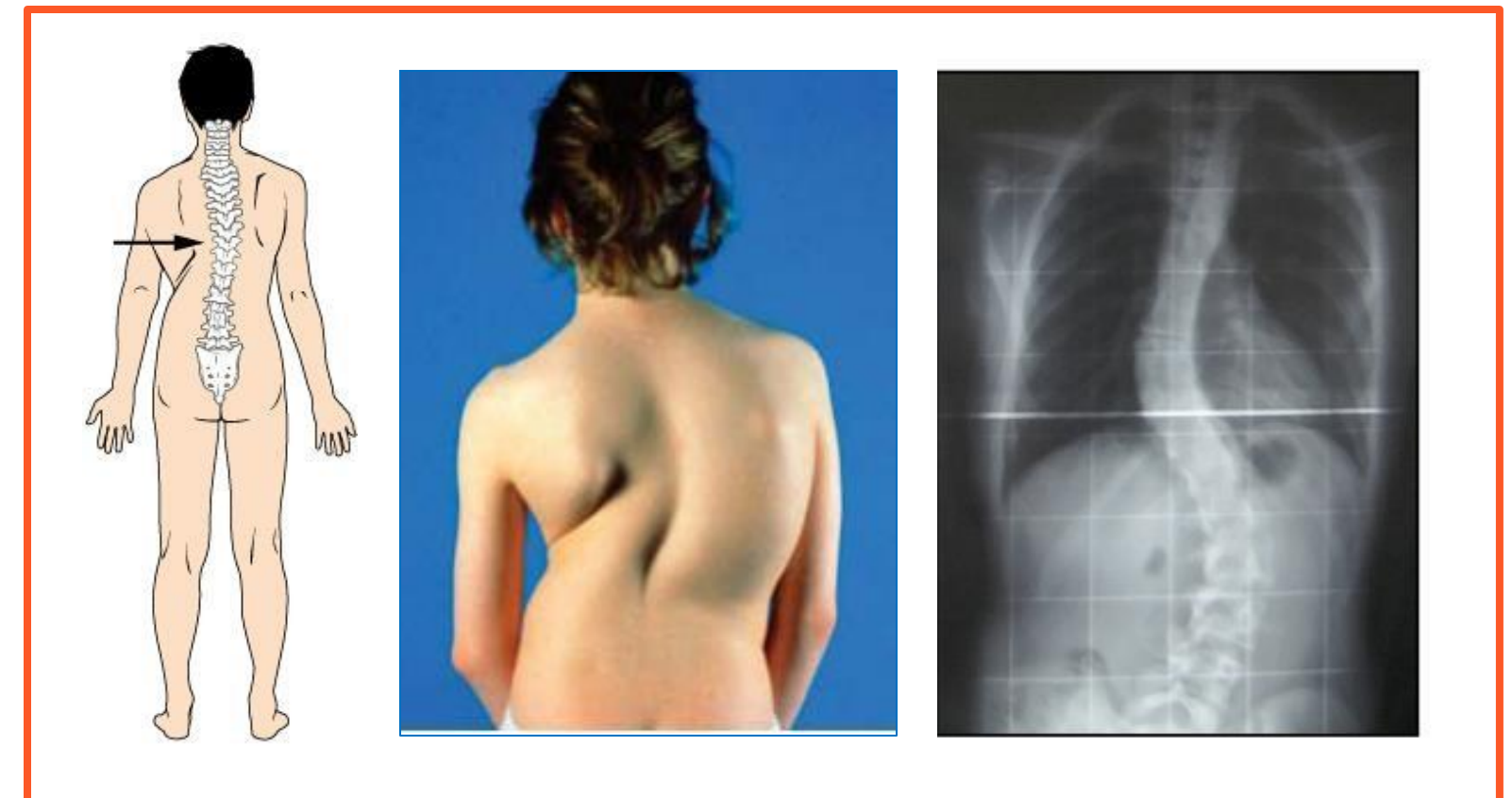
1. **Kyphosis**: Increased thoracic curve; may occur with age due to osteoporosis or disc degeneration.
2. **Lordosis**: Increased lumbar curve; may result from pregnancy or obesity.
3. **Scoliosis**: Abnormal lateral curvature either to the right or to the left, often in the thoracic region; may be caused by poliomyelitis, leg length discrepancy, or hip disease.



Kyphosis




Lordosis



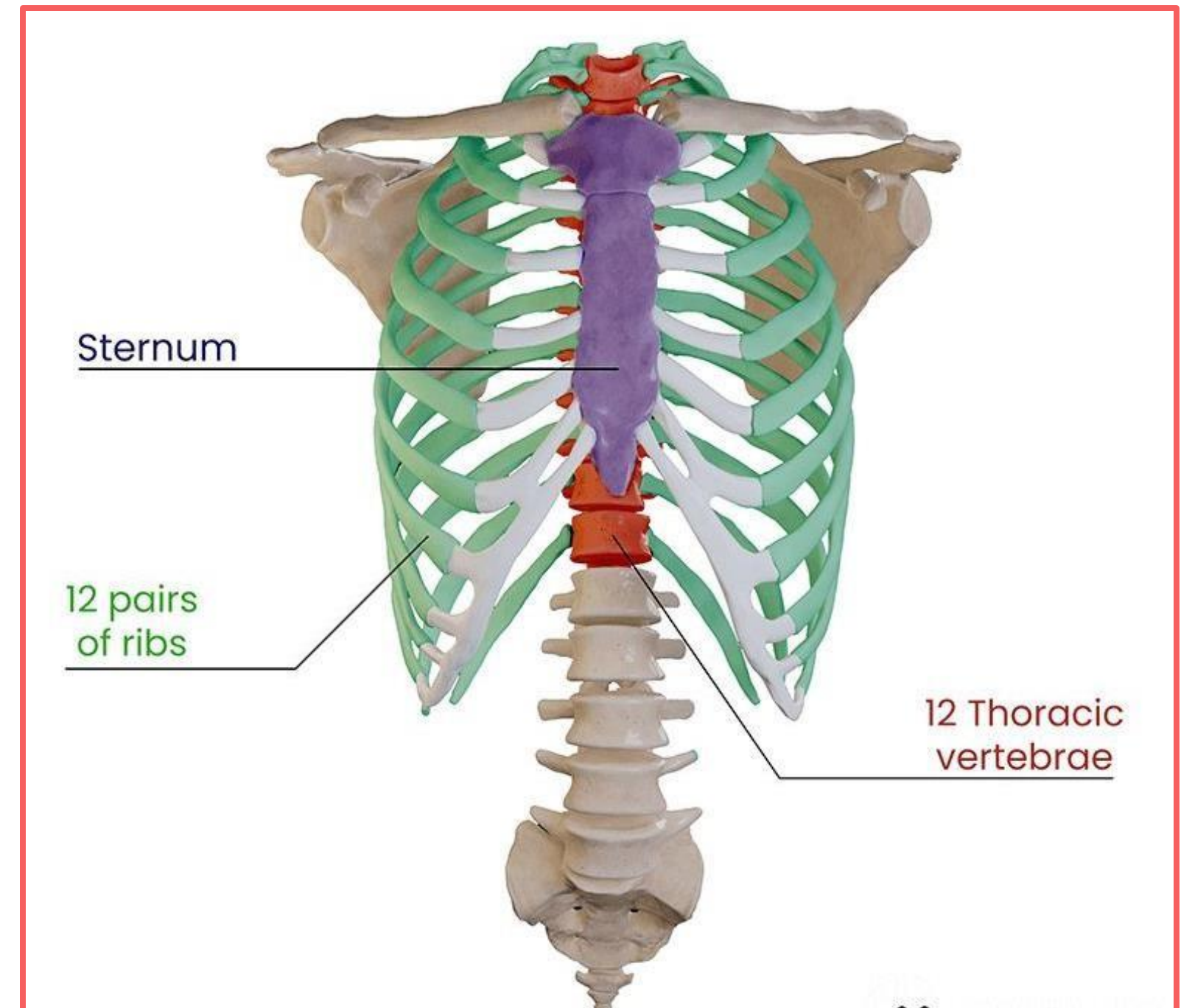
Scoliosis

# Thoracic Cage



➤ The thoracic cage consists of:

1. **Sternum (anteriorly).**
2. **12 pairs of ribs & costal cartilages (Laterally).**
3. **12 thoracic vertebrae (posteriorly).**



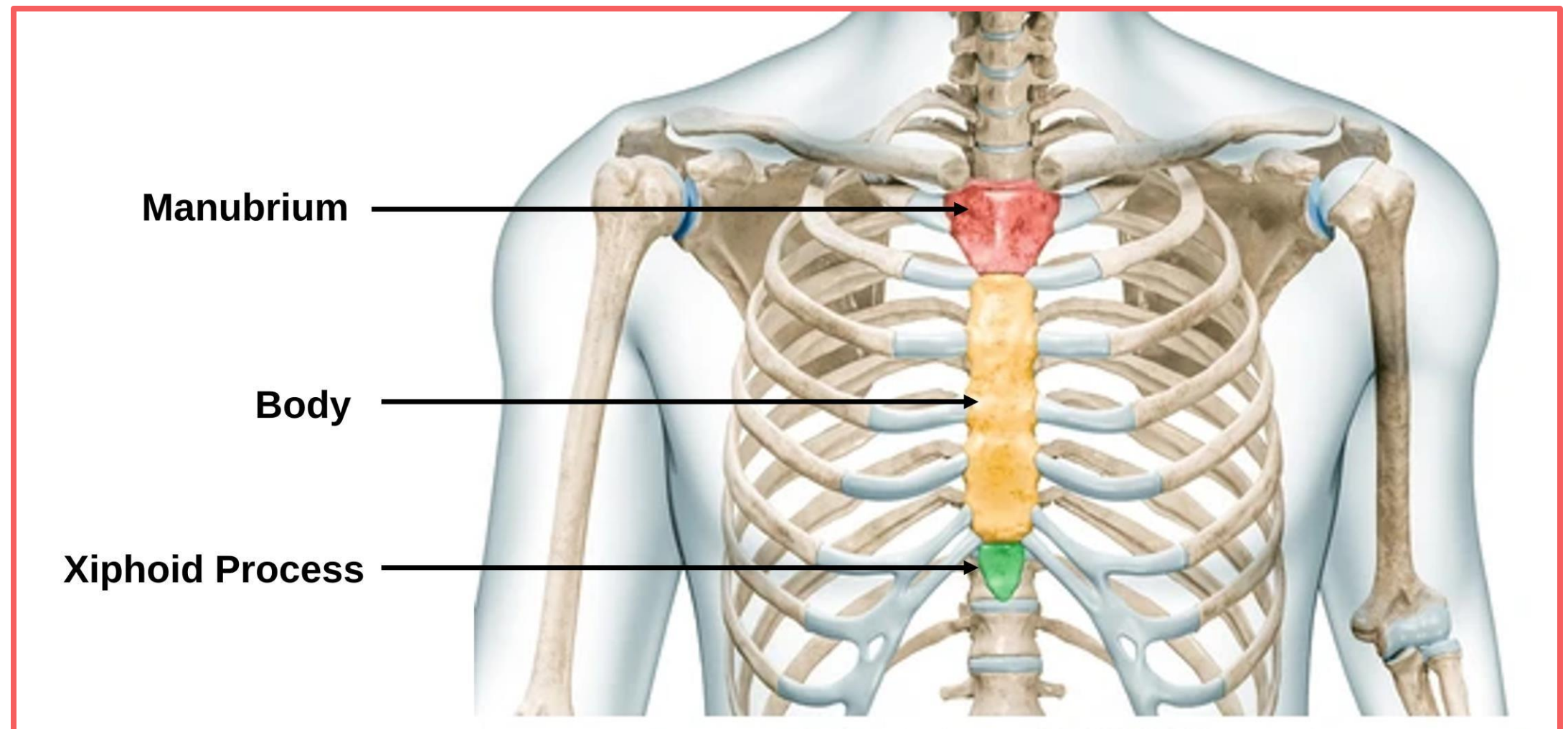
### ➤ Sternum

- It is a flat bone located in the center, consists of the following three parts:

1. Manubrium.

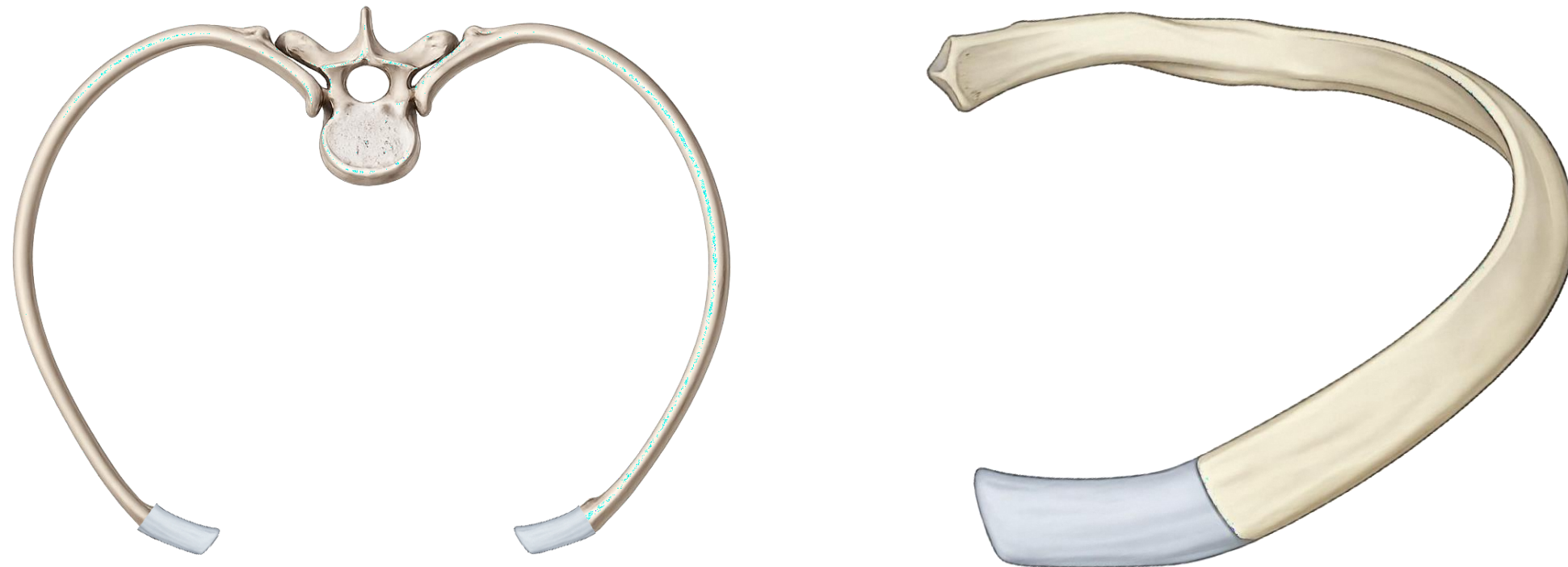2. Body.

3. Xiphoid Process.



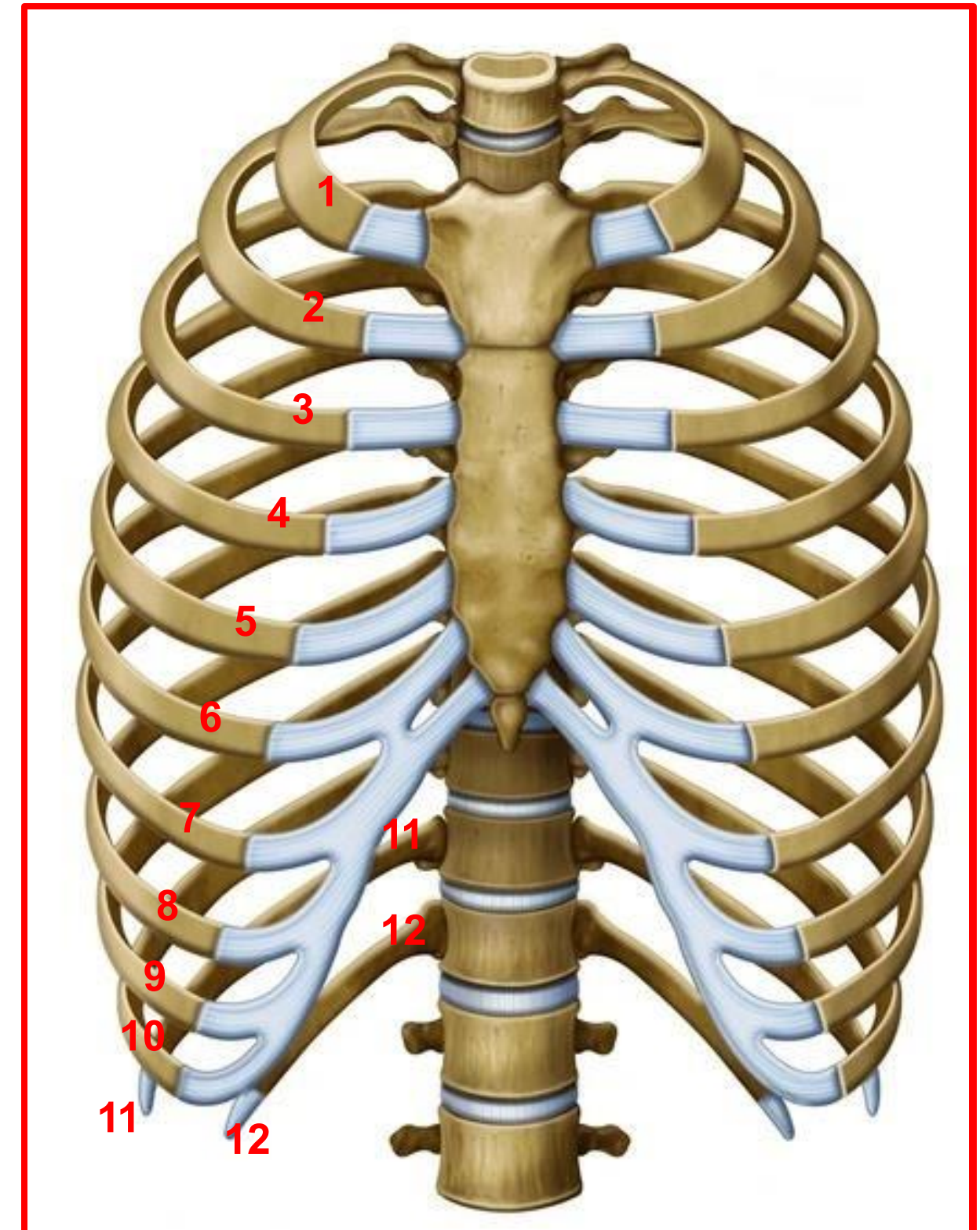
➤ Ribs 

- Elastic bony arches, there are 12 pairs of ribs.
- Extend from thoracic vertebrae posteriorly to the lateral borders of the sternum anteriorly.



➤ Costal Cartilages

- Each rib continues anteriorly as a costal cartilage, which mostly articulates directly or indirectly with the sternum.
- The costal cartilages contribute to the elasticity of the thoracic cage.



To make inhaling and exhaling easier

# Thoracic Cage

## 2. Ribs & Costal Cartilages

➤ There are three types of ribs based on their anterior articulation:

- True Ribs (1st–7th ribs):

They are attached directly to the sternum by their own costal cartilage.

- False Ribs (8<sup>th</sup> -10<sup>th</sup> ribs):

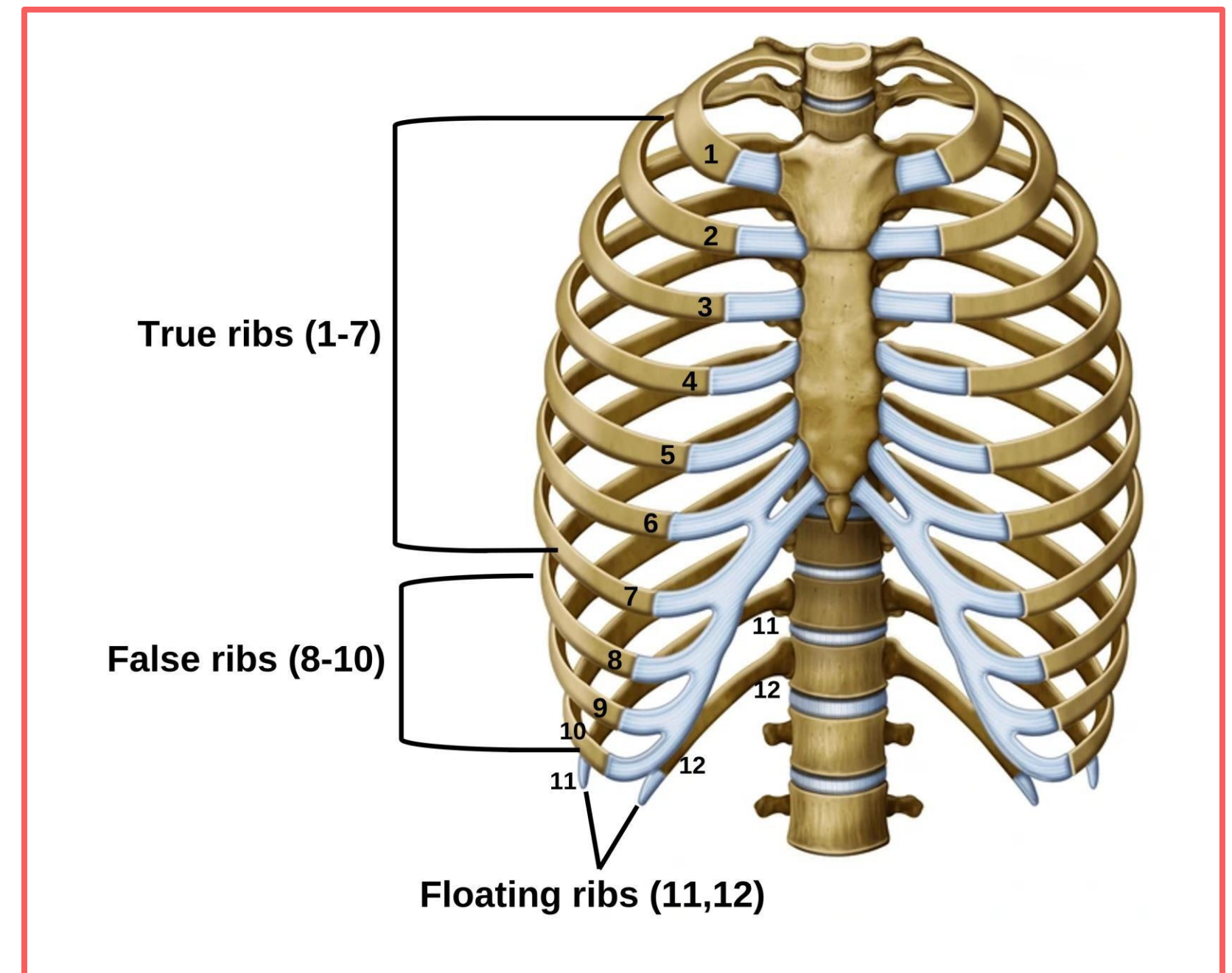
They are attached indirectly to the sternum.

Their costal cartilages join together and then connect to the cartilage of the 7th rib.

- Floating Ribs (11<sup>th</sup> - 12<sup>th</sup> ribs):

They are smaller than the others and do not reach the front of the body.

They do not articulate with the sternum, and the anterior ends of their costal cartilages are free.



➤ The posterior ends of all ribs articulate with the thoracic vertebrae.

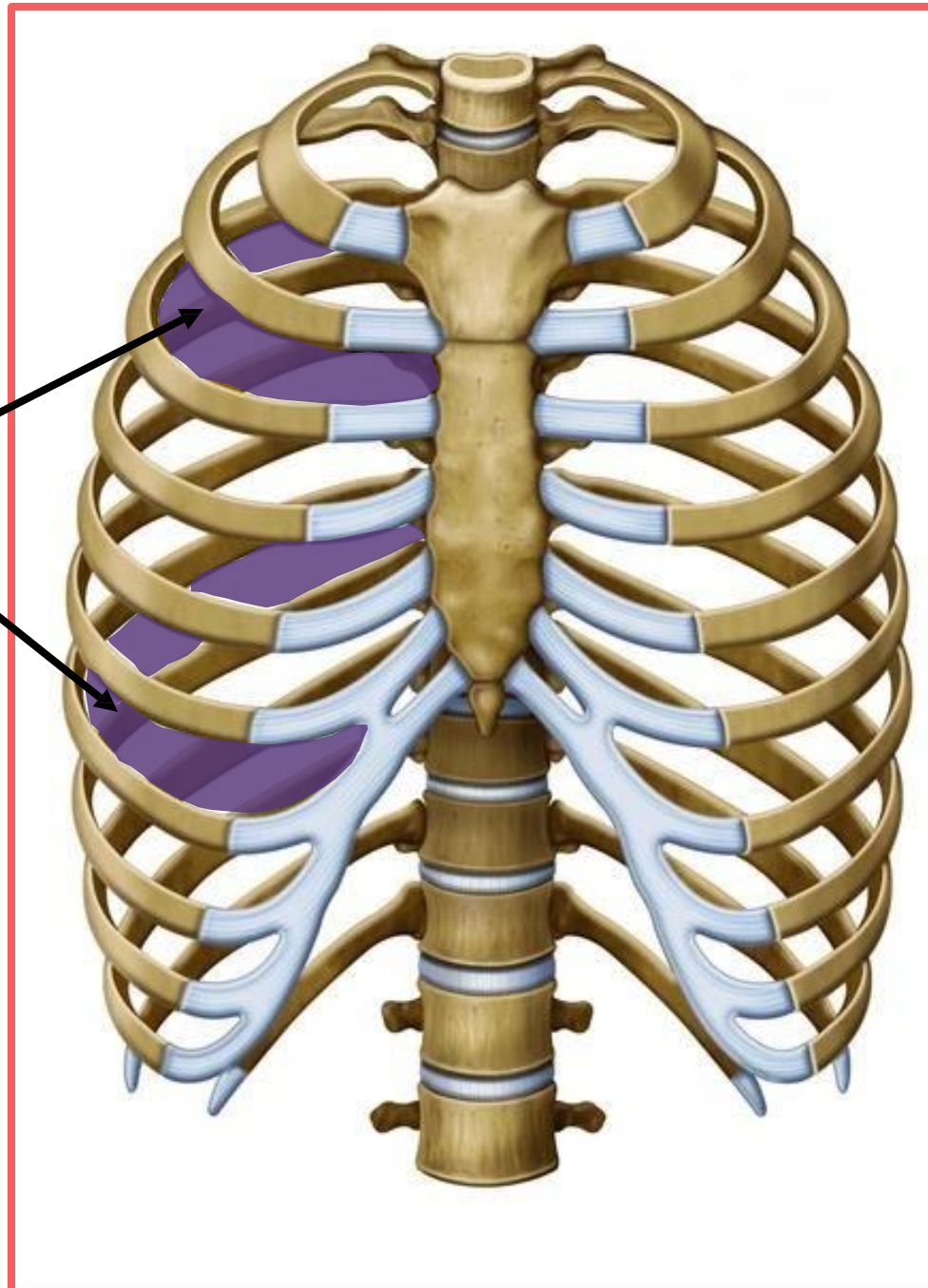
# Thoracic Cage

## 2. Ribs & Costal Cartilages

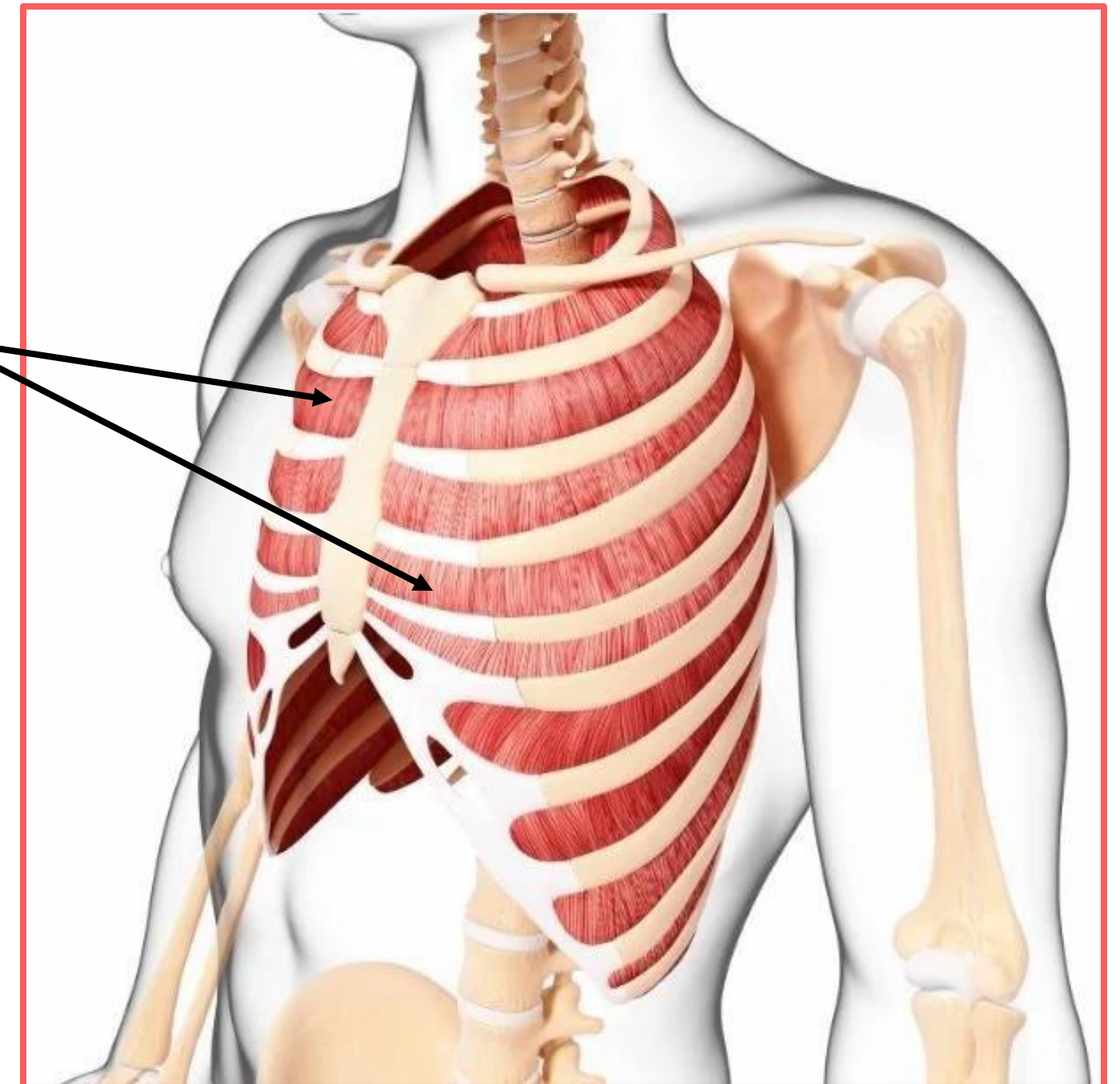
### ➤ Intercostal Spaces:

- The gaps between the adjacent ribs are called Intercostal Spaces.
- Intercostal spaces filled by Intercostal Muscles.

Intercostal Spaces

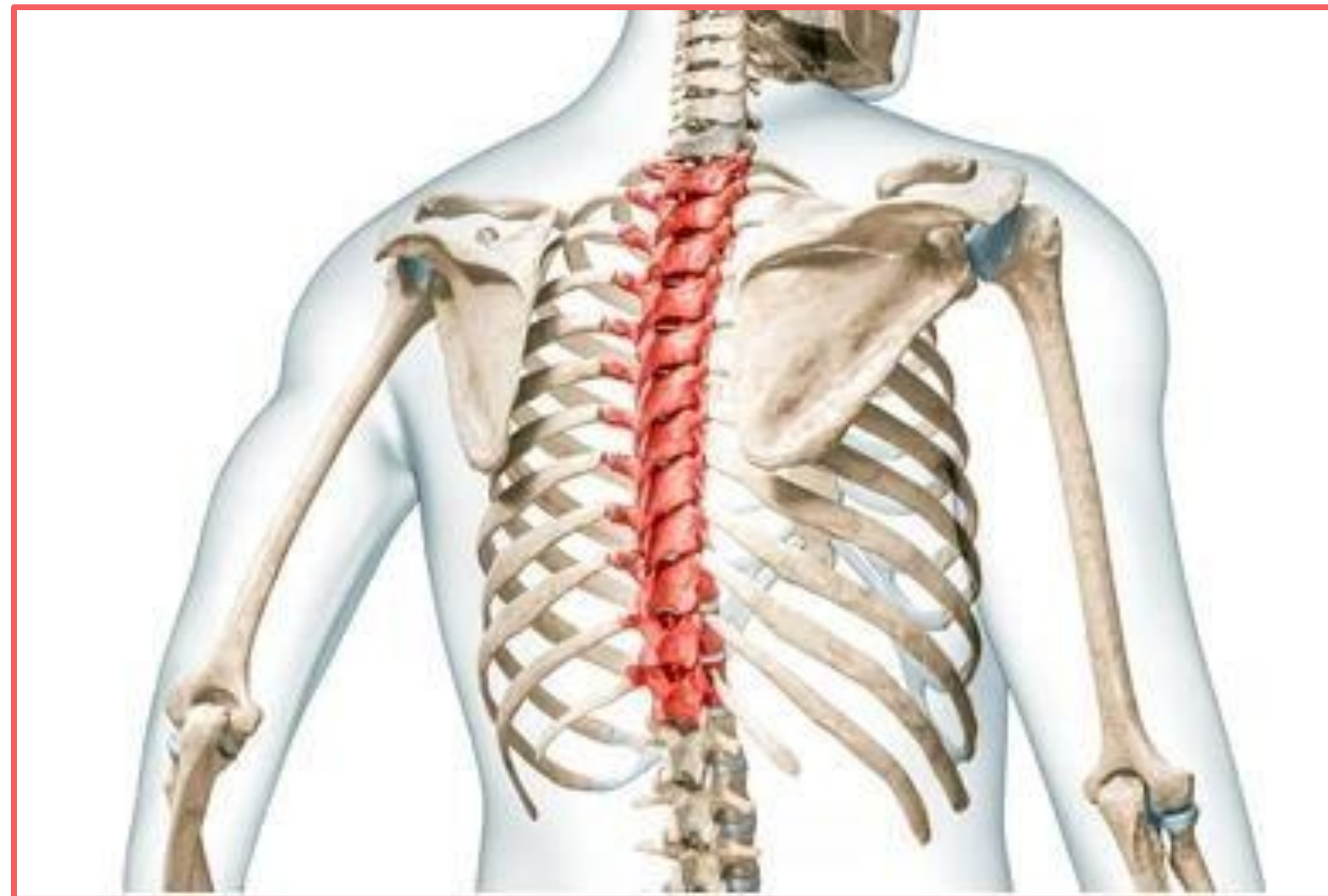

Intercostal Muscles



### ➤ Thoracic vertebrae

- The 12 thoracic vertebrae, along with their intervertebral discs, form the posterior part of the thoracic cage.



# رسالة من الفريق العلمي:

فضلُ العالمِ عليّ { قال -صلى الله عليه وسلم- عن النبي -رضي الله عنه- عن أبي أمامة الباهلي  
إنَّ اللهَ وملائكتهُ وأهلَ :-صلى الله عليه وسلم- العابدِ كفضلي على أدناكم ثمَّ قال رسولُ اللهِ  
السَّمَاوَاتِ وَالْأَرْضِ حَتَّى النَّمْلَةَ فِي جُحْرِهَا، وَحَتَّى الْحَوْتَ لِيَصَلُّونَ عَلَى مُعَلِّمِ النَّاسِ الْخَيْرِ }

# For any feedback, scan the code or click on it.



Corrections from previous versions:

Versions	Slide # and Place of Error	Before Correction	After Correction
V0 → V1	24	The C2 has 7 processes and doesn't have a body	The C2 has 8 processes (with the odontoid process) and has a large body
V1 → V2			